

- Clinical Evaluation (MIRACLE ICD) Trial Investigators. Combined Cardiac resynchronization and implantable cardioverter defibrillation in advanced chronic heart failure: the Miracle ICD trial. *JAMA* 2003;**289**:2685–2694.
25. van Veldhuisen DJ, Maass AH, Priori SG, Stolt P, van Gelder IC, Dickstein K, Swedberg K. Implementation of device therapy (cardiac resynchronization therapy and implantable cardioverter defibrillator) for patients with heart failure in Europe: changes from 2004 to 2008. *Eur J Heart Fail* 2009;**11**: 1143–1151.
26. Bogale N, Priori S, Cleland JG, Brugada J, Linde C, Auricchio A, van Veldhuisen DJ, Limbourg T, Gitt A, Gras D, Stellbrink C, Gasparini M, Metra M, Derumeaux G, Gadler F, Buga L, Dickstein K; Scientific Committee, National Coordinators, and Investigators. The European CRT Survey: 1 year (9–15 months) follow-up results. *Eur J Heart Fail* 2012;**14**:61–73.
27. Singh JP, Klein HU, Huang DT, Reek S, Kuniss M, Quesada A, Barsheshet A, Cannom D, Goldenberg I, McNitt S, Daubert JP, Zareba W, Moss AJ. Left ventricular lead position and clinical outcome in the multicenter automatic defibrillator implantation trial-cardiac resynchronization therapy (MADIT-CRT) trial. *Circulation* 2011; **123**:1159–1166.
28. Thébault C, Donal E, Meunier C, Gervais R, Gerritse B, Gold MR, Abraham WT, Linde C, Daubert JC; REVERSE study group. Sites of left and right ventricular lead implantation and response to cardiac resynchronization therapy observations from the REVERSE trial. *Eur Heart J* 2012;**33**:2662–2671.

CARDIOVASCULAR FLASHLIGHT

doi:10.1093/eurheartj/eh202

Online publish-ahead-of-print 11 June 2013

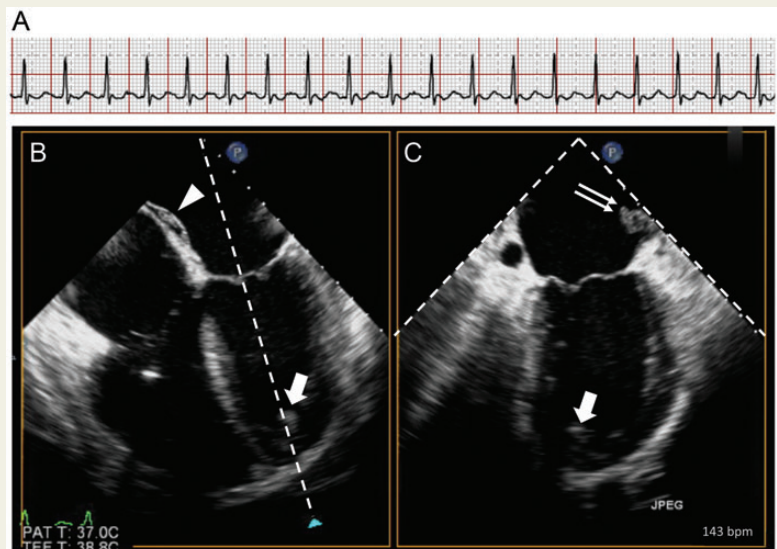
Triple trouble in the heart

Alexander Breitenstein*, Patric Biaggi, and Matthias Greutmann

Division of Cardiology, University Hospital of Zurich, Raemistrasse 100, Zurich 8091, Switzerland

*Corresponding author. Tel: +41 442553979, Fax: +41 442558701, Email: alexander.breitenstein@usz.ch

A 47-year-old man with a history of systemic hypertension and type 2 diabetes mellitus was admitted to our centre in cardiogenic shock. He experienced rapidly progressive shortness of breath for the past 3 weeks. The ECG on admission showed atrial flutter with 2:1 conduction and a ventricular rate of 142 b.p.m. (Panel A). Transoesophageal echocardiography prior to cardioversion (Panels B and C, simultaneous recordings of the left heart in two orthogonal planes) revealed a dilated left ventricle with an ejection fraction of 25%. In addition, large clots were detected in the three most typical locations for clot formation in the left heart: in the left atrial appendage [Panel C (double arrow) and see Supplementary material online, Video S1], in the left ventricular apex [Panels B and C (arrow) and see Supplementary material online, Video S1] and in the tunnel of the foramen ovale [Panel B (arrow head) and see Supplementary material online, Video S2]. Under antithrombotic treatment with heparin the clots were nearly completely resolved within 2 weeks (see Supplementary material online, Video S3). After restoration of sinus rhythm the left ventricular ejection fraction improved to 40% (see Supplementary material online, Video S3). The patient recovered without clinical or radiological evidence of systemic embolization. He will be kept on long-term anticoagulant therapy and was instructed to seek immediate medical attention in case of recurrence of palpitations or worsening exercise tolerance. Given the need for life-long anticoagulation, no thrombophilia screening was performed. Amiodarone was initiated as antiarrhythmic therapy.



(Panel A) ECG on admission demonstrating atrial flutter with 2:1 conduction and a ventricular rate of 142 b.p.m. (Panels B and C) Transoesophageal echocardiography showing the presence of clots in the tunnel of the foramen ovale (arrow head), the left ventricular apex (arrow), and the left atrial appendage (double arrow).

Supplementary material is available at *European Heart Journal* online.