

Treatment challenges associated with bone echinococcosis

Sylvain Steinmetz¹, Guillaume Racloz¹, Richard Stern¹, Dennis Dominguez¹, Mohamed Al-Mayahi¹, Manuel Schibler², Daniel Lew², Pierre Hoffmeyer¹ and Ilker Uçkay^{1,2*}

¹Orthopaedic Surgery Service, Geneva University Hospitals and Faculty of Medicine, University of Geneva, Geneva, Switzerland; ²Service of Infectious Diseases, Geneva University Hospitals and Faculty of Medicine, University of Geneva, Geneva, Switzerland

*Corresponding author. Service of Infectious Diseases, Geneva University Hospitals, 4 Rue Gabrielle Perret-Gentil, 1211 Geneva 14, Switzerland. Tel: +41-22-372-2901; Fax: +41-22-372-9830; E-mail: ilker.uckay@hcuge.ch

Received 3 February 2013; returned 19 August 2013; revised 1 October 2013; accepted 6 October 2013

Objectives: In this literature review, we concentrate on epidemiology and therapy of osseous echinococcosis, with an emphasis on the recurrence risk.

Methods: Literature review 1930–2012.

Results: We retrieved 200 publications based upon single case reports or case series, mostly from resource-poor settings. Among the 721 rural patients (22% females; median age 37 years), 60% of all reported cases were from the Mediterranean region and almost all patients were immune competent. *Echinococcus granulosus* was identified as the most frequent species. Most infections involved a single bone (602/721; 83%) and often the spine (321 cases; 45%). In eight cases (8/702; 1%), a secondary bacterial surgical site infection was reported. Surgical intervention was performed in 702 cases (97%), with single intervention in 687 episodes (95%). Complete excision of the lesion was possible in only 117 episodes (16%). Albendazole was by far the most frequently used agent in monotherapy with various dosages, while mebendazole in monotherapy was less frequent (32 cases). The median duration of antihelminthic therapy was 6 months (range 0.7–144 months). There were 124 recurrences (17%) after a median delay of 2 years (range 0.4–17 years). In multivariate analysis, the presence of visceral organ involvement increased the odds of recurrence by 5.4 (95% CI 3.1–9.4), whereas the number of surgical interventions, the duration of antihelminthic therapy or the use of hypertonic saline did not influence recurrence.

Conclusions: Bone echinococcosis is a rare parasitic disease. While treatment modalities vary considerably, combined surgical and medical approaches are the standard of care with a 17% risk of recurrence.

Keywords: epidemiology, recurrence, orthopaedic surgery, benzimidazoles

Introduction

Echinococcosis is a worldwide zoonosis infecting a large number of animals and humans.^{1–3} Human bone involvement is often asymptomatic^{2,3} and estimated to occur at a frequency of 0.5%⁴ to 4%² of all cases of echinococcosis,^{5,6} most likely by haematogenous spread^{5,6} from the liver or a secondary soft organ infected from the liver. Endemic regions include rural areas (sheep farming^{1,7}) of Mediterranean countries, Asia, Africa and Latin America,⁸ due to a variety of reasons such as migration, chronicity of the disease and absence of spontaneous healing. Nevertheless, a substantial number of physicians and surgeons in less-endemic rich countries may equally witness bone disease once in a lifetime.

Other than the consensus for combined aggressive surgical and medical therapy,^{9,10} there are no additional detailed

recommendations when confronted with bone hydatid disease. To the best of our knowledge, there are no systematic reviews available. Antihelminthic benzimidazole therapy for many years is frequent.^{2,10} Some surgeons use bone grafts to fill bone cavities, while others insert polymethylacrylate.¹¹ Some physicians administer antimicrobial agents for only 3 months,^{9,12} while others prefer 10 years.⁵ Overall, recurrences despite several surgical interventions are common.¹¹ In this systematic literature review, we concentrate on the epidemiology and treatment modalities of osseous echinococcosis, with an emphasis on the risk of recurrence.

Methods

We performed a review of the literature from 1930–2012 in the Internet and PubMed database, using the MeSH terms 'echinococcus' or 'hydatid'

combined with either 'bone', 'os', 'Knochen*' or 'kemik'. Published original scientific articles in English, French, German, Italian, Spanish, German or Turkish for human infections were included in an Excel™ database. References of retrieved articles were further hand-searched for additional papers, while English language abstracts of articles in other languages were excluded. In order to avoid doubling of patients, we included only the last publication from the same author group. Recurrence was defined as progression of the cyst diameter despite therapy and/or the appearance of new bone lesions.

Statistical analyses

The majority of articles were case reports or case series. No prospective cohort studies or randomized trials were found; therefore, a formal meta-analysis regarding outcomes and treatment modalities was not possible. Nevertheless, we attempted to evaluate recurrence risks, even if this approach only considered a collection of retrospective case series. Group comparisons of categorical variables were performed using the Pearson χ^2 or Wilcoxon rank-sum test. A logistic regression analysis determined association with the outcome 'recurrence of bone echinococcosis'. Independent variables with a P value ≤ 0.2 in univariate analysis were introduced stepwise in the multivariate analysis. We included 5–10 outcome events per predictor variable.¹³ All variables were checked for confounding and interaction. P values ≤ 0.05 (two-tailed) were significant. STATA software (9.0, STATA™, USA) was used.

Results

Our representative case report

An elderly male Spanish immigrant presented at Geneva University Hospitals with a chronic intermittent discharge from the right hip. Twenty-six years previously in rural Spain he was diagnosed with bone echinococcosis (*Echinococcus granulosus*) of the femur and pelvis without visceral involvement. He was treated without surgery and received albendazole for 2 years. In Switzerland,

after a quiescence of 20 years, he developed chronic bacterial osteomyelitis of the femur and pelvis due to *Staphylococcus epidermidis*, with a productive sinus tract to the skin and an internal fistula into the abdomen. This bacterial superinfection was new, whereas the size and number of the cysts did not change over >20 years. There were no other signs of active echinococcal disease. Because of the extension of the lesions to weight-bearing bones, surgical resection was not possible. Suppressive therapy with oral ciprofloxacin/rifampicin (600 mg three times a day) stopped the sinus discharge for 2 years, at which time a new internal fistula into the abdomen developed. At present, the patient receives occasional suppressive antibiotic therapy in cases of fistula drainage.

Literature review and patients

According to our search criteria, we retrieved 200 publications with 721 different episodes (Table 1). Turkey ranked highest with 158 different reported cases (22%), followed by Spain with 78 cases (9%) and Germany with 67 reported cases (11%). WHO region 4 (Europe, Turkey and the former Soviet Union) accounted for almost 60% of all reported cases. Most publications concerned one single case (136/200; 68%) and 40 publications between two and nine cases. Only 24 papers (12%) had a substantial experience with ≥ 10 episodes. Within the publication window from 1930 to 2012, half of the manuscripts were published in the last 16 years (since 1996). The median age of the 721 different patients was 37 years (IQR 29–45 years). Potential immune suppression was often not addressed, thus the presumption that almost all patients were immune-competent. In the majority of cases, the provenance of infection could not be established, besides the fact that the patients lived in rural areas. There were 73 farmers and 6 shepherds in the reported cases.

Table 1. Osseous echinococcosis (literature review 1930–2012; 721 episodes)

	Number (%)	Remarks
Clinical features		
male patients	559 (78)	rural activities
single bone involvement	602 (83)	various sites
spine	321 (45)	most dangerous site (paraplegia)
paraplegia	40 (6)	
claudication	66 (9)	claudication mostly spinal
fractures	48 (7)	
substantial pain	292 (40)	most patients have pain of varying intensity
soft tissue tumefaction	33 (5)	
adjacent soft tissue involvement	114 (16)	in vicinity of the bone lesion
concomitant organ involvement	74 (10)	also occurring in distant organs
liver	45 (6)	most frequently involved organ in general
lung	29 (4)	
Treatment		
surgery performed	702 (97)	no surgery only in inoperable cases
complete excision possible	117 (16)	
osteosynthesis and/or grafting	70 (10)	
absence of antihelminthic therapy	10 (1)	median duration of administration 6 months
Recurrence	124 (17)	after a median of 2 years

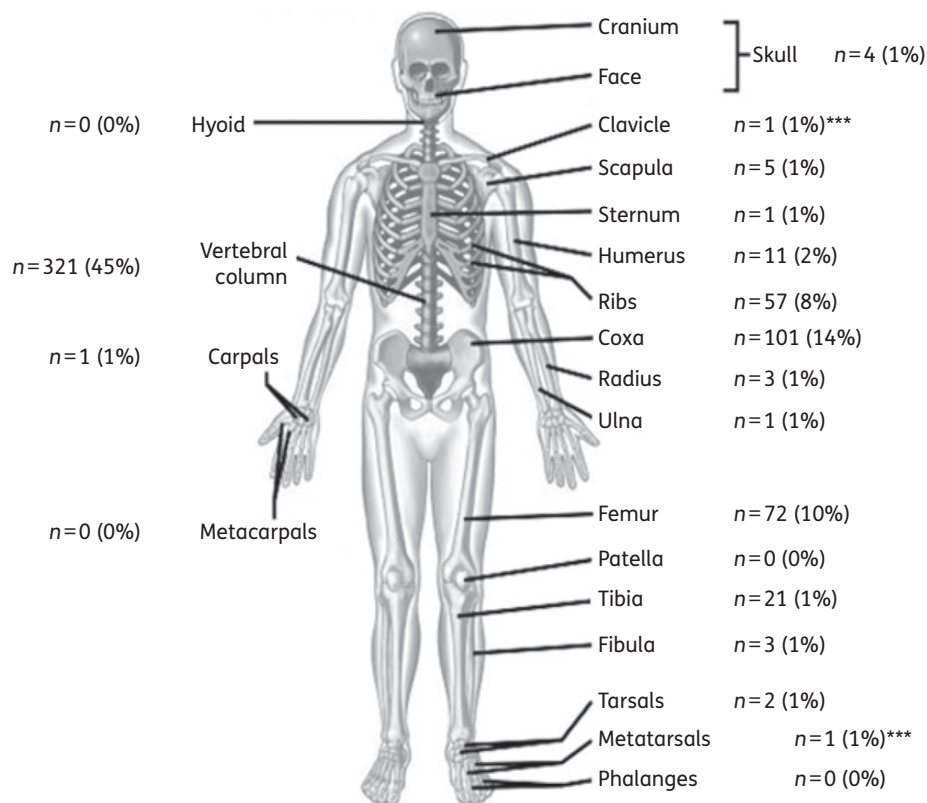


Figure 1. Localizations of bone echinococcosis in our literature review 1930–2012. ***One case each of metatarsal and clavicular involvement mentioned in the literature are not included in our review due to lack of sufficient information.

Infections, bones and species

Many older publications did not identify the echinococcosis species. In more recent publications, *E. granulosus* was identified as the most frequent species with only 11 exceptions: 9 mono-infections due to *Echinococcus multilocularis*; 1 mixed episode of *E. granulosus* and *E. multilocularis*; and 1 mixture of *Echinococcus vogeli* and *E. granulosus*. Most infections involved a single bone (602/721; 83%). In 107 episodes, two bones were involved; in 8 episodes, three bones were involved; and in 4 episodes, four different bones were involved (Figure 1). In two episodes, echinococcosis was in contact with arthroplasty material. The median largest diameter of the bone lesions was 5.5 cm (range 1–20 cm). Overall, 80% of all cysts were <10 cm in diameter. In 114 episodes, the parasitic infection involved adjacent soft tissues, together with distant organs in 74 episodes, including: liver ($n=45$), lung ($n=29$), spleen ($n=2$), pancreas ($n=2$), brain ($n=1$), kidney ($n=1$), ovaries ($n=1$) and bladder ($n=1$).

Surgical treatment

Surgical intervention was performed in almost all cases (702/721; 97%), with the exception of 19 episodes where a surgical approach was deemed not possible due to potential substantial harm to the patient. In 687 episodes (95%), there was only one surgical intervention; in seven cases, there were three interventions; in five cases, there were two interventions; and in three cases, there were four interventions. Complete excision of the lesion, as best

as could be reported, was possible only in 117 cases (16%), of which 5 were amputations. The remainder included incomplete debridement, drainage, laminectomy, arthrodesis and hemipelvectomy.¹⁴ In 12 operations, the surgeon injected hypertonic saline at concentrations varying between 3%¹² and 40%¹⁵ or ethyl alcohol¹⁵ (70%) into the cavity. Very rarely, an anaphylactic reaction was reported after cavity opening.¹⁶ Despite the large diameters of the different lesions and multiple surgical interventions, a secondary bacterial surgical site infection occurred in only eight cases (8/702; 1%). The bone cavities became infected with bacterial pathogens in 36 cases (5%), of which 8 were classified as post-interventional surgical site infections and 28 as spontaneous superinfections due to various bacteria (staphylococci, *Escherichia coli*, *Enterobacter* spp., *Pseudomonas aeruginosa*, enterococci and streptococci).¹⁷ The excised cavities were stabilized by osteosynthesis in 661 episodes (92%), while fractures occurred in 48 cases. The time of fracture occurrence was, however, not noted. Hence, we ignore whether they occurred early or late in the infection process. In most cases, osteosynthesis was performed with the use of plates or by spondylodesis; in five cases of femoral infection, the surgeons performed a total joint arthroplasty.¹⁸ Bone grafting was performed in 30 episodes.

Antimicrobial treatment

Since most publications were found in surgical journals, the main focus was the surgical approach. Thus, we often lack detailed

Table 2. Clinical variables associated with recurrence of bone echinococcosis

	Recurrence, n=124	P ^a	No recurrence, n=597
Female gender	39	NS	123
Pelvic involvement	13	NS	75
Spine involvement	75	0.019	246
Involvement of >2 bones	9	NS	23
Middle East region	42	0.001	101
Soft tissue involvement	20	NS	94
Organ ^b involvement	35	0.001	39
'Complete' surgical excision	18	NS	99

NS, not significant.

^aPearson χ^2 test. Only significant values ($P < 0.05$) are displayed.

^bLiver, lung, kidney or pancreas involvement concomitant with bone infection.

information about the modalities of antihelminthic therapy for 427 episodes (59%), especially regarding variations of daily doses throughout the therapy course. Albendazole (15 mg/kg/day) in monotherapy was the most frequently used regimen (in a minimum of 235 episodes).¹⁵ Nine cases used albendazole in reduced doses (10 mg/kg/day) from the start and in 11 cases, albendazole (15 mg/kg/day) was combined with praziquantel (40 mg/kg/day). Mebendazole was usually combined with albendazole⁵ and praziquantel,⁹ with mebendazole in monotherapy (10 mg/kg/day) used less frequently (32 cases).⁵ The remaining publications indicated 'benzimidazole therapy' or 'albendazole' without mentioning the dose. In contrast, the duration of antihelminthic therapy was almost always noted, with a median duration of therapy of 6 months (range 0.7–144 months; IQR 3–8 months). In some cases, the antihelminthic drugs were started 4 weeks prior to surgery.¹⁵ The benzimidazoles were generally well tolerated, even over a course of 10 years of administration.⁵

Variables associated with recurrence

Patients were followed for a median of 5.5 years after their last surgical intervention (range 0.1–24 years). Among the 721 episodes, 124 (17%) were reported as recurrent (or progressive infection) after a median delay of 2 years after treatment for the first episode (range 0.4–17 years). All recurrences occurred at the same bone site and there were no new bone lesions at another location. Besides clearly evident recurrences (or persistence of infection), patients with bone echinococcosis reported other sequelae: persistent pain was very frequent, followed by fractures in 48 episodes, persistent paraplegia in 14 episodes, handicap in 10 cases, death due to progressive disease in 5 cases and pseudarthrosis in 1 case. When adjusting for case mix in multivariate analysis, no single demographic variable was associated with recurrence risk (Tables 2 and 3), with one exception. The presence of a (visceral) organ involvement increased the OR for recurrence of bone infection by 5.4 (95% CI 3.1–9.4), whereas spine involvement was significantly associated only in the univariate analysis, but not in the multivariate analysis. In contrast, among therapeutic aspects, no

variable influenced recurrence risk more than another. The number of surgical interventions, the duration of concomitant antihelminthic therapy or the injection of hypertonic saline failed to reveal superiority compared with other regimens (Table 3).

Discussion

Bone echinococcosis is a rare parasitic infection and is difficult to treat. It is probably associated with very high costs, which is evident when we extrapolate the massive investment according to the 200 publications reviewed. It can involve any bone,¹² but has a predilection for the spine, femur and pelvis. Multiosseous infestation and concomitant soft tissue or organ involvement are frequent, particularly the combination of proximal femur involvement with the pelvic girdle.²

Geographically, the disease is endemic almost worldwide in rural areas, especially in sheep farming regions and/or where there is endemicity of stray dogs.^{8,18,19} However, there are hot spots. The Mediterranean region,^{7,20–22} especially Northern Africa^{3,7} or Turkey^{10,11,19,23–25} together with a few Asian countries¹² (especially Iran^{2,26} and India^{14,18}), yielded the most publications, although the disease was also reported in more resource-rich areas.²⁷ The geographical distribution has probably not changed since 1930, with many authors finding similar distribution patterns although with fewer reported cases than in our present review.²

A combined surgical and medical approach seems to be the basic consensus,⁹ but there are many flaws when it comes to the details. Different authors reveal various therapeutic approaches, especially concerning the duration of antihelminthic therapy combined with surgical excision. The majority of authors performed at least one surgical intervention together with 6 months of albendazole treatment at oral doses of 15 mg/kg/day.²⁸ A minority preferred a 'second surgical look'.⁶ Similar to surgery for chronic bacterial osteomyelitis,^{29,30} the number and type of interventions did not influence the recurrence risk, even if the approach was similar to oncologic surgery with margins excised as wide as possible.³ Filling excised bony defects with polymethylacrylate beads did not prevent recurrence¹¹ and not even a presumed 'total excision' protected from later recurrence. The proportion of surgical excision, which was interpreted as 'total' during the first surgery, was only 117/721 episodes (16%), of which 18/117 (15%) recurred. Total excision of echinococcal cysts is difficult, since many may have daughter cysts. In addition, the cysts can be substantial in size or complicated in shape, or even might infest several weight-bearing bones, as was demonstrated in our own case. Radical excision in the spine is difficult because of the absence of distinct anatomic planes and the existence of neural structures.¹⁰ The parasite grows in the direction of least resistance, infiltrating and damaging the bone like a tumour, with a risk of fracture.⁷ The rigid structure of the bone does not allow formation of adventitia.⁵

Our evaluation suggests that the duration of concomitant antihelminthic therapy does not play a role. A duration of <3 months yielded similar outcomes as compared with administration for >6 months. Likewise, starting a neoadjuvant regimen with albendazole¹⁵ pre-operatively did not show a benefit in terms of recurrence. The literature is sparse when it comes to recommendations for the choice or duration of antimicrobial chemotherapy for bone echinococcosis. International guidelines exist for visceral organs such as the liver,³¹ but not for bone. Albendazole and

Table 3. Logistic regression analysis with outcome 'recurrence of bone echinococcosis'

Variable	Univariate analysis OR, 95% CI	Multivariate analysis OR, 95% CI
female gender	1.4, 0.9–2.2	2.3, 0.7–7.3
age (continuous variable)	1.0, 0.9–1.1	NA
age 35–50 years compared with <35 years	1.0, 0.6–1.8	0.8, 0.3–2.3
age >50 years compared with <35 years	0.7, 0.4–1.1	0.8, 0.3–1.9
pelvic involvement	0.6, 0.3–1.1	0.7, 0.3–1.4
spine involvement	1.7, 1.1–2.6	1.3, 0.8–2.3
cyst diameter (continuous variable)	1.0, 0.8–1.2	NA
more than one bone involved	1.6, 0.7–3.6	NA
soft tissue involvement	1.0, 0.6–1.7	1.1, 0.5–2.8
visceral organ involvement	5.6, 3.1–9.4	5.4, 3.1–9.4
species <i>E. granulosus</i>	1.1, 0.2–5.5	NA
serum CRP value (continuous variable)	0.9, 0.7–1.2	NA
serum eosinophilia >1 G/L	1.1, 0.9–1.3	NA
Treatment modalities		
number of surgical interventions	1.0, 0.6–1.8	0.8, 0.3–1.9
presumed total excision	0.9, 0.5–1.5	1.1, 0.6–2.2
bone grafting	0.3, 0.1–1.4	0.4, 0.1–1.7
injection of hypertonic saline	1.4, 0.6–3.0	1.8, 0.2–13.2
duration of antihelminthic therapy	1.0, 0.98–1.01	NA
3–6 months compared with <3 months	0.4, 0.1–1.3	0.3, 0.1–1.1
>6 months compared with <3 months	0.6, 0.3–1.1	0.5, 0.2–1.3

NA, not applicable; CRP, C-reactive protein.

Statistically significant results are shown in bold.

mebendazole might have the same clinical activity for bone, as suggested by comparative studies between these two agents in alveolar echinococcosis.³² However, because of its higher level in blood plasma, albendazole is regarded by many specialists as the first choice for bone treatment.⁸ For visceral organs, a cyclic treatment of benzimidazoles in several 1 month courses separated by 14 day intervals is usual,³¹ but its efficacy is unknown for bone infections. To overcome these uncertainties, some authors suggest depending upon the clinical and serological evolution as a guide to the duration of antihelminthic therapy,²⁸ although the dormant state of the remission phase can persist for a long time and echinococcal serology can remain falsely elevated²⁷ after treatment.

Despite massive investments of time, resources and surgical interventions, the long-term local recurrence risk of bone echinococcosis was 17%.^{2,10,12,14,20,26} Local symptomatic recurrences after 10 years have been reported²⁶ and we often are not concerned whether patients without clinical recurrence are parasitologically cured or are in remission with a long-lasting control of their infection.²⁰ Interestingly, the remission rate and its duration are similar to the recurrence rate for classic bacterial osteomyelitis.^{29,30} This finding is surprising since echinococci, compared with microscopic bacteria with high reproduction rates, are multicellular parasites that should be removed when performing surgery. In our formal evaluation, the only variable associated with local recurrence was distant organ involvement. In the presence of concomitant bone and visceral organ infestation, the

incidence was five times greater for local bone recurrence or progression of disease in bone. We were unable to detect any difference among the visceral organs and could not elucidate if recurrences were truly local or reinfections from these organs. Finally, unlike chronic bacterial osteomyelitis in young adults, echinococcal infections appear to be more frequently associated with fractures or with the need for osteosynthesis after excision. In our review, 36 of 48 fractures were treated by osteosynthesis and in 30 cases received bone grafts. Of note, the presence of these foreign materials did not seem to increase long-term recurrence, the only exception being arthroplasties performed for an unidentified echinococcal lesion.^{21,22}

Our research has several limitations. (i) Successful cases may have been reported more frequently than therapeutic failures. On the other hand, it is likely that difficult-to-treat cases or cases with particular bone involvement were more often published, whereas uncomplicated complete surgical resections are not mentioned. (ii) Physicians and surgeons in resource-rich countries who rarely see these cases might find them more interesting than surgeons living in endemic areas. Since there are no national registries of bone echinococcosis, we ignore the burden of worldwide disease beneath the 'tip of the iceberg'. (iii) The literature search was based on the Internet and relied on (Western) European languages. Even if most publications are written in these languages, there might be scientific work in local languages invisible on the Internet. (iv) Recurrence for bone hydatid disease not treated by excision may be difficult to interpret. We used the

progression of the cyst cavities or reappearance as defining criteria. It is theoretically possible that the parasite remains dormant in once-treated cysts without causing further harm. Whether this should be classified as persistent infection or remission is a philosophical question. (v) Our attempt to 'analyse statistically' 721 published cases may give only an estimate and by no means represents a valid statistical meta-analysis in proper terms.

Acknowledgements

We thank all our colleagues of the Orthopaedic Surgery Service of Geneva University Hospitals.

Funding

This study was conducted as part of our routine work.

Transparency declarations

None to declare.

I. U. had full access to all of the data in the study and takes responsibility for the integrity of the data and the accuracy of the analysis.

References

- Bouree P. Hydatidosis: dynamics of transmission. *World J Surg* 2001; **25**: 4–9.
- Ebrahimi A, Assadi M, Saghari M et al. Whole body bone scintigraphy in osseous hydatidosis: a case report. *J Med Case Rep* 2007; **1**: 93.
- Zlitni M, Ezzaouia K, Lebib H et al. Hydatid cyst of bone: diagnosis and treatment. *World J Surg* 2001; **25**: 75–82.
- Katz AM, Pan CT. *Echinococcus* disease in the United States. *Am J Med* 1958; **25**: 759–70.
- Scheuring UJ, Seitz HM, Wellmann A et al. Long-term benzimidazole treatment of alveolar echinococcosis with hematogenic subcutaneous and bone dissemination. *Med Microbiol Immunol* 2003; **192**: 193–5.
- Apt WL, Fierro JL, Calderon C et al. Vertebral hydatid disease. Clinical experience with 27 cases. *J Neurosurg* 1976; **44**: 72–6.
- Papanikolaou A. Osseous hydatid disease. *Trans R Soc Trop Med Hyg* 2008; **102**: 233–8.
- Song XH, Ding LW, Wen H. Bone hydatid disease. *Postgrad Med J* 2007; **83**: 536–42.
- Ayles HM, Corbett EL, Taylor I et al. A combined medical and surgical approach to hydatid disease: 12 years' experience at the Hospital for Tropical Diseases, London. *Ann R Coll Surg Engl* 2002; **84**: 100–5.
- Özdemir HM, Oğun TC, Taşbaş B. A lasting solution is hard to achieve in primary hydatid disease of the spine: long-term results and an overview. *Spine* 2004; **29**: 932–7.
- Yıldız Y, Bayrakçı K, Altay M et al. The use of polymethylmethacrylate in the management of hydatid disease of bone. *J Bone Joint Surg Br* 2001; **83**: 1005–8.
- Zia S, Enam A, Salahuddin I et al. Role of irrigation with hypertonic saline for a recurrent skull base hydatid cyst: case report and review of the literature. *Ear Nose Throat J* 2010; **89**: 22–6.
- Vittinghoff E, McCulloch CE. Relaxing the rule of ten events per variable in logistic and Cox regression. *Am J Epidemiol* 2007; **165**: 710–8.
- Jain S, Chopra P. Cystic echinococcosis of the pelvic bone with recurrences: a case report. *Korean J Parasitol* 2011; **49**: 277–9.
- Infanger M, Kossmehl P, Grimm D. Surgical and medical management of rare echinococcosis of the extremities: pre- and post-operative long-term chemotherapy. *Scan J Infect Dis* 2005; **37**: 954–7.
- Heinze J, Junginger W, Muller G et al. Anaphylactic shock during excision of an intraosseous *Echinococcus granulosus* cyst. *Anesthesist* 1987; **36**: 659–61.
- Uçkay I, Harbarth S, Peter R et al. Preventing surgical site infections. *Expert Rev Anti Infect Ther* 2010; **8**: 657–70.
- Natarajan MV, Kumar AK, Sivaseelam A et al. Using a custom mega prosthesis to treat hydatidosis of bone: a report of 3 cases. *J Orthop Surg (Hong Kong)* 2002; **10**: 203–5.
- Altıntaş N. Past to present: echinococcosis in Turkey. *Acta Trop* 2003; **85**: 105–12.
- Turtas S, Viale ES, Pau A. Long-term results of surgery for hydatid disease of the spine. *Surg Neural* 1980; **13**: 468–70.
- Notarnicola A, Panella A, Moretti L et al. Hip joint hydatidosis after prosthesis replacement. *Int J Infect Dis* 2010; **14**: 287–90.
- Voutsinas S, Sayakos J, Smyrnis P. *Echinococcus* infestation complicating total hip replacement. A case report. *J Bone Joint Surg Am* 1987; **69**: 1456–8.
- Sasani M, Özer AF. Spontaneous drainage of an asymptomatic recurrent hydatid cyst of the sacrum. *Spine* 2009; **34**: 269–71.
- Kural C, Uğraş AA, Sungur I et al. Hydatid bone disease of the femur. *Orthopedics* 2008; **31**: 712.
- Kotil K, Tatar Z, Bilge T. Spinal hydatidosis accompanied by a secondary infection. Case report. *J Neurosurg Spine* 2007; **6**: 585–90.
- Samadian M, Alavi E, Sharifi G et al. Extension of echinococcal spinal infestation extra- and intradurally after a decade of extinction. *J Neurosurg Sci* 2010; **54**: 143–8.
- Jensen B, Reuter S, Kratzer W et al. Long-term seropositivity against *Echinococcus multilocularis* in an epidemiological follow-up study in southwestern Germany (Romerstein). *Infection* 2001; **29**: 310–4.
- Bonifacino R, Dogliani E, Craig PS. Albendazole treatment and serological follow-up in hydatid disease of bone. *Int Orthop* 1997; **21**: 127–32.
- Rod-Fleury T, Dunkel N, Assal M et al. Duration of post-surgical antibiotic therapy for adult chronic osteomyelitis: a single-centre experience. *Int Orthop* 2011; **35**: 1725–31.
- Uçkay I, Jugun K, Gamulin A et al. Chronic osteomyelitis. *Curr Infect Dis Rep* 2012; **14**: 566–75.
- Guidelines for treatment of cystic and alveolar echinococcosis in humans. *Bull World Health Organ* 1996; **74**: 231–42.
- Reuter S, Jensen B, Buttenschoen K et al. Benzimidazoles in the treatment of alveolar echinococcosis: a comparative study and review of the literature. *J Antimicrob Chemother* 2000; **46**: 451–6.