

## Review

# Mechanisms of biliary carcinogenesis: A pathogenetic multi-stage cascade towards cholangiocarcinoma

F. Holzinger, K. Z'graggen & M.W. Büchler

Department of Visceral and Transplantation Surgery, Inselspital, University of Berne, Switzerland

### Summary

Carcinomas of the biliary tract are rare cancers developing from the epithelial or blast-like cells lining the bile ducts. A variety of known predisposing factors and recent experimental models of biliary carcinogenesis (e.g., infection with the liver fluke *Opisthorchis viverrini*, models of chemically induced carcinogenesis and experimental models of pancreaticobiliary maljunction) have elucidated different stages of this complex system of biliary tumorigenesis. Chronic inflammatory processes, generation of active oxygen radicals, altered cellular detoxification mechanisms, activation of oncogenes, functional loss of tumor-suppressor genes and dysregulation of cell proliferation and cell apoptotic mechanisms have been identified as important contributors in the development of cholangiocarcinomas. In this review, the known

mechanisms involved in the carcinogenesis of biliary epithelium are addressed. We will divide the topic into four stages: 1) Predisposition and risk factors of biliary cancer. 2) Genotoxic events and alterations leading to specific DNA damage and mutation patterns. 3) Dysregulation of DNA repair mechanisms and apoptosis, permitting survival of mutated cells and 4) Morphological evolution from premalignant biliary lesions to cholangiocarcinoma. Finally, established and hypothetical future therapeutic strategies directed towards specific pathogenetic events during biliary carcinogenesis will be addressed.

**Key words:** apoptosis, biliary carcinogenesis, cholangiocarcinoma, genotoxicity, risk factors, therapeutic strategies

### Introduction

Carcinomas of the biliary tract arise from either bile duct epithelial (oval) cells termed cholangiocytes or non-epithelial blast-like cells distributed among the oval/bile ductule epithelial cells. Cholangiocarcinoma (CC) represents a relatively rare cancer and its prevalence in autopsy series is reported as 0.01%-0.5% [1]. Despite its rarity, a variety of predisposing factors have been identified in epidemiological and clinical series during the past decades. Consequently, various biliary cancer models were established, that investigate the initiating mechanisms involved in biliary carcinogenesis. Such experimental and clinical tumor models are the liver fluke infection with *Opisthorchis viverrini* (OV) [2-4], models of anomalous arrangement of the pancreaticobiliary ducts (APBD) and bilioenterostomy [5,6], clinical series of patients with congenital bile duct cysts (CBDC) and pancreaticobiliary maljunctions (PBM) [7-9] and tumor induction models that use chemical hepatobiliary carcinogens such as N-nitrosobis(2-oxopropyl)amine (BOP) [6,10] or diethylnitrosamine (DEN) [11]. With the introduction of translational research methods (e.g. polymerase chain reaction (PCR)), a number of oncogenes, tumor-suppressor genes and apoptotic proteins involved in biliary carcinogenesis have been identified [12-14]. Finally, histomorphological studies have provided some evidence, that at least in the gallbladder [15,16] and ampulla of Vater the sequence "intestinal metaplasia-dysplasia-carcinoma" is significant in biliary carcinogenesis [17]. However, despite the recent insights into the mechanisms involved in biliary carcinogenesis, the key events and specific links in this multi-stage cascade leading to transformation of

cholangiocytes into malignant cells remain unknown and will need further investigations.

### Stage I: Predisposition to biliary carcinogenesis

Table 1 summarizes the identified risk-factors of biliary carcinogenesis and for some of the predisposing conditions, the relative risk to develop CC compared to the general population has been estimated (Table 1). The common denominator for biliary metaplasia, dysplastic epithelial transformation, and epithelial proliferation seems to be chronic inflammation through chemical and/or mechanical irritation and cholestasis with activation of injurious pancreatico-biliary compounds and carcinogens.

#### Anatomic Anomalies:

Congenital bile duct cysts (CBDC), pancreaticobiliary maljunction (PBM) and Caroli's disease have been clearly identified to be precursors of biliary cancer. It has been suggested, that there is an etiological link between congenital bile duct cyst formation and PBM, since several clinical series report coincidence of these two conditions in over 90% of cases [8,18]. In CBDC with PBM chronic exposure of the biliary epithelium to a regurgitated mixture of bile and pancreatic juice is due to an impaired sphincter of Oddi function and induces chronic inflammation. In comparison to normal bile, an elevated amylase level, preactivation of trypsin, phospholipase A2 and elastase I, and deconjugated secondary bile acids (e.g. lithocholic acid, deoxycholic acid) are found in the bile of patients with CBDC and PBM [8,9,19,20]. Retention of these injurious and comutagenic substances in the dilated bile duct and/or gallbladder seems

**Table 1.** Predisposition to biliary carcinogenesis and relative risk (rR) to develop cholangiocarcinoma compared to the general population

	Predisposition	rR
1. Anatomic Anomalies:	- Congenital bile duct cysts	86x
	- Caroli's disease	NA
	- PBM	32x
2. Chronic inflammatory conditions:	- PSC	30x
	- Typhoid carriers (gallbladder)	6x
	- Porcelain gallbladder	25x
	- Parasites:	
	- <i>Opisthorchis viverrini</i> (OV) 5x - <i>Clonorchis sinensis</i> (CS) 5x	
3. Biliary calculi	- Cholecystolithiasis	NA
	- Hepatolithiasis	NA
4. Carcinogens:	- Nitrosamines (BOP, DEN)	NA
	- Thorotrast	303x
	- Betel nut	NA
5. Autoimmune diseases:	- PSC	30x
	- PBC	30x
	- CUC	75x

Abbreviations: rR - relative risk; NA - not available; PBM - pancreaticobiliary maljunction; PSC - primary sclerosing cholangitis; BOP - N-nitrosobis(2-oxopropyl)amine; DEN - diethylnitrosamine; PBC - primary biliary cirrhosis; CUC - chronic ulcerative colitis

to initiate proliferative epithelial processes with possible activation of the carcinogenic cascade.

#### *Chronic inflammatory conditions*

Primary sclerosing cholangitis (PSC) is the most important risk-factor for CC in the Western countries. In autopsy studies CC is present in 33%-42% of patients with PSC [21]. In a series of 30 patients by Rosen and colleagues the diagnosis of PSC preceded diagnosis of CC by a mean of 52 months [21]. Since PSC mostly develops in patients with chronic ulcerative colitis (CUC), similar mechanisms for carcinogenesis of bile duct cancer in PSC and colon cancer in CUC have been assumed. In fact, identical *K-ras* gene point mutations were found in the biliary and colonic epithelial tumor cells of these patients.

Chronic cholangitis, the chronic infected gallbladder of typhoid carriers and the porcelain gallbladder (calcification of the gallbladder) represent endpoints of sustained chronic inflammation and all these conditions have an elevated risk of developing CC.

#### *Parasites*

The association between CC and the presence of liver flukes (*Opisthorchis viverrini* (OV) and *Clonorchis sinensis* (CS)) has been very well established [2,4]. Infection is acquired by eating raw or undercooked cyprinid fish contaminated with encysted metacercariae of the parasites. The flukes chronically infect the intrahepatic bile ducts, the gallbladder as well as the pancreatic duct. It has been suggested, that the parasite infestation by itself is not strongly carcinogenic but exerts a marked promoting influence on cholangiocellular tumor development via chronic irritation and increased cell turnover, rendering the cells susceptible to either exogenous or endogenous carcinogens [3]. Furthermore, Haswell-Elkins [2] and Oshima [4] have shown among others, that OV-infected subjects, as identified by the presence of OV eggs in the feces, had increased biosynthesis of nitrosamines and increased nitrosation potential of macrophages compared to uninfected subjects. Their data supports the hypothesis that

infection with OV increases the generation of genotoxic nitric oxide (NO), as estimated by elevated salivary nitrite and urinary nitrate levels in infected subjects [2,4].

#### *Biliary calculi*

Gallstones are found in 70-98% of gallbladders resected for carcinoma [22]. The hypothetical link between gallstones and carcinoma of the gallbladder relates to the chronic mechanical irritation and inflammation of the biliary epithelium. A recent investigation by Ekblom and colleagues concluded, that gallstones may also play a causative role in the development of extrahepatic bile duct cancer, since a significant decrease in the incidence of cholangiocarcinoma 10 or more years after cholecystectomy for cholecystolithiasis was shown [23]. In analogy to cholecystolithiasis, hepatolithiasis, which is not uncommon in East Asia, has been observed in an impressive proportion (up to 17.5%) of registered cases of CC in these countries [24]. The liver containing intraductal hepatoliths (mostly calcium-bilirubinate) show features of chronic proliferative cholangitis in vicinity to stone-bearing ducts [25].

#### *Carcinogens:*

Nitrosamines are potent carcinogens experimentally inducing tumors in different organs and are suspected to play a role in human carcinogenesis. Exposure occurs through dietary intake of preformed nitrosamines, through tobacco use and through endogenous nitrosation of nitrogenous compounds via nitric oxide (NO) [4]. However, in vivo little is known about the carcinogenic concentration and the time of exposure necessary to induce biliary cancer.

Thorotrast, a radioactive  $\alpha$ -particle emitter, was widely used as a radiocontrast medium between 1930 and 1955. 10-12 years after exposition, liver cancer and cholangiocarcinoma developed in a large number of Thorotrast treated patients. Proliferative and dysplastic changes of the bile duct epithelium were noted in the noncancerous areas of Thorotrast-induced cholangiocarcinomas which possibly represent precursor lesions of these cancers [26].

#### *Autoimmune diseases:*

Three autoimmune diseases, primary biliary cirrhosis (PBC), PSC and CUC, have been identified as predisposing conditions in the development of CC. As mentioned above, PSC and CUC are often linked, since 75%-83% of patients with PSC have evidence of CUC. The lifetime risk to develop CC in patients with CUC was estimated to be 1.4% [27]. Total proctocolectomy does not protect against the development of CC which usually appears 15-20 years after the onset of CUC.

## **Stage II: Genotoxic cellular events**

Genotoxic cellular events which may play an important role in biliary carcinogenesis have been summarized in Figure 1. Almost all predisposing factors present with the common features of chronic inflammation and/or cholestasis. The resident inflammatory cells are possibly involved in this carcinogenic process. Cytokines, namely TNF- $\alpha$  and Interleukin- $\lambda$  (IL- $\lambda$ ), are produced by activated macrophages, Kupffer cells and hepatocytes during inflammation. Macrophages activated by such cytokines produce nitric oxide (NO) and its derivatives, which have been shown to induce cytotoxic and mutagenic effects in target cells when

present in excess [4]. NO which has a double-edged role as an essential physiological signaling and a cytotoxic molecule reacts rapidly with superoxide anion and decomposes to the highly reactive and toxic hydroxyl radical (HO $\cdot$ ) and nitrogen dioxide (NO $_2$ ) [28]. It has been demonstrated that NO and its derivatives can induce DNA damage by deaminating DNA-nucleobases causing DNA strand breaks [29]. In addition, excessive NO production has been reported to be immunosuppressive in vitro, inhibiting lymphocyte proliferation [30].

Cellular detoxification is an important defensive mechanism against chemically induced carcinogenesis. UDP-glucuronosyltransferases (UGT) and glutathione (GSH) were specifically identified to provide the principal intracellular

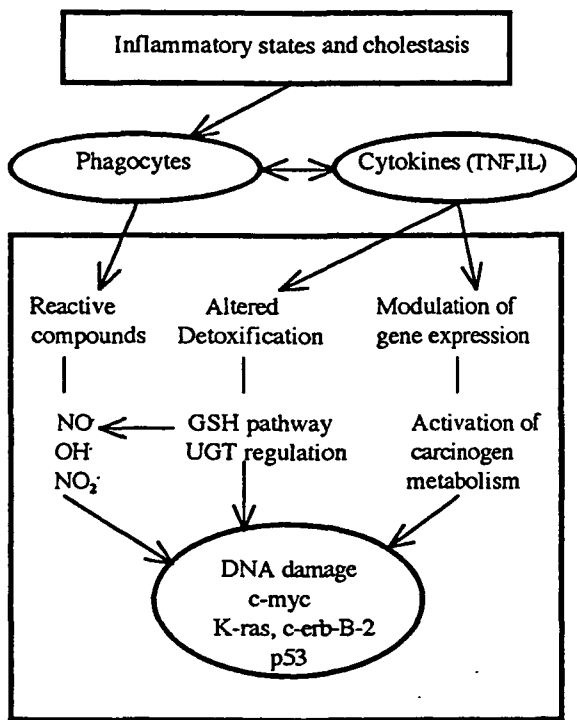


Figure 1. Proposed scheme of genotoxic events in the multistage process of biliary carcinogenesis

metabolic line of defense in eliminating hydrophobic and carcinogenic compounds [31,32]. Bioactivation of lipophilic compounds by cytochrome P-450S can result in the generation of reactive oxygen compounds. Conjugation with glucuronic acid by UGTs enables their elimination as hydrophilic conjugates. In human cholangiocarcinoma down-regulation of UGT1A4 and UGT1A10 has been demonstrated to be an early marker of biliary carcinogenesis [31]. GSH, which is secreted by hepatocytes into bile, maintains molecules in the reduced state, and similar to UGT, also participates in the detoxification of different carcinogenic molecules [32]. The inability to remove damaging cellular carcinogens predisposes cells to genetic alterations which can be followed by point-mutations of

proto-oncogenes and tumor suppressor genes, enhancing cell proliferation and/or inhibiting cell apoptosis. Over the past few years, specific mutation spectra of the growth promoting c-myc, K-ras and c-erb-B-2 oncogenes were identified in the majority of CC. The prevalence of K-ras mutations in CC is approximately 80%-100% and CC together with pancreatic cancer has the highest prevalence of such mutations [13,33,34]. K-ras point mutations have been localized in codon 12 with replacement of glycine (GGT) with aspartic acid (GAT) in most cases [13]. Proto-oncogene activity is necessary for mediating cell-cycle progression. Point mutations in specific domains of this gene family result in uncontrolled stimulation and signal transduction endowing the cells with a selective growth advantage [35]. On the side of apoptosis, loss of function of p53, a tumor suppressor gene, has been identified to occur in the later stage of nuclear tumor pathogenesis. Allelic loss or point mutations of codon 17p, which contains the tumor suppressor gene p53, has been demonstrated in approximately 40% of CC [36,37]. p53 encodes a 53 kd nuclear phosphoprotein that initiates cell cycle arrest or cell apoptosis, if excessive DNA damage has occurred [38]. A second important function of p53 is suppression of bcl-2 gene expression, an important gene involved in the key mechanisms of cell death regulation through apoptosis [39].

### Stage III: Dysregulation of DNA-repair and apoptosis leading to malignant transformation

Usually genotoxic events with DNA damage lead to either DNA-mismatch repair mechanisms or, if the damage is beyond repair, to cell death through apoptosis. Several proteases have been implicated in apoptosis, including members of the caspase (ICE) family [40]. Apoptosis is highly regulated by a growing number of members of the Bcl-2 family of proteins that block caspase activity [39]. These proteins are localized predominantly at the nucleolus membrane, endoplasmic reticulum and mitochondrial membranes. As mentioned above, loss of p53 function is followed by overexpression of Bcl-2. This overexpression contributes to the neoplastic expansion by prolonging cell survival and failure of apoptosis. Thus, as schematically drawn in Figure 2, overexpression of Bcl-2 and point

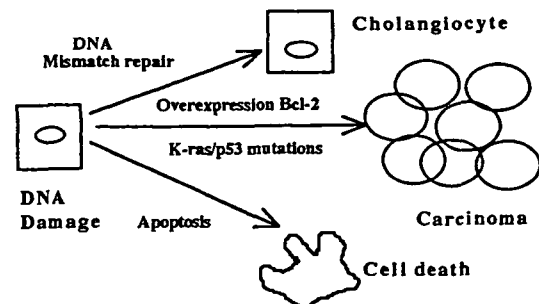


Figure 2. Dysregulation of DNA repair and apoptosis leading to survival of mutated cells progressing to cholangiocarcinoma (according to Celli et al. [39]).

mutations of p53 and K-ras may inhibit apoptosis of DNA damaged cholangiocytes, permitting survival of the mutated cell line with progress to CC [39].

#### Stage IV: Histomorphological aspects in biliary carcinogenesis

It has been suggested, that similar to colon and stomach cancer, cholangiocarcinoma arises from precancerous lesions in the biliary tract following the "intestinal metaplasia-dysplasia-carcinoma" sequence. At least for the gallbladder and papilla of Vater this hypothesis has been proven [15,16]. As a consequence gallbladder cancers present macroscopically more often as flat than as polypoid tumors [41]. Besides this sequence, "de novo" malignant epithelial transformation as well as cancer formation through adenoma has been suggested to play a role in histomorphological cancer development. Kozuka et al. [42] showed in a series of 1'605 cholecystectomies that the transition of benign adenoma to carcinoma is histologically traceable. The same authors [43] performed histological analysis of 22 invasive carcinomas of the papilla of Vater finding a rate of 82% of vestigial adenomas. The retrospective analysis of our own case material confirms both hypothesis [44]. The surgical specimens of fifty-eight patients with cancer of the ampulla of Vater were examined histologically for dysplastic changes and the incidence of adenomatous structures (Table 2). We found in 100% of the examined specimens epithelial dysplasia in the non-carcinomatous part of the ampulla, 82.8% of these being moderate to severe. In 91.4% adenomatous residues and adenomas were found, implicating that dysplasia and adenomas are developmental stages in the neoplastic transformation of the biliary epithelium and should be considered as pre-cancerous lesions. However, in some cases of carcinoma of the ampulla of Vater it remains uncertain which epithelium gave rise to the tumor and differentiation of bile duct cancer from tumors arising from the duodenal mucosa may be impossible.

Table 2: Histomorphological alterations of the non-tumor-infiltrated ampulla in the immediate vicinity of the carcinoma (n=58)

Epithelial dysplasia stage	%	Micro-adenomas of the mucosa, %	Macro-adenomas and adenomatous residues, %
I	17.2		
II	44.9	58.6	32.8
III	37.9		
Total:	100	adenoma structures	91.4

#### Therapeutic strategies

Because of the lack of characteristic symptoms and physical findings, benign biliary tumors and preneoplastic lesions are usually not diagnosed preoperatively. Nevertheless, there are some medical and surgical strategies which may be of some help in treating CC and decreasing its incidence.

Primary prevention of CC is available by the use of the drug Praziquantel in high-risk populations with a high prevalence of liver fluke infestation. Administered in a single dose it eliminates the parasites successfully from infested individuals.

Surgical and/or endoscopic removal of precancerous lesions is mandatory to prevent further progression into CC. Early surgical resection of choledochal cysts in patients with CBDC as well as complete excision of the extrahepatic biliary tract followed by reconstruction and biliopancreatic separation in patients with PBM may further decrease the incidence of biliary cancer and result in better survival, since prognosis of CC is still poor, even after extended resection [45]. After the onset of CC or gallbladder cancer the therapeutic strategies are very limited. Only extended surgical resectional procedures may offer a chance for cure. Vitamin C and other antioxidants may be effective in high-risk patients by interacting with the NO synthase, thus decreasing endogenous nitrosation and formation of reactive derivatives. Antioxidants may also decrease oxidative stress-induced apoptosis.

Attempts are underway to develop new procedures for targeting the ras protein oncogene products and mutated p53-associated signal transduction pathways [36], thus interacting with unregulated cell proliferation and apoptosis. In the future, CC may be tested for oncogene and tumor suppressor gene targeted therapy. New approaches with Bcl-2 phosphorylators and antisense oligonucleotides targeted against Bcl-2 are investigated. They may increase tumor cell susceptibility to chemotherapeutic agents [36,46].

Therefore, the primary goal of therapeutic strategies has to be the disconnection of the pathogenetic cascade which leads to the development of CC.

#### References

- Parkin DM, Ohshima H. Cholangiocarcinoma: Epidemiology, mechanisms of carcinogenesis and prevention. *Cancer Epidemiol Biomarkers Prevent* 1993;2:537-544
- Haswell-Elkins MR, Satarug S, Tsuda M et al. Liver fluke infection and cholangiocarcinoma: Model of endogenous nitric oxide and extragastric nitrosation in human carcinogenesis. *Mutation Research* 1994;305:241-52
- Thamavit W, Tiwawech D, Moore MA et al. Equivocal evidence of complete carcinogenicity after repeated infection of syrian hamsters with *Opisthorchis viverrini*. *Toxicol Pathol* 1996;24:493-7
- Ohshima H, Bartsch H. Chronic infections and inflammatory processes as cancer risk factors: Possible role of nitric oxide in carcinogenesis. *Mutation Research* 1994;305:253-64
- Masamune K, Kunitomo K, Sasaki K et al. Bile-induced DNA strand breaks and biochemical analysis of bile acids in an experimental model of anomalous arrangement of the pancreaticobiliary ducts. *J Med Invest* 1997;44:47-51
- Ikematsu Y, Tomioka T, Yamanaka S et al. Bilioenterostomy enhances biliary carcinogenesis in hamsters. *Carcinogenesis* 1996;17:1505-9
- Komi N, Tamura T, Miyoshi Y et al. Histochemical and immunohistochemical studies on development of biliary carcinoma in forty-seven patients with choledochal cysts-special reference to intestinal metaplasia in the biliary duct. *Jap J Surg* 1985;15:273-8
- Iwai N, Yanagihara J, Tokiwa K et al. Congenital choledochal dilatation with emphasis on pathophysiology of the biliary tract. *Ann Surg* 1992;215:27-30
- Matsubara T, Tsuji T, Miyama A et al. Mutagenicity of bile and pancreatic juice from patients with pancreatico-biliary maljunction. *Hepato-Gastroenterol* 1995;42:113-6
- Ikematsu Y, Tomioka T, Tajima Y et al. Enhancement of biliary carcinogenesis in hamsters by cholecystokinin. *World J Surg* 1995;19:847-51
- Novikoff PH, Yam A, Oikawa I. Blast-like cell compartment in carcinogen-induced proliferating bile ductules. *Am J Pathol* 1996;148:1473-92
- Watanabe M, Asaka M, Tanaka J et al. Point mutation of K-ras gene codon 12 in biliary tract tumors. *Gastroenterol* 1994;107:1147-53
- Matsubara T, Sakurai Y, Sasayama Y et al. K-ras point mutations in cancerous and noncancerous biliary epithelium in patients with pancreaticobiliary maljunction. *Cancer* 1996;77:1752-7
- Que FG, Gores GJ, LaRusso NF. Development and initial application of an

- vitro model of apoptosis in rodent cholangiocytes. *Am J Physiol* 1997;272:G106-G115
15. Albores-Saavedra J, Alcantra-Vazquez A, Cruz-Ortiz H et al. The precursor lesions of invasive gallbladder carcinoma. *Cancer* 1980;45:919-27
  16. Yamagiwa H, Tomiyama H. Intestinal metaplasia-dysplasia-carcinoma sequence of the gallbladder. *Acta Pathol Jpn* 1986;36:989-97
  17. Holzinger F, Baer HU, Büchler MW. Mechanisms of biliary carcinogenesis and preneoplastic lesions. *Dig Surg* 1995;12:208-14
  18. Kimura K, Ohtho M, Saisho H et al. Association of gallbladder carcinoma and anomalous pancreaticobiliary ductal union. *Gastroenterology* 1985;89:1258-65
  19. Mizuno M, Kato T, Koyama K. An analysis of mutagens in the contents of the biliary tract in pancreaticobiliary maljunction. *Surg Today* 1996;26:597-602
  20. Reveille RM, Stiegmann VG, Everson GT. Increased secondary bile acids in a choledochal cyst: Possible role in biliary metaplasia and carcinoma. *Gastroenterology* 1990;99:525-7
  21. Rosen CB, Nagorney DM, Wiesner RH et al. Cholangiocarcinoma complicating primary sclerosing cholangitis. *Ann Surg* 1991;213:21-5
  22. Diehl AK. Epidemiology of gallbladder cancer: A synthesis of recent data. *J Nat Cancer Inst* 1980;65:1209-14
  23. Ekbohm A, Hsieh CC, Yuen J et al. Gallstones and bile duct cancer. *Gastroenterology* 1994;107:1205-6
  24. Sugihara S, Kojiro M. Pathology of cholangiocarcinoma. In: Okuda K and Ishak KG (eds.), *Neoplasms of the liver*. Tokyo: Springer, 1987
  25. Terada T, Nakanuma Y, Ohta T et al. Histological features and interphase nucleolar organizer regions in hyperplastic, dysplastic and neoplastic epithelium of intrahepatic bile ducts in hepatolithiasis. *Histopathology* 1992;21:233-40
  26. Rubel LR, Ishak KG. Thorotrast associated cholangiocarcinoma: An epidemiologic and clinicopathologic study. *Cancer* 1982;50:1408-15
  27. Akwari OE, van Heerden JA, Foulk WT et al. Cancer of the bile ducts associated with ulcerative colitis. *Ann Surg* 1975;181:303-9
  28. Beckman JS, Beckman TW, Chen J et al. Apparent hydroxyl radical production by peroxynitrite: Implications for endothelial injury from nitric oxide and superoxide. *Proc Natl Acad Sci* 1990;87:1620-4
  29. Nguyen T, Brunson D, Crespi CL et al. DNA damage and mutation in human cells exposed to nitric oxide in vitro. *Proc Natl Acad Sci* 1992;89:3030-4
  30. Kawabe T, Isobe KI, Hasegawa Y et al. Immunosuppressive activity induced by nitric oxide in culture supernatant of activated rat alveolar macrophages. *Immunology* 1992;76:72-8
  31. Strassburg CP, Manns MP, Tukey RH. Differential down-regulation of the UDP-Glucuronosyltransferase 1A locus is an early event in human liver and biliary cancer. *Cancer Res* 1997;57:2979-85
  32. Deleve LD, Kaplowitz N. Importance and regulation of hepatic glutathione. *Sem Liver Dis* 1990;10:251-66
  33. Levi S, Urbano-Ispizua A, Gill R et al. Multiple K-ras codon mutations in cholangiocarcinomas demonstrated with a sensitive polymerase chain reaction technique. *Canc Res* 1991;51:3497-3502
  34. Zgraggen K, Rivera JA, Compton CC et al. Prevalence of activating K-ras mutations in the evolutionary stages of neoplasia in intraductal papillary mucinous tumors of the pancreas. *Ann Surg* 1997; 226: 491 - 500
  35. Tsutsumi M, Murakami Y, Kondoh S et al. Comparison of K-ras oncogene activation in pancreatic duct carcinomas and cholangiocarcinomas induced in hamsters by n-nitrosobis(2-hydroxypropyl)amine. *Japan J Canc Res* 1993;84:956-60
  36. Kiba T, Tsuda H, Pairojkul C et al. Mutations of the p53 suppressor gene and the ras gene family in intrahepatic cholangiocellular carcinomas in Japan and Thailand. *Molec Carcinog* 1993;8:312-8
  37. Ohashi K, Nakajima Y, Kanehiro H et al. K-ras mutations and p-53 protein expressions in intrahepatic cholangiocarcinomas: relation to gross tumor morphology. *Gastroenterology* 1995;109:1612-7
  38. Lane DP. p53, guardian of the genome. *Nature* 1992;358:15-6
  39. Celli A, Que FG. Dysregulation of apoptosis in the cholangiopathies and cholangiocarcinoma. *Sem Liv Dis* 1998;18:177-85
  40. Patel T, Gores GJ. Apoptosis and hepatobiliary disease. *Hepatology* 1995;21:1725-41
  41. Z'graggen K, Birrer S, Maurer CA et al. Incidence of port site recurrence after laparoscopic cholecystectomy for preoperatively unsuspected gallbladder carcinoma. *Surgery* 1998 (in press)
  42. Kozuka S, Tsubone M, Yasui A et al. Relation of adenoma to carcinoma in the gallbladder. *Cancer* 1982;50:2226-34
  43. Kozuka S, Tsubone M, Yamaguchi A. Adenomatous residues in cancerous papilla of Vater. *Gut* 1981;22:1031
  44. Büchler M, Malfertheiner P, Baczako K et al. Aspects of morphogenesis in carcinoma of the ampulla of Vater. *Dig Surg* 1986;3:15-20
  45. Holzinger F, Baer HU, Schilling M et al. Congenital bile duct cyst: A premalignant lesion of the biliary tract associated with adenocarcinoma - a case report. *Z Gastroenterol* 1996;34:382-5
  46. Harnois DM, Que FG, Celli A et al. Bcl-2 is overexpressed and alters the threshold for apoptosis in a cholangiocarcinoma cell line. *Hepatology* 1997;26:884-90

*Correspondence to:*

Markus W. Büchler, MD  
 Department of Visceral and Transplantation Surgery  
 Inselspital, University of Berne  
 CH-3010 Berne, Switzerland