

*Brief Report*

## **Histopathology of humorally mediated anti-glomerular basement membrane (GBM) glomerulonephritis in mice**

Michel Le Hir

Institute of Anatomy, University of Zurich, Zurich, Switzerland

### **Abstract**

**Background.** From a diagnostic point of view it would be important to learn more about the relationship between the immune responses underlying glomerulonephritis and the patterns of glomerular lesions. A murine model of anti-GBM glomerulonephritis in which inflammation is driven by delayed-type hypersensitivity (DTH) has been studied extensively. The aim of this study was to uncover histological features that might be specific for anti-GBM glomerulonephritis driven by a humoral immune response.

**Methods.** BALB/c mice were immunized with rabbit IgG in incomplete Freund's adjuvant. Six days later, on day 0, they received rabbit anti-GBM serum intravenously. Proteinuria was assessed with dipsticks. Mice were killed on days 4, 8 or 14. Kidneys from days 4 and 8 were processed for immunofluorescence and histology. On day 14 mice were perfusion-fixed for electron microscopy.

**Results.** Proteinuria started on day 3. Autologous IgG and of C3 were found along the GBM. There was only slight infiltration with macrophages and no measurable infiltration by CD4 T cells, indicating the virtual absence of DTH. Besides infiltration with neutrophils there were little histological alterations on day 4. On day 8 many loops were hyalinized. On day 14, cellular crescents were found in 23% of glomeruli. Subendothelial spaces contained hyaline material, cells and fibrin. Podocytes displayed effacement of foot processes and apical microprotrusions. Podocyte bridges were common. These alterations were identical to those reported in the standard model that produces a DTH-like inflammation.

**Conclusion.** The qualitative pattern of histological damage in a murine model of anti-GBM glomerulonephritis does not depend on the underlying immunological process.

**Keywords:** crescentic; glomerulonephritis; histology; mouse

---

### **Introduction**

Glomerulonephritis is a collective term for a heterogeneous group of diseases [1]. Since therapeutic interventions targeting immune responses are gaining specificity it would be highly desirable to define the immunological basis of inflammatory glomerular diseases in any individual case. One way to reach that aim might be to improve the diagnostic potential of histopathology. Indeed, it seems reasonable to assume that a given immunological process might elicit a given pattern of histological alterations. In reverse, one might expect that histopathology allows conclusions concerning the underlying immunological response. For the following reasons experimental anti-GBM glomerulonephritis seems appropriate in order to disclose association of specific histological features with specific immunological processes. First, the antigen, a foreign immunoglobulin planted in the GBM, is known. Secondly, the disease is initiated at a precise time point that is at the injection of anti-GBM serum. Thirdly, many studies have been carried out, revealing essential aspects of the immunological background and of the histopathology of the disease.

In humans anti-glomerular basement membrane (anti-GBM) glomerulonephritis is an autoimmune disease. The following findings suggest a major role of humoral mediators of immunity. Immunoglobulins and C3 are found in a linear pattern along the GBM [2,3]. Antibodies eluted from the kidneys of patients induce glomerulonephritis in squirrel monkeys [4]. Transfer of the disease by antibodies has also been achieved in a murine model [5]. However, infiltration of glomeruli with T helper cells and macrophages in human anti-GBM glomerulonephritis [6] suggest a role of cellular immunity and, more specifically, of delayed-type hypersensitivity (DTH). Furthermore, the severity of

---

*Correspondence and offprint requests to:* Michel Le Hir, Institute of Anatomy, University of Zurich, Winterthurerstrasse 190, CH-8057 Zurich, Switzerland. Email: lehir@anatom.unizh.ch

anti-GBM glomerulonephritis in rats and mice immunized against the alpha-3 chain of type IV collagen, a major antigen in the human disease [2,3], correlates better with the cellular immune response than with the humoral immune response [3,7]. It is thus likely that, depending on genetic factors and on environmental factors anti-GBM glomerulonephritis is driven by a cellular immune response, by a humoral immune response or by both.

The histopathology of glomerulonephritis driven by cellular immunity has been described previously in a murine model of anti-GBM glomerulonephritis [8–10]. In that model C57BL/6 mice receive an i.v. injection of anti-GBM serum a few days after immunization against the immunoglobulins of the donor species. Complete Freund's adjuvant (CFA) is used for immunization. That protocol yields a virtually pure DTH-type inflammation in the glomerulus [10,11]. Infiltration by macrophages and T-cells, the characteristic cellular mediators in DTH, is followed by intracapillary alterations and by the rapid development of cellular crescents [8–10].

The present study examined the pattern of histological lesions in anti-GBM glomerulonephritis under conditions where inflammation is initiated by humoral mediators of immunity. The aim was to compare the findings with those of the previous studies describing DTH-mediated anti-GBM glomerulonephritis in mice [8–10] and thus to discover glomerular alterations that were specific for cell-mediated inflammation or humorally mediated inflammation. BALB/c mice were used because in that strain, in contrast to the C57BL/6 strain, glomerulonephritis relies essentially on a humoral immune response when induced by the standard protocol outlined above [12]. In order to reduce further the influence of DTH in glomerular inflammation we immunized the mice with incomplete Freund's adjuvant (IFA) instead of CFA. As expected, with the modified protocol glomerulonephritis developed without measurable infiltration with CD4+ T cells and there was only slight infiltration with macrophages. Still, histopathology revealed qualitatively similar features as in the classical model of DTH-type glomerular inflammation in C57BL/6 mice immunized in the presence of CFA.

## Subjects and methods

### *Induction of anti-GBM glomerulonephritis*

Female BALB/c mice, 9–12 weeks old, were immunized by s.c. injection of 0.2 mg of rabbit IgG (Jackson ImmunoResearch Laboratories, West Grove, PA, USA) in 0.2 ml of a 1:1 emulsion with IFA (Sigma, St Louis, MO, USA). Six days later (day 0) glomerulonephritis was induced by i.v. injection of rabbit anti-mouse GBM serum prepared as described previously [13]. Unless otherwise stated the dose of antiserum was 100 µl. Control animals were immunized with rabbit IgG but did not receive anti-GBM serum. The experimental protocol had been approved by the Veterinary Office of the Canton of Zurich.

### *Cutaneous test for DTH*

Six female BALB/c mice were immunized with rabbit IgG as described above. Ten days after immunization 20 µl of 1 mg/ml rabbit IgG or of 1 mg/ml bovine serum albumin were injected in the right and left footpad, respectively. The difference of thickness between the two feet 24 h after injection of antigen was taken as measure of DTH.

### *Proteinuria*

Micturition was evoked by holding the skin of the neck in a firm grip. Protein concentration in urine was assessed using dip sticks (Albustix, Miles Inc., USA). Values of 0 (traces), 0.3, 1, 3 or 20 mg/ml were attributed according to the colour scale provided by the producer.

### *Histology of immersion-fixed tissue*

Mice were killed by inhalation of diethylether on days 4 or 8. The right kidney was immersion-fixed in 4% buffered paraformaldehyde (PFA) and processed for paraffin sectioning. Three slices from each kidney were embedded. Three micrometre thick sections were stained with the periodic acid-Schiff reagent (PAS), followed by haematoxylin. At least 50 glomeruli were evaluated per kidney for the presence of crescents.

### *Immunofluorescence*

The left kidney was snap-frozen in isopentane cooled by liquid nitrogen. Six-micrometre thick sections were cut in a cryostat, air-dried and stored at –20°C. Fixation in acetone (10 min at 4°C) was performed just before the immunolabelling. After a rinse in Tris-buffered saline the sections were incubated for 16 h at 4°C with the primary antibodies diluted in TBS. The following rat anti-mouse monoclonal antibodies were used: anti-CD3 (clone KT3), anti-CD4 (clone YTS 191.1.2), anti-granulocytes (clone RB6-8C5) and anti-MHC class II (clone M5/114.15.2). The sections were then washed in TBS and incubated for 1 h at room temperature with a Cy3-labelled mouse anti-rat immunoglobulin antibody (Jackson Immuno Research Laboratories, West Grove, PA, USA). After rinsing in TBS the sections were mounted in Immumount (Shandon, Pittsburgh, PA, USA). Immunoreactive cells and T helper cells were counted on cryosections in at least 50 glomerular cross-sections per mouse. Since the incidence of B cells identified with anti-B220 (clone RA36B2) was always <0.1 cell/glomerular cross-section, the majority of MHC class II-positive cells in glomeruli were probably macrophages.

### *Histology of perfusion-fixed tissue*

On day 14, mice were anaesthetized with 17 mg/kg body weight xylazine hydrochloride and 50 mg/kg body weight ketamine hydrochloride, intraperitoneally. Kidneys were fixed by vascular perfusion via the abdominal aorta. The fixative consisted of 3% PFA, and 0.05 % picric acid. It was dissolved in a 3:2 mixture of 0.1 M cacodylate buffer (pH 7.4, adjusted to 300 mosm with sucrose) and 10% hydroxyethyl starch in saline (HAES; Fresenius AG, Germany). After 5 min

of fixation *in situ* the kidneys were removed and cut into coronal slices. Some slices were embedded in paraffin. The remaining tissue was immersed for at least 24 h in the 3% PFA fixative solution, to which 0.5% glutardialdehyde was added. Thereafter, the tissue was post-fixed in 1% OsO<sub>4</sub> and embedded in epoxy resin.

Light microscopical investigations were carried out on sections of 1 μm thickness, cut from epoxy resin-embedded tissue and stained with azur II-methylene blue.

For TEM, ultra-thin sections from epoxy resin-embedded tissue were contrasted with uranyl acetate and lead citrate.

### Statistics

Unless otherwise specified each experimental group consisted of six mice. Mean values are given with the SEM. Variance analysis was performed using the ANOVA software, with a significance level of 5% in the Fischer PLSD test.

## Results

In a pilot experiment aimed at selecting a dose of anti-GBM serum, BALB/c mice were either immunized with rabbit IgG in IFA or they were injected with IFA alone. They received an i.v. injection of 25, 50 or 100 μl of anti-GBM serum. Each experimental group comprised three mice. Proteinuria was evaluated daily for 6 days using dipsticks. With 25 μl of antiserum in immunized mice as well as with either of the three doses of antiserum in non-immunized mice urinary protein concentration remained in the control range, not exceeding 0.3 mg/ml. With 50 μl of antiserum in immunized mice, protein concentration did not exceed 1 mg/ml. The three immunized mice that received 100 μl of antiserum reached values between 3 and 20 mg/ml on day 6.

### Mediators of inflammation

The aim of the next experiment was to examine the presence of inflammatory mediators in glomeruli. Twelve mice were immunized. Glomerulonephritis was induced in six of them by injection of anti-GBM serum whereas the other six were injected s.c. in the footpad with rabbit IgG for evaluation of the DTH response. The kidneys of the latter mice were used as controls in the evaluation of glomerulonephritis.

There was no measurable DTH response to rabbit IgG. Foot swelling was  $0.04 \pm 0.02$  mm. Using the same

procedure we measured ~1 mm swelling in C57BL/6 mice immunized with CFA [14].

In the anti-GBM-treated groups, proteinuria started on day 3 (Figure 1). The mice were killed on day 8 after injection of anti-GBM serum. Intraglomerular inflammatory cells were counted in immunolabelled cryosections (Table 1). There was a strong infiltration by neutrophilic granulocytes and a small infiltration with macrophages (MHC class II-positive) on day 8. In glomerulonephritic mice the incidence of CD3+ cells was slightly higher than in controls but the incidence of CD4+ T cells was similar in both groups. Immunofluorescence revealed a linear deposition of mouse IgG and of C3 along the GBM (Figure 2).

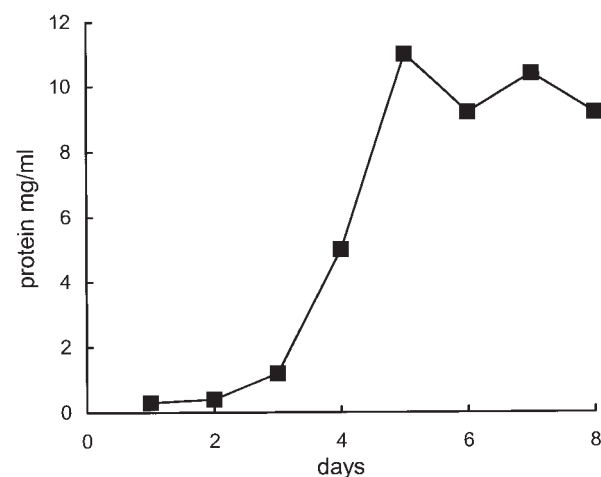


Fig. 1. Time course of proteinuria in glomerulonephritic mice.

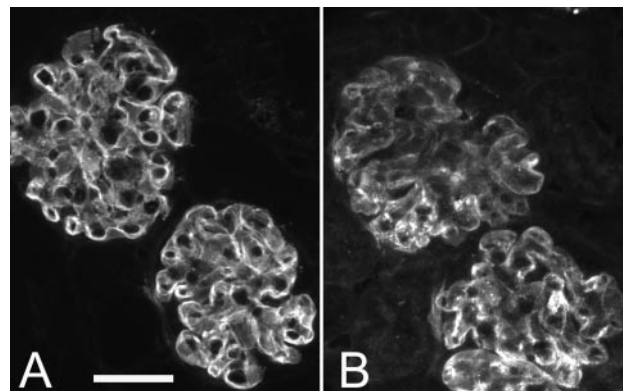
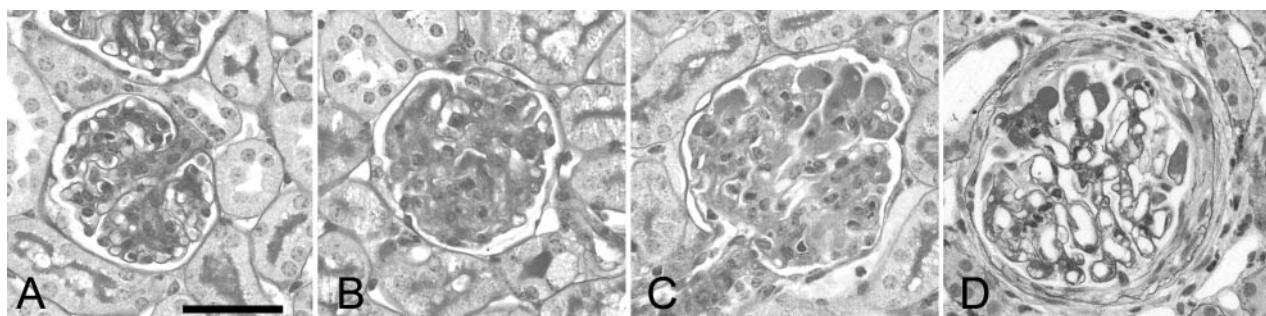


Fig. 2. Immunofluorescence for mouse IgG (A) and for C3 (B) in glomerulonephritic mice. Bar, 50 μm.

Table 1. Incidence of infiltrating cells, expressed as the number of cells per glomerular cross-section

	CD3+	CD4+	MHC class II+	Granulocytes
d4, control	0.147 ± 0.032	0.105 ± 0.027	0.297 ± 0.050	0.083 ± 0.018
d4, glomerulonephritis	0.132 ± 0.018	0.123 ± 0.027	0.492 ± 0.059 <sup>a</sup>	2.917 ± 0.760 <sup>a</sup>
d8, control	0.200 ± 0.035	0.102 ± 0.016	0.393 ± 0.039	0.107 ± 0.026
d8, glomerulonephritis	0.324 ± 0.026 <sup>a</sup>	0.118 ± 0.025	0.974 ± 0.090 <sup>a</sup>	0.920 ± 0.088 <sup>a</sup>

<sup>a</sup>Statistically significant difference, compared with the control group.



**Fig. 3.** Histology of glomeruli in control (A) and in glomerulonephritic (B, day 4; C, day 8; D, day 14). A circumferential crescent is seen in (D). PAS staining. Bar, 50  $\mu$ m.

In order to make sure that we did not miss an early T cell infiltration, we performed an additional experiment, in which mice were killed on day 4 after injection of anti-GBM serum, that is 1 day after the start of proteinuria. Urinary protein concentration on days 3 and 4 were  $1.3 \pm 0.3$  and  $3.3 \pm 1.3$  mg/ml, respectively. Again there was no infiltration with CD4 T cells, whereas the incidence of granulocytes was already very high on day 4 (Table 1).

#### Histopathology

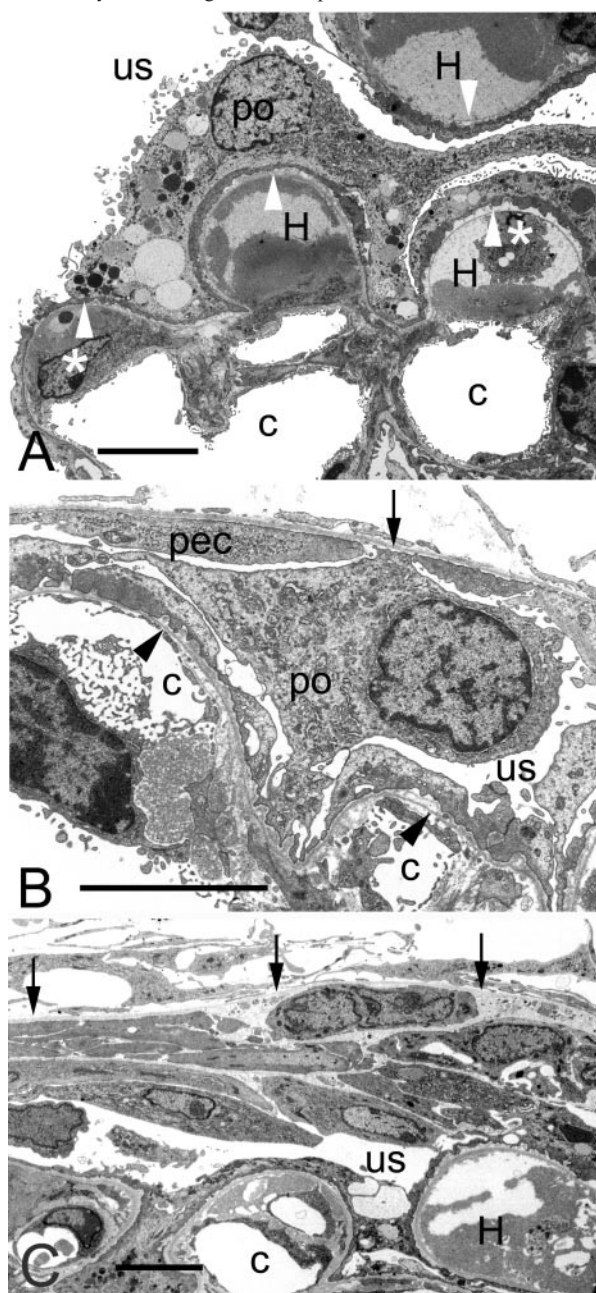
The kidneys of the mice used in the experiments described above were examined by histology on paraffin sections (Figure 3). Endocapillary lesions on day 4 and on day 8 were evidenced mainly by increased amounts of PAS-positive material. This material was probably identical with the subendothelial hyaline proteinaceous material, which was seen in the electron microscope (see below). Capillary necrosis and hyalinization of loops was occasional on day 4 but frequent on day 8. There was no global glomerular hypercellularity, but on day 8 segmental hypercellularity was visible in some glomeruli. Elongated and segmented nuclei, which were found on day 4 and on day 8 in capillary loops represented probably neutrophil granulocytes. Crescents were found in  $2.2 \pm 0.08\%$  of glomeruli on day 8.

In order to examine histopathological alterations at the ultrastructural level we carried out an additional experiment in which kidneys were fixed by perfusion. Since extracapillary lesions were not frequent on day 8 we chose day 14 for this experiment. On day 14 most capillary loops were morphologically altered. Focal fusion of foot processes and focal detachment of the capillary endothelium from the GBM represented the most benign alterations. In severely damaged loops the capillary lumen was narrowed. The GBM was attenuated. Hyaline material and, less frequently, fibrin accumulated in the subendothelial space. The cells in that space displayed mostly morphological features of mesangial cells or of neutrophil granulocytes. Many podocytes exhibited protrusions of their apical cytoplasm (Figure 4). Capillary necrosis was sometimes observed. Cellular crescents were found in  $23.3 \pm 6.4\%$  of glomeruli. They were histologically (Figure 3) and

ultrastructurally (Figure 4) similar to those in the standard model of anti-GBM glomerulonephritis [8]. The cells of crescents were not connected by junctions. The intercellular space was often broad and it contained cell debris and basement membrane-like material. The tuft and Bowman's capsule were frequently connected by podocyte bridges. Morphologically the bridging cells were identified as podocytes (Figure 4). Heavily damaged glomeruli were surrounded by cellular infiltrates. A vast majority of tubules appeared histologically unaltered but a few degenerating tubules were found. The latter were surrounded by infiltrates containing mononuclear cells and neutrophil granulocytes (not shown).

#### Discussion

The present paper describes the histopathology in a model of glomerulonephritis in which inflammation is driven by humoral mediators. The aim was a comparison with the known histopathological features in DTH-mediated glomerulonephritis. Rapidly progressive glomerulonephritis can be induced in rodents by injection of an anti-GBM serum a few days after immunization with IgGs of the donor species. Since effectors of humoral immune response and of cellular immune response are found in the inflamed glomeruli of experimental animals, both responses may contribute to the disease. The balance between the humoral and the cellular types of immune response is under strong genetic control. C57BL/6 mice display a bias towards Th1 responses [10]. Th1 helper cells produce interferon-gamma and promote cellular immunity [15]. Accordingly, with the usual protocol for induction of anti-GBM glomerulonephritis, glomerular inflammation shows features of DTH in C57BL/6 mice [10,11,14,16]. Thus, infiltration of glomeruli by CD4 T cells and macrophages is prominent. Autologous antibodies and complement, although they are detectable in the glomeruli, do not play a measurable role in pathogenesis [11,16]. In contrast to C57BL/6 mice, the BALB/c strain displays a bias towards Th2 responses. Accordingly, the usual protocol for induction of anti-GBM glomerulonephritis produces in BALB/c mice a disease, which relies essentially on a humoral immune



**Fig. 4.** Ultrastructural alterations on day 14. (A) Glomerular tuft. The lumens of capillaries (c) are narrowed. The subendothelial spaces contain hyaline material (H) and cells (asterisks). The GBM is attenuated (arrowheads). A podocyte (po) displays flattening of foot processes, abundant inclusions of various electron densities and microprojections along the luminal aspect. (B) A podocyte (po) bridges the space between the GBM (arrowheads) and the parietal basement membrane (arrow). It does not form cellular contacts with a neighbouring parietal epithelial cell (pec). (C) A crescent is composed of cells and of basement membrane-like material. The parietal basement membrane (arrows) is preserved. In A, B and C us, urinary space. Bar, 5  $\mu$ m.

response [12]. In the present study, in order to lessen a potential contribution of DTH to glomerular inflammation we immunized BALB/c mice with IFA instead of CFA. Immunization with IFA induces a strongly

polarized Th2 response [17]. It not only fails to elicit the development of Th1 helper cells [18,19], which are required for adaptive cellular immune responses, but it also induces an antigen-specific tolerance against Th1 responses [20]. In agreement with this theoretical background, in the present study BALB/c mice did not display a measurable cutaneous DTH response to rabbit IgG after immunization with IFA.

In order to evaluate the DTH response in glomeruli we counted T helper cells (CD4+) and macrophages (MHC II+). DTH reactions are characterized by their well-defined time course. The sensitization phase, which corresponds to the development of antigen-specific T helper cells, takes a few days after immunization. In the present study anti-GBM serum was injected 6 days after immunization against rabbit IgG. The specific effector phase, involving infiltration with T helper cells and macrophages, peaks between 1 and 3 days after antigen challenge and declines slowly thereafter. In the present study on days 4 and 8 after injection of anti-GBM serum there was no measurable infiltration with CD4 cells and there was little influx of macrophages in glomeruli. This contrasts with the large influx of these two cell populations in the standard model, in which C57BL/6 mice are immunized with CFA [10,16]. This is the first report of a model of anti-GBM glomerulonephritis in which there is no measurable infiltration with CD4 T cells. Humoral mediators of inflammation, autologous IgG and C3, were detected. Thus, the modified protocol yields a model for studying humorally mediated glomerulonephritis in the absence of a measurable DTH-like inflammatory response.

Surprisingly, all lesions observed in humorally mediated anti-GBM glomerulonephritis in the present study have been described previously in DTH-mediated anti-GBM glomerulonephritis in C57BL/6 mice immunized with CFA, and conversely. It has been proposed that a high incidence of cellular crescents might be an attribute of glomerulonephritis driven by DTH [10]. Although crescents developed more slowly in the present study than in various studies with C57BL/6 mice, 23.3% of glomeruli displayed crescents at day 14. The formation of cellular crescents following mesangiolysis in rats [21] also suggests that crescentic glomerulonephritis does not necessarily represent a DTH-type inflammation. Thus, crescents do not appear to be a safe criterion in order to discriminate between different types of inflammatory processes. This conclusion is in keeping with the large diversity of conditions that are associated with glomerular crescents in human pathology [1].

In animal models of glomerulonephritis quantitative differences have been found previously when comparing models in which the cellular immune response predominates and models in which the humoral immune response predominates. Whereas they contributed to the understanding of the pathophysiology of glomerulonephritis those observations are probably not very useful with respect to diagnostics in human pathology. Indeed, qualitative criteria are much more

robust than quantitative criteria in histological diagnostics. In the present study we did not detect any specific histological feature, which might allow us discriminate between the two types of immune responses. This suggests that the glomerulus has only a very limited repertoire of structural adaptation to inflammatory insults. Similarly a variety of pathophysiological processes converge to the same pattern of histological lesions in focal segmental glomerulosclerosis [22].

*Acknowledgements.* I would like to thank Michele Enderlin and Lea Kläusli for excellent technical assistance.

*Conflict of interest statement.* None declared.

## References

- Jennette JC, Thomas DB. Crescentic glomerulonephritis. *Nephrol Dial Transplant* 2001; 16: 80–82
- Kluth DC, Rees AJ. Anti-glomerular basement membrane disease. *J Am Soc Nephrol* 1999; 10: 2446–2453
- Kalluri R. Goodpasture syndrome. *Kidney Int* 1999; 55: 1120–1122
- Lerner RA, Glasscock RJ, Dixon FJ. The role of anti-glomerular basement membrane antibody in the pathogenesis of human glomerulonephritis. *J Exp Med* 1967; 126: 989–1004
- Meyers KE, Allen J, Gehret J *et al.* Human antiglomerular basement membrane autoantibody disease in XenoMouse II. *Kidney Int* 2002; 61: 1666–1673
- Nolasco FE, Cameron JS, Hartley B, Coelho A, Hildreth G, Reuben R. Intraglomerular T cells and monocytes in nephritis: study with monoclonal antibodies. *Kidney Int* 1987; 31: 1160–1166
- Wu J, Hicks J, Ou C, Singleton D, Borillo J, Lou YH. Glomerulonephritis induced by recombinant collagen IV alpha 3 chain noncollagen domain 1 is not associated with glomerular basement membrane antibody: a potential T cell-mediated mechanism. *J Immunol* 2001; 167: 2388–2395
- Le Hir M, Keller C, Eschmann V, Hahnel B, Hosser H, Kriz W. Podocyte bridges between the tuft and Bowman's capsule: an early event in experimental crescentic glomerulonephritis. *J Am Soc Nephrol* 2001; 12: 2060–2071
- Ophascharoensuk V, Pippin JW, Gordon KL, Shankland SJ, Couser WG, Johnson RJ. Role of intrinsic renal cells versus infiltrating cells in glomerular crescent formation. *Kidney Int* 1998; 54: 416–425
- Huang XR, Tipping PG, Shuo L, Holdsworth SR. Th1 responsiveness to nephritogenic antigens determines susceptibility to crescentic glomerulonephritis in mice. *Kidney Int* 1997; 51: 94–103
- Kitching AR, Holdsworth SR, Tipping PG. Crescentic glomerulonephritis—a manifestation of a nephritogenic Th1 response? *Histol Histopathol* 2000; 15: 993–1003
- Huang XR, Holdsworth SR, Tipping PG. Th2 responses induce humorally mediated injury in experimental anti-glomerular basement membrane glomerulonephritis. *J Am Soc Nephrol* 1997; 8: 1101–1108
- Le Hir M, Haas C, Marino M, Ryffel B. Prevention of crescentic glomerulonephritis induced by anti-glomerular basement membrane antibody in tumor necrosis factor-deficient mice. *Lab Invest* 1998; 78: 1625–1631
- Le Hir M, Ryffel B, Schatzmann U. IL-12-dependent, INF-gamma-independent experimental glomerulonephritis. *Kidney Blood Press Res* 2001; 24: 27–32
- Gately MK, Renzetti LM, Magram J *et al.* The interleukin-12/interleukin-12-receptor system: role in normal and pathologic immune responses. *Annu Rev Immunol* 1998; 16: 495–521
- Schatzmann U, Haas C, Le Hir M. A Th1 response is essential for induction of crescentic glomerulonephritis in mice. *Kidney Blood Press Res* 1999; 22: 135–139
- Yip HC, Karulin AY, Tary-Lehmann M *et al.* Adjuvant-guided type-1 and type-2 immunity: infectious/noninfectious dichotomy defines the class of response. *J Immunol* 1999; 162: 3942–3949
- Forsthuber T, Yip HC, Lehmann PV. Induction of TH1 and TH2 immunity in neonatal mice. *Science* 1996; 271: 1728–1730
- Chu RS, Targoni OS, Krieg AM, Lehmann PV, Harding CV. CpG oligodeoxynucleotides act as adjuvants that switch on T helper 1 (Th1) immunity. *J Exp Med* 1997; 186: 1623–1631
- Heeger PS, Forsthuber T, Shive C *et al.* Revisiting tolerance induced by autoantigen in incomplete Freund's adjuvant. *J Immunol* 2000; 164: 5771–5781
- Kriz W, Hahnel B, Hosser H *et al.* Pathways to recovery and loss of nephrons in anti-thy-1 nephritis. *J Am Soc Nephrol* 2003; 14: 1904–1926
- Kriz W, Lemley KV. The role of the podocyte in glomerulosclerosis. *Curr Opin Nephrol Hypertens* 1999; 8: 489–497

*Received for publication: 10.9.03*

*Accepted in revised form: 24.3.04*