

CARDIOVASCULAR FLASHLIGHT

doi:10.1093/eurheartj/ehr078

Online publish-ahead-of-print 29 March 2011

Impressive left ventricular pseudoaneurysm mimicking a pericardial tamponade 5 years after mitral valve replacement for endocarditis

Maximilian Y. Emmert^{1*}, Markus J. Wilhelm¹, Thomas Frauenfelder², Benedikt Weber¹, Simon P. Hoerstrup¹, and Volkmar Falk¹

¹Clinic for Cardiovascular Surgery, University Hospital Zurich, Raemi Street 100, 8091 Zurich, Switzerland and ²Department for Diagnostic Radiology, University Hospital Zurich, Zurich, Switzerland

* Corresponding author. Tel: +41 442553298, Fax: +41 442554446, Email: maximilian.emmert@usz.ch

This paper was guest edited by Prof. Frank E. Rademakers, University Hospital Gasthuisberg, Leuven, Belgium

A 66-year-old female patient with a history of mechanical mitral valve replacement (MVR) due to endocarditis 5 years ago was referred with shortness of breath, tachycardia, and beginning hypotension. In addition, the patient appeared to have prominent jugular veins suggesting a pericardial tamponade. Transthoracic echocardiography (TTE) displayed a partly calcified pericardial effusion (13 × 8 cm) compressing the right ventricle (RV) and the right atrium (RA) (Panel A), and computed tomography revealed a giant left ventricular pseudoaneurysm (LVPA) (10 × 10 cm) originating from the posterior mitral valve annulus (Panel B, white arrow). The impressive LVPA compressing the RV, the RA, and the inferior vena cava (Panels C and D; see Supplementary Video 1) was perfused through a tunnel-like structure (Panel E, black arrow; see Supplementary Video 2) that communicated with the left ventricular posterolateral wall below the prosthetic mitral valve. The LVPA was partially resected and a 4 × 4 cm atrioventricular dehiscence became apparent (Panel F, black arrow) which was repaired from the inside of the left atrium using a 4 × 4 cm patch, before re-replacement of the mechanical valve (MVR) was performed. The procedure was uneventful and the patient made a swift recovery. Here, we present a very impressive image and motion series of a giant LVPA originating from below the mitral annulus 5 years after mechanical MVR. Left ventricular pseudoaneurysm is a rare condition that is difficult to diagnose (Miura *et al.*, *Ann Thorac Surg* 2008;**85**:643–645). Although myocardial infarction is the most common reason for LVPA (Amasyali *et al.*, *Int J Cardiol* 2007;**119**:e51–e5), one-third result from surgical procedures, most often after MVR (Frances *et al.*, *J Am Coll Cardiol* 1998;**32**:557–561). Therefore, regular follow-up including TTE is mandatory after MVR.

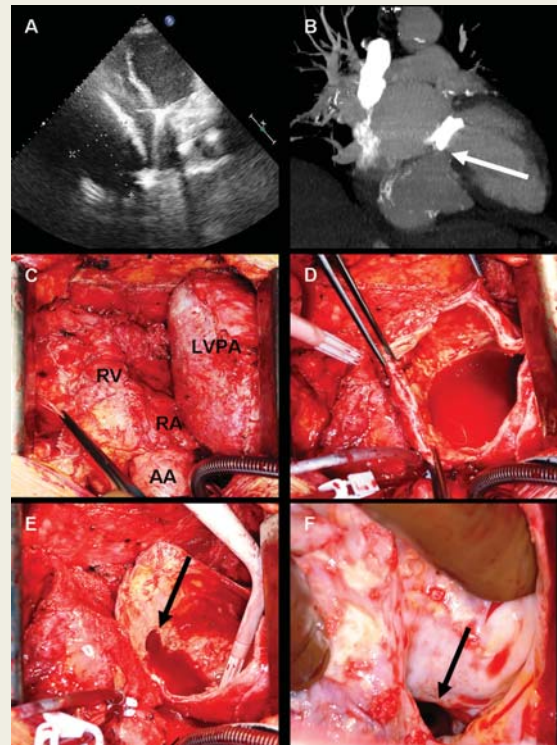


Figure. RV, right ventricle; RA, right atrium; AA, ascending aorta; LVPA, left ventricular pseudoaneurysm.

Supplementary material

Supplementary material is available at *European Heart Journal* online.