

Evaluation of tooth position, occlusion, and interproximal contacts after transplantation of immature third molars

Oskar Bauss* and Stavros Kiliaridis**

*Private Practice, and Hannover Medical School, Germany and **Department of Orthodontics, University Dental School of Geneva, Switzerland

SUMMARY The aim of the present investigation was to examine position, occlusion, and interproximal contacts of 139 transplanted third molars in 136 patients (94 females, 42 males) with a mean age of 17.6 years at the time of transplantation.

Ninety-two teeth were placed directly into favourable positions and left to erupt spontaneously. Forty-seven teeth were transplanted into atrophied jaw sections and underwent post-operative orthodontic adjustment. According to the post-operative treatment performed, the sample was divided into two groups: transplants with or without subsequent orthodontic treatment. The mean post-operative observation time was 4.4 years. Study models were obtained from all patients and the American Board of Orthodontics Objective Grading System was adapted for evaluation of position, occlusion, and interproximal contacts of the transplanted teeth. A Mann–Whitney *U*-test was used to determine significant intergroup differences with respect to the final scores and the various evaluated criteria.

Absence of occlusal contacts was found in more than 30 per cent, absence of both interproximal contacts in more than 15 per cent, and inadequate position in more than 40 per cent of the transplants without subsequent orthodontic treatment. The poorest results were observed for maxillary teeth transplanted into the mandible.

The results of the present study show that incorrect positioning with absence of occlusal and interproximal contacts are frequent findings in transplanted teeth. Short-term orthodontic adjustment, especially of maxillary transplants into the mandible, seems to be advisable in order to obtain correct positioning and function of these teeth.

Introduction

Transplantation of teeth is usually performed into fresh extraction sites, immediately after removal of the non-retainable tooth. The transplant is placed into a favourable buccolingual position and is fixed in infraocclusion. Afterwards, the transplanted tooth is expected to erupt into the occlusal plane and to obtain an adequate position. The vast majority of investigations on tooth transplantation have been concerned with the post-operative periodontal and pulpal healing of transplants (Andreasen, 1992). Although an adequate transplant position with the presence of occlusal and interproximal contacts is mandatory for the physiological function of transplanted teeth, only scant attention has been paid to this issue (Nordenram, 1963; Galanter and Minami, 1968). One aim of the present study was thus to examine the position, occlusion, and interproximal contacts in a large sample of transplanted third molars.

One important prerequisite for the success of transplantation is a suitable donor tooth. There is usually a high level of congruence concerning crown and root morphology, if a third molar replaces a tooth in the same quadrant (Andreasen, 1992). However, in many instances, the treatment plan involves transplantation into the opposite side of the same jaw, or even into the opposite jaw, implying marked differences between the transplant and the opposing teeth with respect to the size and morphology of the crowns. A

further objective of this study was therefore to evaluate whether orthodontic adjustment of transplanted teeth can provide a correct tooth position with adequate occlusion and sufficient interproximal contacts, even in those cases with distinct discrepancies in crown size and crown morphology.

Subjects and methods

The study sample consisted of 139 teeth transplanted in 136 patients (94 females, 42 males). Three of the patients had undergone two transplantations each. The mean age at the time of transplantation was 17.6 years (range 16.1–20.3 years). The mean post-operative observation time was 4.4 years (range 1.8–8.3 years; Table 1). According to the classification by Moorrees *et al.* (1963), all transplants were at root development stages 3–4 (one half to three-quarter root development). In 47 cases, maxillary third molars had been transplanted within the maxilla, and in 34 cases into the mandible. In 58 cases, a transplantation of mandibular third molars had been conducted within the mandible (Table 2). All operations were performed by one surgeon (OB) using a standardized surgical technique under antibiotic coverage for 7 days. Depending on the bone height in the recipient region, transplants were fixed in 1–6.5 mm of infraocclusion for 7 days with a suture splint crossing the occlusal surface. The extent of infraocclusion was determined to the nearest 0.5 mm immediately after transplantation and at the final follow-up,

Table 1 Transplant and gender distribution, average age at transplantation, and mean observation period (decimal years).

Examination group	Transplanted teeth	Gender		Average age (range)	Observation period (range)
		Male	Female		
No orthodontic treatment	92	28	62	17.8 (16.1–20.3)	4.5 (2.1–8.3)
Orthodontic treatment	47	14	32	17.2 (16.3–19.2)	4.2 (1.8–7.5)
Total	139	42	94	17.6 (16.1–20.3)	4.4 (1.8–8.3)

Table 2 Number and distribution of transplants according to stage of root development and direction of transplantation.

Examination group	Stage of root development		Direction of transplantation		
	Stage 3 (1/2)	Stage 4 (3/4)	MX to MX*	MX to MD†	MD to MD‡
No orthodontic treatment	33	59	33	23	36
Orthodontic treatment	20	27	14	11	22
Total	53	86	47	34	58

*Maxillary third molar to maxilla. †Maxillary third molar to mandible. ‡Mandibular third molar to mandible.

using the approximal marginal ridges of the transplant and the respective neighbouring molar as reference points. Only transplants with pulpal vitality (positive sensitivity testing or pulp obliteration with no signs of inflammatory root resorption or periapical radiolucencies) and regular periodontal condition (pocket probing depths of less than 3 mm and absence of ankylosis or inflammatory root resorption) at the final follow-up were included in the investigation. Thus, 26 transplants had to be excluded from the original sample. According to the post-operative treatment performed, the sample was divided into two groups: transplants with or without subsequent orthodontic treatment.

Transplanted teeth without subsequent orthodontic treatment

Ninety-two teeth were transplanted in patients with only minor malocclusions or malalignment of teeth and without orthodontic treatment need. Inclusion criteria for this group were occlusal contacts, correct buccolingual position, no apparent rotation, and no buccal or lingual tipping of either neighbouring teeth or the contralateral tooth. Transplants in this group replaced non-retainable maxillary ($n = 33$) or mandibular ($n = 59$) first molars. All teeth were placed directly into favourable positions after removal of the non-retainable tooth and were left to erupt spontaneously. Post-operative infraocclusion of these transplants averaged 1.5 mm (range 1.0–3.0 mm).

Transplanted teeth with subsequent orthodontic treatment

All 47 transplantations in this group were undertaken in patients who were already undergoing orthodontic treatment with fixed appliances. The teeth were transplanted into atrophied jaw sections due to early molar loss ($n = 19$) or

aplasia of premolars ($n = 28$) with subsequent atrophy of the alveolar process. Therefore, the transplants had to be placed in distinct infraocclusion or in a distally rotated position during surgery to permit transplant adjustment to the recipient site and to facilitate transplant fixation. Orthodontic treatment of the transplants was initiated no earlier than 3 months and no later than 6 months after transplantation and included extrusion and derotation of the transplants. Orthodontic therapy was carried out with a preadjusted appliance with 0.018 inch slot brackets (Unitek/3M, Monrovia, California, USA). The archwire sequence was usually 0.012, 0.016, and 0.016×0.022 nickel–titanium, followed by 0.016×0.022 stainless steel. The mean orthodontic treatment time of the transplants was 14.8 months (range 6.0–23.9 months). Post-operative infraocclusion in this group averaged 3.8 mm (range 1.0–6.5 mm).

Evaluation of transplant position, occlusion, and interproximal contacts

Alginate impressions were obtained from all patients during the final follow-ups for production of study models. After trimming the models, the American Board of Orthodontics Objective Grading System (Casko *et al.*, 1998) for scoring dental casts was adapted for the evaluation of the transplant position (alignment, marginal ridges, and buccolingual inclination), occlusion (occlusal contacts and lateral overjet), and interproximal contacts. Depending on the discrepancies from ideal position, up to two points were subtracted in each category from the maximum score of 12 points. All evaluations were carried out by one examiner (OB).

1. Alignment (buccolingual position): in the maxillary arch, the central grooves should all be in mesiodistal

alignment, and in the mandibular arch, the mesiobuccal and distobuccal cusps of the transplants and the neighbouring teeth should be in mesiodistal alignment. If the mesial or distal alignment at any of the contact points deviated up to 1 mm from ideal alignment, one point was subtracted. If the discrepancy was greater than 1 mm, two points were subtracted (Figure 1a).

2. Marginal ridges (vertical position): the marginal ridge was defined as the most occlusal point that is within 1 mm of the contact at the occlusal surface of the adjacent teeth. In both maxillary and mandibular arches, the marginal ridges of the transplant and the adjacent teeth should be at the same level. If adjacent marginal ridges deviated up to 1 mm for one of the interproximal contacts, one point was subtracted. If the marginal ridge discrepancy was greater than 1 mm, two points were subtracted. Irrespective of the number of involved

marginal ridges, no more than two points were subtracted from the final score (Figure 1b).

3. Buccolingual inclination (angulation): the buccolingual inclination of the transplants was assessed using a flat surface that extended between the occlusal surfaces of the transplant and the contralateral tooth. When positioned in this manner, the straight edge should contact the buccal cusps of the transplant and the contralateral tooth in the mandible and the lingual cusps of the transplant and the contralateral tooth in the maxilla. The lingual cusps in the mandible and the buccal cusps in the maxilla should be within 1 mm of the surface of the straight edge. If the discrepancy was more than 1 mm but less than 2 mm, one point was subtracted. If the discrepancy was more than 2 mm, two points were subtracted. In the case of a buccally tipped transplant in the mandible or a palatally tipped

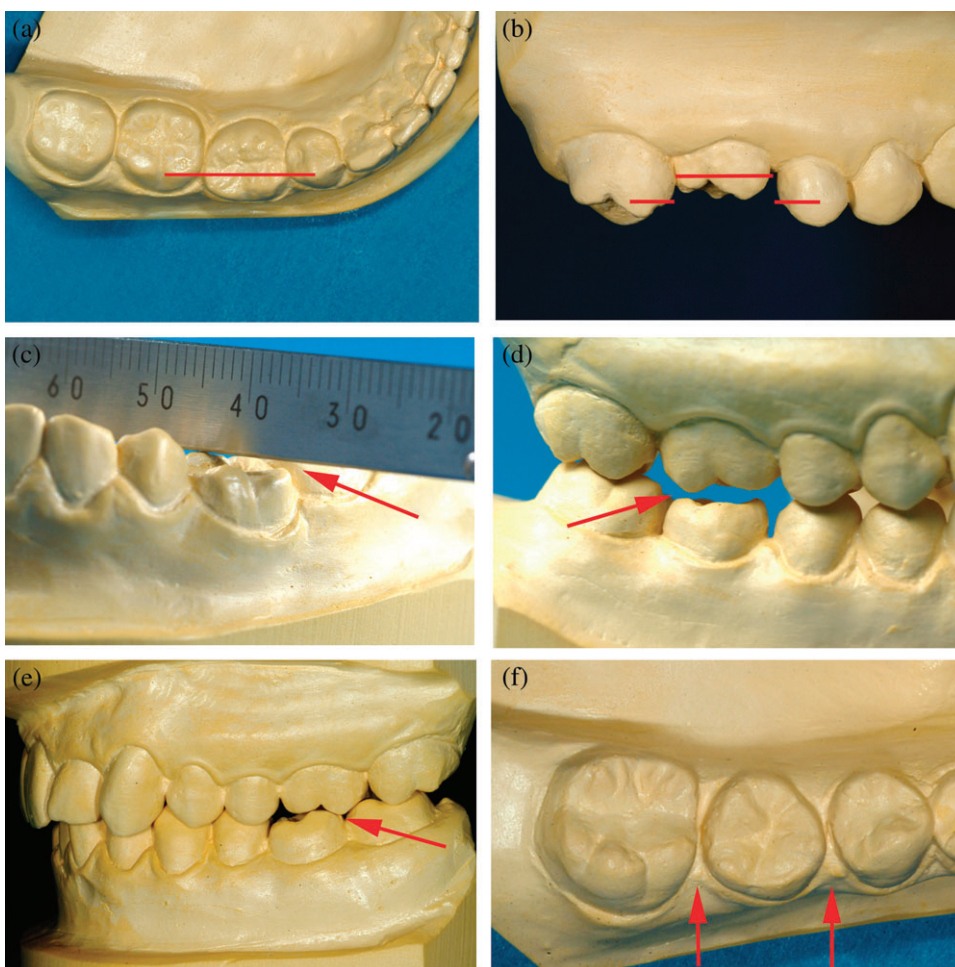


Figure 1 Inadequate alignment of a transplant in the right mandible with a discrepancy between the mesiobuccal and distobuccal cusps of the transplant and the cusps of the adjacent teeth of more than 1 mm (a). Inadequate vertical position of a transplant in the right maxilla with a marginal ridge discrepancy of more 1 mm (b). Inadequate buccolingual inclination of a transplant in the left mandible with contact of the straight edge to the lingual cusp only (c). Absence of occlusal contacts in a transplant in the right mandible (d). Inadequate lateral overjet with an edge-to-edge bite between a transplant in the left mandible and the opposing tooth (e) and absence of interproximal contacts in a transplant in the right mandible (f).

transplant in the maxilla with contact of the straight edge to the lingual (mandible) or buccal (maxilla) cusp only, two points were subtracted (Figure 1c).

4. Occlusal contacts: the buccal cusps of the transplants in the mandible and the lingual cusps of transplants in the maxilla should contact the occlusal surfaces of the opposing teeth. If the cusps of the transplant were out of contact with the opposing teeth and the distance was 1 mm or less, then one point was subtracted. If the cusps were out of contact and the distance was greater than 1 mm, then two points were subtracted (Figure 1d).
5. Lateral overjet: evaluation was performed by articulating the models and viewing the labiolingual relationship of the maxillary arch relative to the mandibular arch. The buccal cusps of the mandibular molars should contact in the centre of the occlusal surfaces, buccolingually of the maxillary molars. In the case of an edge-to-edge bite, one point was subtracted and in the case of a crossbite, two points were subtracted (Figure 1e).
6. Interproximal contacts: this assessment was made by viewing the maxillary and mandibular dental casts from an occlusal perspective. The mesial and distal surfaces of the transplant and the adjacent teeth should be in contact with one another. If an interproximal space existed between the transplant and one of the adjacent teeth, then one point was subtracted. If there were interproximal spaces between the transplant and both neighbouring teeth, then two points were subtracted (Figure 1f).

Statistical analysis

A Mann–Whitney *U*-test was carried out to determine significant intergroup differences with respect to the final scores and to the six evaluated criteria (alignment, marginal ridges, buccolingual inclination, occlusal contacts, lateral overjet, and interproximal contacts). A further analysis was performed to determine the influence of additional parameters. These examined parameters were donor tooth (maxillary or mandibular third molar) and direction of transplantation (maxillary molar within the maxilla, maxillary molar into the mandible, and mandibular molar within the mandible). The level of statistical significance was set at $\alpha = 0.05$. Statistical analysis was performed using the Statistical Package for Social Sciences version 15.0 (SPSS Inc., Chicago, Illinois, USA).

Error of the method

The reliability of the assessment of the six criteria was evaluated by double measurements of all casts within a 4 week interval. A Wilcoxon rank sum test was performed to detect any systematic error between the two scoring sessions. Spearman rank order correlation was calculated to assess the degree of correlation between the two ratings. No systematic error between the two registrations and a highly significant correlation was determined for all criteria

(Table 3). The mean difference between the double ratings was 0.42 points (range 0–2 points). All discrepancies between the double measurements were corrected through repeated measurements (Yang-Powers *et al.*, 2002).

Results

Transplanted teeth without subsequent orthodontic treatment

Transplants in this group showed correct alignment in 9.8 per cent of the cases ($n = 9$). A correct position of the marginal ridges was determined in 65.2 per cent ($n = 60$), and a correct buccolingual inclination was observed for 30.4 per cent of the teeth ($n = 28$). At least one occlusal contact was registered in 71.7 per cent ($n = 66$), and a correct lateral overjet was observed in 84.8 per cent of the transplants in this group ($n = 78$). Both interproximal contacts were present for 52.2 per cent of the teeth ($n = 48$; Figure 2). Transplants in this group achieved a mean final score of 7.86 [range 0–12; standard deviation (SD) = 2.43]. The highest mean score (1.82) was found for lateral overjet (range 0–2; SD = 0.47) and the lowest (0.66) for alignment of the transplants (range 0–2; SD = 0.65). The mean scores for the remaining criteria were 1.53 for marginal ridges (range 0–2; SD = 0.70), 0.89 for buccolingual inclination (range 0–2; SD = 0.85), 1.60 for occlusal contacts (range 0–2; SD = 0.70), and 1.37 for interproximal contacts (range 0–2; SD = 0.74).

Transplanted teeth with subsequent orthodontic treatment

For transplants with subsequent orthodontic treatment, correct alignment was found for 72.3 per cent of the teeth ($n = 34$). A correct position of the marginal ridges was observed in 89.4 per cent ($n = 42$), and a correct buccolingual inclination in 83.0 per cent of the transplants ($n = 39$). At least one occlusal contact was present for all the transplants in this group ($n = 47$). Correct lateral overjet was seen in 97.9 per cent ($n = 46$), and both interproximal contacts were present in 95.7 per cent of the transplants ($n = 45$). The mean final score in this group was 11.32 (range 8–12; SD = 0.89). The highest mean score was for occlusal contacts (2.0) and the

Table 3 Reliability for the assessment of transplant position on dental casts based on double evaluations within a 4 week interval.

Rated criteria	Wilcoxon ranked sum test	Spearman ranked order correlation	
		<i>r</i>	<i>P</i>
Alignment	<i>P</i> = 0.09	0.76	<i>P</i> < 0.001
Marginal ridges	<i>P</i> = 0.07	0.77	<i>P</i> < 0.001
Buccolingual inclination	<i>P</i> = 0.11	0.86	<i>P</i> < 0.001
Occlusal contacts	<i>P</i> = 0.22	0.94	<i>P</i> < 0.001
Lateral overjet	<i>P</i> = 0.35	0.93	<i>P</i> < 0.001
Interproximal contacts	<i>P</i> = 0.41	0.89	<i>P</i> < 0.001

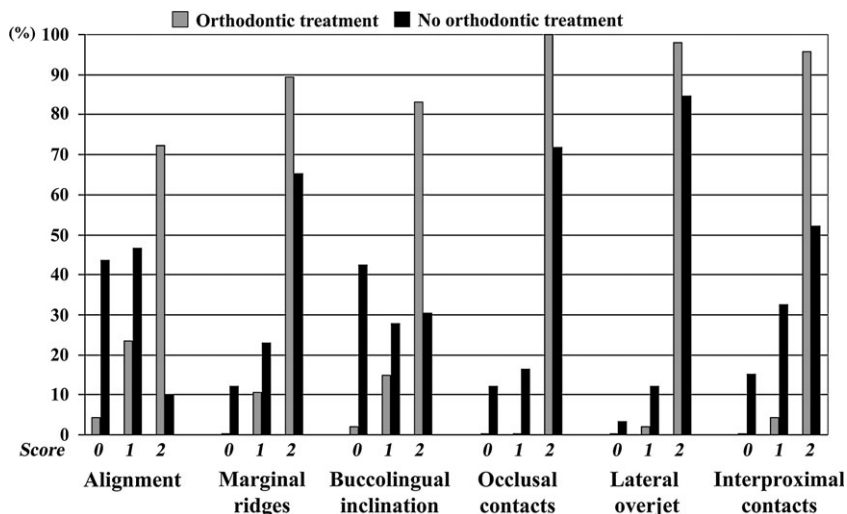


Figure 2 Frequency distribution of the various scores for the examined criteria in transplants with or without orthodontic treatment.

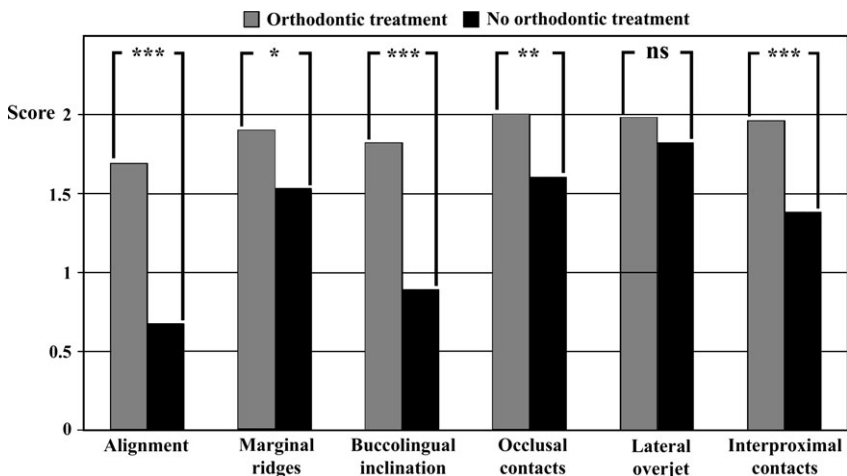


Figure 3 Intergroup differences in the mean scores for the examined criteria in transplants with or without orthodontic treatment. *** $P < 0.001$; ** $P < 0.01$; * $P < 0.05$; ns, not significant.

lowest (1.68) for alignment of the transplants (range 0–2; SD = 0.56). The mean scores for the remaining criteria were 1.89 for marginal ridges (range 1–2; SD = 0.31), 1.81 for buccolingual inclination (range 0–2; SD = 0.45), 1.99 for lateral overjet (range 1–2; SD = 0.15), and 1.96 for interproximal contacts (range 1–2; SD = 0.20).

Transplants without subsequent orthodontic treatment showed a significantly lower mean final score than those with subsequent orthodontic treatment ($P < 0.001$). With respect to the various criteria examined, significant intergroup differences were determined for alignment ($P < 0.001$), marginal ridges ($P = 0.014$), buccolingual inclination ($P < 0.001$), occlusal contacts ($P = 0.006$), and interproximal contacts ($P < 0.001$). No significant difference was observed for lateral overjet (Figure 3).

Significant influences of the donor tooth and the direction of transplantation were noted for the transplants without subsequent orthodontic treatment. Maxillary molars demonstrated a significantly lower final score (7.23; range 0–11; SD = 2.73) than mandibular molars (8.83; range 4–12; SD = 1.73; $P = 0.004$). Concerning the various criteria rated, significant differences were observed for buccolingual inclination ($P = 0.014$) and interproximal contacts ($P = 0.011$). Correct buccolingual inclination was found for 23.2 per cent ($n = 13$) of the maxillary and 41.7 per cent of the mandibular ($n = 15$) transplants; both interproximal contacts were present for 41.1 per cent ($n = 23$) of the maxillary and 69.4 per cent ($n = 25$) of the mandibular transplants (Figure 4).

With respect to the direction of transplantation, maxillary molars that had been transplanted into the mandible showed a

significantly lower final score (5.87; range 0–10; SD = 3.15) than maxillary molars within the maxilla (8.18; range 3–11; SD = 1.93; $P=0.004$) or mandibular molars within the mandible (8.83; range 4–12; SD = 1.73; $P<0.001$). Maxillary transplants into the mandible showed significantly lower scores for buccolingual inclination ($P<0.001$) and interproximal contacts ($P=0.002$) than maxillary transplants within the maxilla, or mandibular transplants within the mandible ($P<0.001$, respectively). Maxillary transplants into the mandible had a correct buccolingual inclination in 4.3 per cent of the cases ($n=1$), and both interproximal contacts were determined for 17.4 per cent ($n=4$) of the teeth. No significant differences were observed between maxillary transplants within the maxilla or mandibular transplants within the mandible (Figure 5).

Discussion

Transplanted teeth with subsequent orthodontic treatment

Previous studies have shown that orthodontic adjustment can be performed without additional risk to the pulpal and periodontal condition of transplanted teeth (Paulsen *et al.*, 1995; Bauss *et al.*, 2004a,b). However, no previous investigation has examined tooth position, occlusion, and interproximal contacts after orthodontic adjustment of transplanted teeth. The findings of the present research indicate that orthodontic therapy is capable of providing excellent results concerning occlusion and interproximal contacts of transplanted teeth, even for maxillary molars transplanted into the mandible, or transplants positioned in extremely infraoccluded or rotated positions. Lower scores were obtained for tooth position. In a previous study on the treatment outcome of orthodontic therapy (Yang-Powers *et al.*, 2002), alignment and buccolingual inclination were also found to be the two most deficient criteria. In the present sample, correct alignment, vertical position of

marginal ridges, and buccolingual inclination were observed to be problematic in patients with premolar aplasia. Since in these subjects a third molar was used to replace a second premolar, correct tooth position was complicated by the differences in crown dimension.

Transplanted teeth without subsequent orthodontic treatment

In contrast to dental implants, transplantation of teeth is suitable for individuals who are still growing (Ödman *et al.*, 1991; Oesterle *et al.*, 1993; Thilander *et al.*, 1994). However, the purpose of dental implants and tooth transplants is to replace a missing tooth by an adequate substitute. Thus, even if transplanted teeth show survival rates comparable with those of dental implants (Eckert and Wollan, 1998; Lekholm *et al.*, 1999), the advantages of tooth transplantation can be questionable, if a transplanted tooth is not capable of fulfilling the two crucial requirements: regular function and adequate position.

As occlusal contacts are necessary for the regular function of transplants, the presence of occlusal contacts is a basic prerequisite if tooth transplants are to compete with dental implants. However, occlusal contacts were absent in almost 30 per cent of the transplants in this group. Several studies have demonstrated a high incidence of overeruption of unopposed posterior teeth (Compagnon and Woda, 1991; Craddock and Youngson, 2004). Therefore, it might be assumed that some of these teeth will show further eruption. However, Kiliaridis *et al.* (2000) found in a study of 84 molars for which antagonists had been missing for at least 10 years, that 58 per cent of the teeth revealed only minimal (<2 mm) elongation and 18 per cent showed no overeruption. In addition, a previous study on the duration of eruption of permanent molars demonstrated that after penetration of the gingival surface, most of the teeth reached the occlusal plane within the first 18 months (Ekstrand

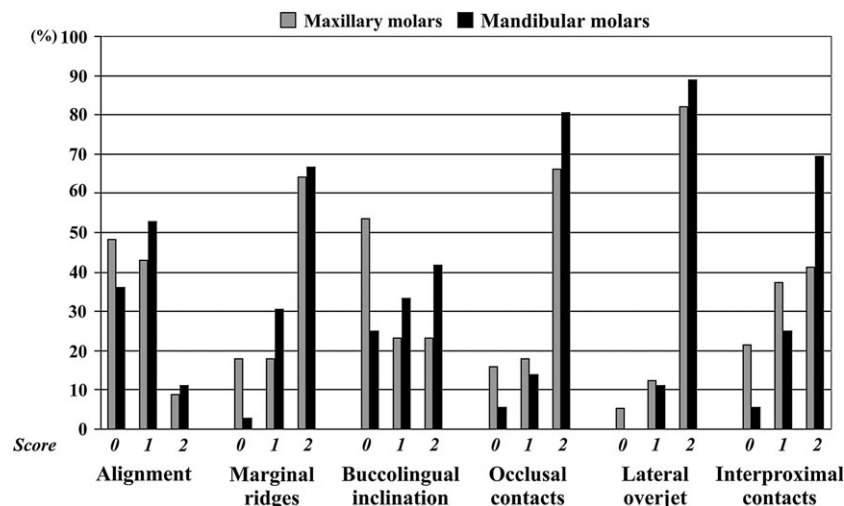


Figure 4 Frequency distribution of the various scores for the examined criteria in maxillary and mandibular transplants without orthodontic treatment.

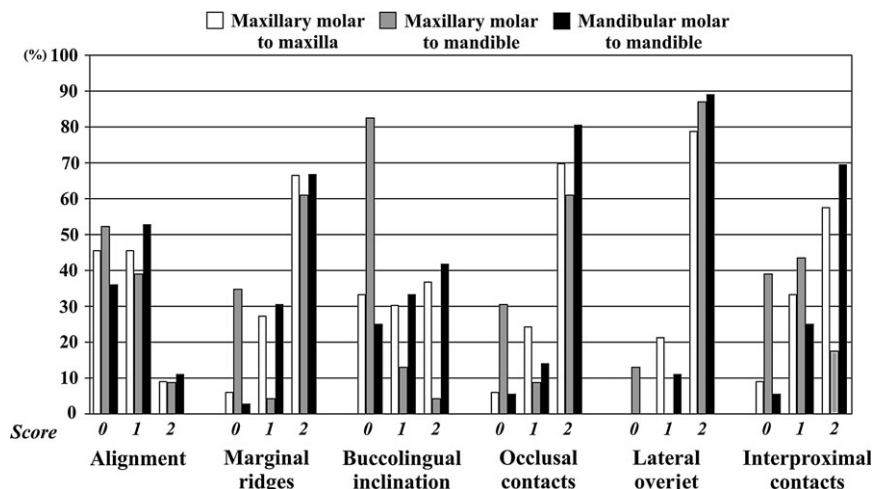


Figure 5 Frequency distribution of the various scores for the examined criteria according to the direction of transplantation in transplants without orthodontic treatment.

et al., 2003). All transplants in the present study were developing teeth with a minimum follow-up period of more than 2 years and were placed in a maximum infraocclusion of 3 mm. Therefore, it is unclear as to why not all these transplants completed the eruption process, and it is questionable whether all infraoccluded transplants will finally reach the occlusal plane. Further investigations are necessary to elucidate this question.

The absence of one interproximal contact was noted for more than 30 per cent of the examined transplants and more than 15 per cent of the teeth showed absence of both interproximal contacts, which is in the range of previous investigations (Nordenram, 1963; Galanter and Minami, 1968). Conclusions differ concerning the relationship between the absence of interproximal contacts and periodontal disease (Geiger *et al.*, 1974). However, several studies found significantly increased pocket probing depths and attachment loss in teeth facing open proximal contacts (Gould and Picton, 1966; Jernberg *et al.*, 1983; Årtun and Osterberg, 1987). It was assumed that open contact areas might promote food impaction and plaque retention, thereby exacerbating local inflammation, eventually resulting in loss of connective tissue attachment and alveolar bone destruction. Thus, it might be concluded that open interproximal contacts have a detrimental effect on the periodontal condition and thus on the long-term prognosis of transplanted teeth. In addition, transplantation of teeth leads to a reduction in final root length (Andreasen *et al.*, 1990; Bauss *et al.*, 2005), and unfavourable crown–root ratios have been reported after transplantation of teeth at early developmental stages (Andreasen, 1992). Galanter and Minami (1968) pointed out that mobility of transplanted teeth might be aggravated by missing interproximal contacts. Therefore, it might also be concluded that closed interproximal contacts are important not only for periodontal health but also for the long-term stability of transplanted teeth.

A major finding of the present investigation was the significant influence of donor tooth and direction of transplantation on the presence of interproximal contacts, with maxillary transplants into the mandible showing the poorest results. This finding could be explained mainly on the basis of tooth size, as all maxillary transplants in this study group were used to replace mandibular first molars. Compared with mandibular first molars, the crowns of maxillary third molars have a reduced mesiodistal width (Orton-Gibbs *et al.*, 2001), so that as a rule, distinct spacing between the maxillary third molar transplant and the adjacent teeth was present after transplantation of maxillary transplants into the mandible.

It is possible that mesial drift of the transplant and the distal tooth could, given sufficient time, result in closure of an initially open interproximal contact (Papandreas *et al.*, 1993). A previous study on orthodontic treatment with extraction of teeth demonstrated a high frequency of incomplete space closure (Oftedal and Wisth, 1982a). Those authors reported that several of the residual extraction spaces closed during or shortly after the period of orthodontic retention. However, for unknown reasons, some open interproximal contacts may remain open and persist even for a number of years after treatment and retention is discontinued (Oftedal and Wisth, 1982b, Wisth and Oftedal, 1982). Therefore, it is questionable in whether all transplants will ever obtain the correct interproximal contacts.

An correct transplant position was observed for more than 40 per cent of the orthodontically untreated transplants. Maxillary transplants into the mandible showed the poorest results, and marked malalignment with extreme buccal or lingual tipping was a frequent finding for these transplants at the final follow-up. A possible explanation might be increased post-operative transplant mobility. During preparation of the recipient site, the intraalveolar septa were removed with bone rongeurs in order to avoid direct contact with the roots of the

transplant. However, most of the maxillary transplants were single-rooted teeth, and the increased distance between roots and recipient site, as well as the absence of interproximal contacts, usually resulted in increased post-operative mobility, complicating correct buccolingual positioning of these transplants. In addition, the occlusal pressure of the suture splint might have aggravated the malposition. Thus, for many maxillary transplants into the mandible, increased buccolingual inclination was already present at the end of the transplantation procedure. Therefore, it might be concluded that an initial transplant malposition often persists and that adequate initial transplant position facilitates obtaining a correct final transplant position. A possible solution could be rigid fixation of transplants with increased post-operative mobility.

Conclusions

The results of the present investigation indicate that an unfavourable position with absence of occlusal and interproximal contacts are frequent findings for transplanted teeth. As previous studies have already demonstrated that orthodontic movement of transplanted teeth is possible without additional risk to the pulpal and periodontal condition, short-term orthodontic adjustment, especially of maxillary transplants into the mandible, seems to be advisable in order to obtain immediate correct positioning and function of these teeth.

Address for correspondence

Dr Oskar Bauss
Luisenstrasse 10/11
30159 Hannover
Germany
E-mail: o.bauss@praxisbauss.de

References

- Andreasen J O 1992 Atlas of replantation and transplantation of teeth. Mediglobe, Fribourg, pp. 111–137
- Andreasen J O, Paulsen H U, Yu Z, Bayer T 1990 A long-term study of 370 autotransplanted premolars. Part IV. Root development subsequent to transplantation. *European Journal of Orthodontics* 12: 38–50
- Årtun J, Osterberg S K 1987 Periodontal status of teeth facing extraction sites long-term after orthodontic treatment. *Journal of Periodontology* 58: 24–29
- Bauss O, Schwestka-Polly R, Kiliaridis S 2004a Influence of orthodontic derotation and extrusion on pulpal and periodontal condition of autotransplanted immature third molars. *American Journal of Orthodontics and Dentofacial Orthopedics* 125: 488–496
- Bauss O, Schwestka-Polly R, Hoy L, Kiliaridis S 2004b Influence of orthodontic movement on root length of autotransplanted immature third molars. *European Journal of Oral Sciences* 112: 12–18
- Bauss O, Schwestka-Polly R, Schilke R, Kiliaridis S 2005 Effect of different splinting methods and fixation periods on root development of autotransplanted immature third molars. *Journal of Oral and Maxillofacial Surgery* 63: 304–310
- Casko J S *et al.* 1998 Objective grading system for dental casts and panoramic radiographs. *American Journal of Orthodontics and Dentofacial Orthopedics* 114: 589–599
- Compagnon D, Woda A 1991 Supraeruption of the unopposed maxillary first molar. *Journal of Prosthetic Dentistry* 66: 29–34
- Craddock H L, Youngson C C 2004 A study of the incidence of overeruption and occlusal interferences in unopposed posterior teeth. *British Dental Journal* 196: 341–348
- Eckert S E, Wollan P C 1998 Retrospective review of 1170 endosseous implants placed in partially edentulous jaws. *Journal of Prosthetic Dentistry* 79: 415–421
- Ekstrand K R, Christiansen J, Christiansen M E C 2003 Time and duration of eruption of first and second permanent molars: a longitudinal investigation. *Community Dentistry and Oral Epidemiology* 31: 344–350
- Galanter D R, Minami R T 1968 The periodontal status of autografted teeth. A pilot study of thirty-one cases. *Oral Surgery, Oral Medicine, and Oral Pathology* 26: 145–159
- Geiger A M, Wasserman B H, Turgeon L R 1974 Relationship of occlusion and periodontal disease. Part VIII. Relationship of crowding and spacing to periodontal destruction and gingival inflammation. *Journal of Periodontology* 45: 43–49
- Gould M S E, Picton D C A 1966 The relation between irregularities of the teeth and periodontal disease. A pilot study. *British Dental Journal* 121: 20–23
- Jernberg G R, Bakdash M B, Keenan K M 1983 Relationship between proximal tooth open contacts and periodontal disease. *Journal of Periodontology* 54: 529–533
- Kiliaridis S, Lyka I, Friede H, Carlsson G E, Ahlqwist M 2000 Vertical position, rotation, and tipping of molars without antagonists. *International Journal of Prosthodontics* 13: 480–486
- Lekholm U *et al.* 1999 Survival of the Brånemark implant in partially edentulous jaws: a 10-year prospective multicenter study. *International Journal of Oral and Maxillofacial Implants* 14: 639–645
- Moorrees C F A, Fanning E A, Hunt E E 1963 Age variation of formation stages for ten permanent teeth. *Journal of Dental Research* 42: 1490–1502
- Nordenram Å 1963 Autotransplantation of teeth. A clinical and experimental investigation. *Acta Odontologica Scandinavica* 21 (Supplement 33): 7–76
- Ödman J, Gröndahl K, Lekholm V, Thilander B 1991 The effect of osseointegrated implants on the dento-alveolar development. A clinical and radiographic study in growing pigs. *European Journal of Orthodontics* 13: 279–286
- Oesterle L J, Cronin R J, Ranly D M 1993 Maxillary implants and the growing patient. *International Journal of Oral and Maxillofacial Implants* 8: 377–387
- Oftedal B, Wisth P J 1982a Residual extraction sites after orthodontic treatment. Part I. At debanding. *European Journal of Orthodontics* 4: 11–19
- Oftedal B, Wisth P J 1982b Residual extraction sites after orthodontic treatment. Part III. Changes in the postretention period. *European Journal of Orthodontics* 4: 203–210
- Orton-Gibbs S, Crow V, Orton H S 2001 Eruption of third permanent molars after the extraction of second permanent molars. Part 1: assessment of third molar position and size. *American Journal of Orthodontics and Dentofacial Orthopedics* 119: 226–238
- Papandreas S G, Buschang S G, Alexander R G, Kennedy D B, Koyama I 1993 Physiologic drift of the mandibular dentition following first premolar extractions. *Angle Orthodontist* 63: 127–134
- Paulsen H U, Andreasen J O, Schwartz O 1995 Pulp and periodontal healing, root development and root resorption subsequent to transplantation and orthodontic rotation: a long-term study of autotransplanted premolars. *American Journal of Orthodontics and Dentofacial Orthopedics* 108: 630–640
- Thilander B, Ödman J, Gröndahl K, Friberg B 1994 Osseointegrated implants in adolescents. An alternative in replacing missing teeth? *European Journal of Orthodontics* 16: 84–95
- Wisth P J, Oftedal B 1982 Residual extraction sites after orthodontic treatment. Part II. At the end of retention. *European Journal of Orthodontics* 4: 99–104
- Yang-Powers L C, Sadowsky C, Rosenstein S, BeGole E A 2002 Treatment outcome in a graduate orthodontic clinic using the American Board of Orthodontics grading system. *American Journal of Orthodontics and Dentofacial Orthopedics* 122: 451–455