

Atherosclerotic renovascular disease: beyond the renal artery stenosis

Pascal Meier¹, Jérôme Rossert², Pierre-François Plouin³ and Michel Burnier¹

¹Service of Nephrology and Hypertension, Centre Hospitalier Universitaire Vaudois, 1011 Lausanne, Switzerland, ²Service of Nephrology and Unité INSERM 652, Groupe Hospitalier HEGP/Broussais, Assistance Publique – Hôpitaux de Paris, Paris, France and ³Hypertension Unit, Groupe Hospitalier HEGP/Broussais, Assistance Publique – Hôpitaux de Paris, Paris, France

Keywords: atherosclerosis; renal artery stenosis; ischemia/reperfusion; reactive oxygen species; fibrosis; inflammation

Introduction

Atherosclerotic renovascular disease (ARVD) is a well-recognized cause of arterial hypertension. However, the role of ARVD as an important contributor to renal failure remains a controversial issue. The original experiments of Goldblatt *et al.* [1] have demonstrated that arterial hypertension due to unilateral renal artery stenosis (RAS) can cause bilateral renal damages. Indeed, because of the reduced perfusion pressure beyond the clip, the tissue of the clipped kidney is exposed to chronic hypoxia, which leads to ischaemic kidney injury. In the unclipped kidney however, renal damage will progressively develop, due to the arterial hypertension caused by the activation of the renin–angiotensin–aldosterone system [1].

In recent years, attention to non-traditional mediators of ARVD such as inflammatory pathways and microvascular events has yielded new paradigms and avenues of research. Among other mechanisms, reactive oxygen species (ROS) production, ischaemia/reperfusion damage and modulation of matrix turnover have been proposed to promote renal failure related to ARVD (Figure 1). The goal of this editorial is to review the potential role of these mediators in ARVD.

Reactive oxygen species and oxidative stress

Atherosclerosis (ATS) is now viewed as a state of chronic inflammation and patients with ARVD may

present progressive chronic renal failure (CRF) related to inflammatory processes that lead to ‘ischaemic nephropathy’, which involves the extension of ATS to the branches of the renal artery, arteriolar thickening, tubular and glomerular atrophy, and glomerulosclerosis [2,3]. These are common features of the progressive renal injury in which oxidative stress has been proposed as playing an important role [4]. Oxidative stress is defined as a tissue injury induced by increase in ROS such as oxygen radicals, which can be generated at different sites along the nephron, like the glomeruli and segments two and three of the proximal tubule [5]. The most common oxygen radicals are superoxide (O_2^-), hydrogen peroxide (H_2O_2) and hydroxyl radical (OH^-). O_2^- and OH^- are more reactive than H_2O_2 , which is not a radical, but which exhibits greater membrane permeability. O_2^- rapidly scavenges nitric oxide (NO) and could therefore blunt NO activity in the renal microvasculature. Since NO inhibits oxygen consumption, it is tempting to speculate that reduced (scavenged) NO during ARVD elevates oxygen consumption, thereby leading to reduced partial oxygen pressure values, with consequences for endothelial–epithelial structure and function. Since ROS are extracellular signaling molecules, they may be significant in mediating the actions of vasoconstrictors, such as angiotensin II, thromboxane A₂, endothelin-1, adenosine and norepinephrine. Thus, ARVD is associated with activation of oxidative pathways, reduction in NO synthesis and stimulation of the renin–angiotensin system, in humans and experimental models. Indeed, recent studies indicate that blockade of oxidative pathways by the superoxide mimetic, tempol in renovascular hypertensive animals produces a fall in arterial pressure comparable to blockade of angiotensin receptors or administration of ACE inhibitors [6,7]. Previous studies indicate that antioxidant vitamin treatment in the swine model modulates activation of fibrogenic pathways, including nuclear factor κ -B (NF- κ B), transforming growth factor- β (TGF- β), and matrix metalloproteinases (MMPs) in kidney tissue [8]. Taken together, these studies

Correspondence and offprint requests to: Pascal Meier, MD, FASN, Service of Nephrology and Hypertension, Centre Hospitalier Universitaire Vaudois (CHUV), Rue de Bugnon, 1011 Lausanne, Switzerland. Email: pascal.meier@chuv.ch

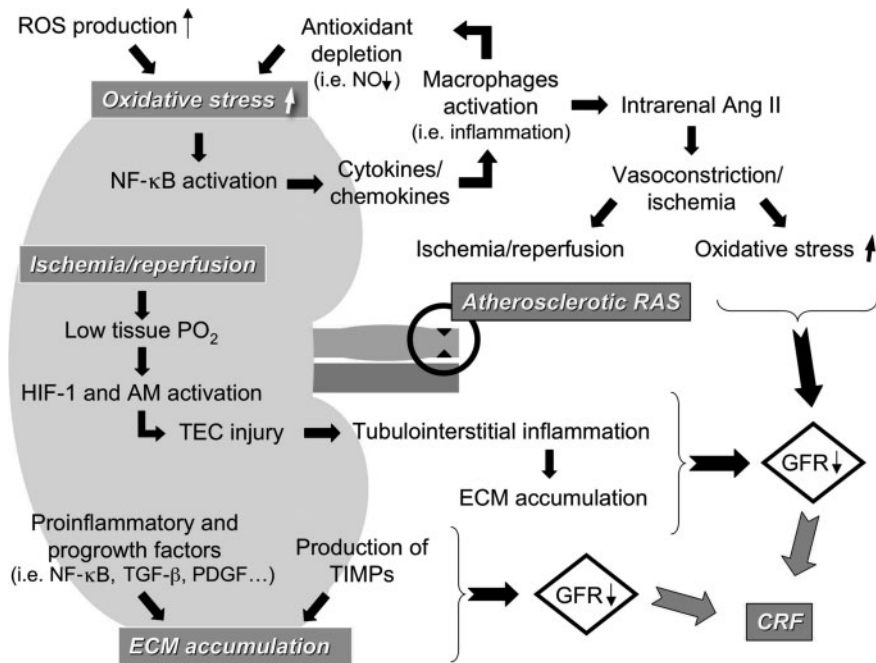


Fig. 1. This schema summarizes current concepts linking atherosclerotic renal artery stenosis with ROS production, ischaemia/reperfusion damage and modulation of matrix turnover to promote renal failure related to atherosclerotic renovascular disease. ROS, reactive oxygen species; NO, nitric oxide; NF- κ B, nuclear factor κ -B; RAS, renal artery stenosis; HIF-1, hypoxia inducible factor-1; AM, adrenomedullin; TEC, tubular epithelial cell; ECM, extracellular matrix; TGF- β , transforming growth factor- β ; PDGF, platelet-derived growth factor; TIMPs, tissue inhibitors of metalloproteinases; GFR, glomerular filtration rate.

emphasize the role of shifts toward oxidative stress as a major pathway sustaining both haemodynamic and functional alterations of the stenotic kidney in ARVD, amplified by chronic mechanisms that promote renal structural injury in the normal and sick kidney [6,8–12]. Furthermore, ROS interfere with renal oxygen usage for tubular sodium transport and enhance tubulo-glomerular feedback [13].

Chade *et al.* [13,14] have shown that increased oxidative stress and upregulation of inflammatory factors in ARVD are associated with marked impairments of renal haemodynamics and function. The authors demonstrated that increased abundance of ROS initially leads to renal microvascular endothelial dysfunction, which may precede and subsequently be aggravated by the development of obstructive lesions in the main renal artery. Notably, although blockade of the oxidative stress pathway substantially attenuated renal injury, it did not completely abolish it, suggesting that additional pathophysiological mechanisms might be involved. The decrease in renal blood flow and subsequent sustained activation of the renin-angiotensin system is probably a major trigger for renal injury in this model [15]. Furthermore, increased local and systemic oxidative stress can facilitate oxidation of LDL, a cytotoxic vasoconstrictor agent that promotes the generation of ROS and augments functional and structural damage in the ischaemic kidney. Reactive oxygen species may thus also play a critical role in the development and progression of CRF due to atherosclerotic RAS, because they are signalling molecules of growth factors and cytokines such as

platelet-derived growth factor and TGF- β [16]. These two factors are upregulated in the so-called ‘ischaemic’ kidney, leading to cell proliferation and extracellular matrix (ECM) accumulation in glomerulus and interstitial tissue (see further) [17].

Ischaemia/reperfusion and renal damage

One hypothesis recognized in the complex cascade of mechanisms encountered in ARVD is represented in the ischaemia/reperfusion phenomenon [18]. Ischaemia/reperfusion damage involves microvascular haemodynamic changes and well-characterized oxidative stress-induced tissue injury. Injury initiated by the lack of oxygen in presence of severe RAS is augmented by ROS once reperfusion is tempted through activation of inflammatory cascade. There is marked congestion and hypoperfusion of the outer medulla, which persist even though cortical blood flow improves during reperfusion after ischaemia. The characteristic post-ischaemic congestion worsens the relative hypoxia, leading to prolonged cellular injury and cell death in the predisposed tubule segments. Mechanisms that underlie these haemodynamic alterations have begun to surface, and they relate primarily to endothelial cell injury [19]. A perturbation of mitochondrial enzyme activity and mitochondrial membrane potential is found under ischaemic conditions, causing cell apoptosis and finally cell death.

Furthermore, a low tissue PO_2 is a well-established stimulus for cell protectors such as adrenomedullin

(AM) expression and hypoxia-inducible factor-1 (HIF-1) in whole kidneys and cultured renal cells [20,21]. Sandner *et al.* [20] suggested that, in response to hypoxic or ischaemic hypoxia, the rather uniform distribution of AM in the rat kidney was changed in keeping with oxygen gradients. In the model of transient ischaemia, tubular damage and AM immunoreactivity was found predominantly in the outer medulla. This could reflect a more rapid and longer-lasting decrease of local PO₂ during transient ischaemia in this zone. In support of this assumption, there is a relatively high density of thick ascending limbs, which are metabolically very active in this region. Although the inner medulla is normally at the limit of hypoxia, it apparently better tolerates transient ischaemic hypoxia. Indeed, tubular epithelial cells (TECs) represent a primary target for hypoxia-elicited injury in ischaemic conditions [21,22]. In such pathologies, non-lethal epithelial dysfunction is typified by increased paracellular permeability and unregulated movement of molecules between compartments normally separated by the tightly controlled epithelial barrier. Hypoxia has been demonstrated to alter the expression of a number of individual genes that contribute to TEC injury [23]. Hypoxia-inducible factor-1 binds to the hypoxia-response element and regulates the expression of a number of adaptive genes coding for angiogenic and glycolytic and other proteins (e.g. erythropoietin and inducible nitric-oxide synthase), which support tissue survival in hypoxia [24]. The data on AM from cultured cells, and previous data on HIF, collectively show that the TECs are directly sensitive to ambient oxygen.

Renal fibrosis and modulation of matrix turnover

The poor response to revascularization observed in ARVD has led to the speculation that synergism between atherogenic factors and hypoperfusion distal to the stenosis might accelerate progressive renal disease, fibrosis, and eventual end-stage renal disease. Renal scarring and tissue remodelling are dynamic processes that involve both synthesis and degradation of extracellular matrix, the balance between which might be disrupted in several renal diseases. Hence, matrix accumulation and fibrosis in ARVD might result from either increased deposition or decreased degradation of the ECM. As discussed before, several proinflammatory and progrowth factors implicated in renal tissue remodeling in ARVD might also be activated in hypercholesterolaemia, a surrogate of early ATS and an independent risk factor for renal disease progression that might promote fibrosis and scarring by increasing the production of fibrogenic factors that stimulate the synthesis of ECM proteins [8]. This is no surprise, as renal scarring is associated with loss of microvasculature, leading to decreased blood flow and impaired oxygenation in areas of fibrosis. However, more recent work has suggested that discrepancies between oxygen demand and supply can

even occur early in diseased kidneys, before visible scarring is detected [25].

A prominent factor likely to be involved in ARVD is oxidized LDL, which may regulate TGF- β . TGF- β expression in ARVD is accompanied by up-regulation and activation of its Smad effectors, underscoring fibrogenic activity [26]. Receptor-regulated Smad-2 and Smad-3 are phosphorylated by the TGF- β receptor, a process that is indispensable to link to Smad-4 (cooperative Smad), and therefore initiates recruitment of transcriptional cofactors involved in cell proliferation and tissue growth [26]. In addition, TGF- β is also a potent inhibitor of ECM degradation. Indeed, it stimulates production of other profibrotic factors such as tissue inhibitors of metalloproteinases (TIMPs), which induce cell proliferation directly and via inhibitory effects on MMPs [27]. Hence, the increase in TIMP-1 and TIMP-2 protein expression was accompanied by downregulation of the expression and activity of MMP-2 and MMP-9, both involved in ECM turnover. MMP-2 and MMP-9 are capable of digesting denatured and native collagen IV, which is often produced in the damaged kidney.

Tubular epithelial cells contribute to the progression of renal fibrosis by undergoing an epithelial–mesenchymal transition (EMT), leading to accumulation of activated fibroblasts in the interstitium [28]. In addition to EMT, apoptosis of TECs is the principal mechanism which leads to loss of viable TECs and tubular atrophy [29].

Clinical consequences

A major question facing physicians and patients with ARVD is whether the benefits of angioplasty outweigh its risks, keeping in mind that in addition to stenotic lesions, the degree of preexisting renal damage is a major determinant of the clinical response to treatment. Can the limited benefits of renal angioplasty on blood pressure and renal function in ARVD be explained by confounding factors? A plausible confounder is intrinsic disease in the post-stenotic or contralateral kidney, which cannot be altered by renal angioplasty or may even be aggravated by the increase in perfusion pressure once the stenosis is relieved.

The appropriate management of patients with ARVD requires accurate knowledge of the natural history of this condition. Therefore, the rate of progression of disease in the renal artery and factors associated with increased rates of progression are important elements to consider, when therapy or follow-up for patients with this disease is being planned [30]. In a recent meta-analysis, none of the trials included showed a significant improvement in renal function with angioplasty, despite a higher arterial patency rate with balloon angioplasty [31]. Because of the frequency of RAS and the lack of clear consensus on its clinical management, the National Institute of Health has funded a prospective,

randomized trial on the subject. This study, the Cardiovascular Outcomes in Renal Artery Lesions (CORAL) trial [32], is intended to determine the best approach to RAS and which patients, if any, will benefit from angioplasty/stent placement. The study seeks to randomize 1080 patients either to angioplasty/stent placement and optimal medical therapy, or to optimal medical therapy alone. The endpoint of this trial is a composite outcome related both to cardiovascular events, hospitalization, and renal dysfunction over a 5 year period. The CORAL trial will add considerably to information that until now has been determined mainly by retrospective observational reports or registries. Furthermore, some authors speculate that medically controlled patients after stenting fare worse than those with uncontrolled blood pressure because of underperfusion related to distal embolization worsened by antihypertensive therapy. The CORAL trial includes a distal protection device to minimize such hazards for those undergoing stenting. These observations argue further that the decision to undertake renal revascularization continues to be complex and highly dependent upon comorbid risks for each patient. Its place might be indicated in patients with high serum creatinine concentrations and bilateral atherosclerotic RAS, those with tight atherosclerotic RAS in a single kidney, and particularly those with flash pulmonary oedema.

Conclusions

The life expectancy of patients with atheromatous disease affecting the renal arteries is drastically reduced, even after stenting of the stenotic lesion [33]. It is, therefore, a difficult task to balance the risks and costs against the expected benefits. Research designed to better understand the underlying pathology of ARVD has already yielded information that has expanded our focus to encompass inflammation and fibrosis among other biological processes. Continued efforts may result in further challenges to some long-held notions and contribute to improved diagnostic and treatment tools. By using clinical and paraclinical tools in combination, better risk profiles may emerge to provide prognostic information, direct therapy, gauge efficacy of interventions, and develop new medications. In 1998, Caps *et al.* [34] identified several classical risk factors for the progression of renal artery disease. Among them, a systolic blood pressure >160 mmHg, the presence of diabetes mellitus and a high grade ipsilateral or contralateral RAS were found to yield a very high risk of disease progression. In the future, new parameters linked to inflammation and ATS might further improve our assessment of the renal risk of patients with ARVD. However, while waiting for these new prognostic factors to be developed, aggressive blood pressure control in patients with ARVD is a critical element to protect renal function. Moreover, an increased emphasis should be put on other risk factors such as

dyslipidaemia, smoking and diabetes, which also increase the risk of renal artery disease progression in patients with ARVD.

Conflict of interest statement. None declared.

References

- Goldblatt H, Lynch J, Hanzal RF, Summerfille WW. Studies on experimental hypertension, I: the production of persistent elevation of systolic blood pressure by means of renal ischemia. *J Exp Med* 1934; 59: 347–379
- Rimmer JM, Gennari FJ. Atherosclerotic renovascular disease and progressive renal failure. *Ann Intern Med* 1993; 118: 712–719
- Plouin PF. Stable patients with atherosclerotic renal artery stenosis should be treated first with medical management. *Am J Kidney Dis* 2003; 42: 851–857
- Zhu XY, Chade AR, Rodriguez-Porcel M *et al.* Cortical microvascular remodeling in the stenotic kidney: role of increased oxidative stress. *Arterioscler Thromb Vasc Biol* 2004; 10: 1854–1859
- Ha Hand, Endou H. Lipid peroxidation in isolated rat nephron segments. *Am J Physiol* 1992; 263: F201–F207
- Welch WJ, Mendonca M, Aslam S, Wilcox CS. Roles of oxidative stress and AT1 receptors in renal hemodynamics and oxygenation in the postclipped 2K,1C kidney. *Hypertension* 2003; 41: 692–696
- Bolterman RJ, Manriquez Mc, Oriz Ruiz MC, Juncos La, Romero JC. Effects of captopril on the renin-angiotensin system, oxidative stress, and endothelin in normal and hypertensive rats. *Hypertension* 2005; 46: 943–947
- Chade AR, Rodriguez-Porcel M, Krier JD, Zhu X, Lerman A, Lerman LO. Beneficial effects of antioxidant vitamins on the stenotic kidney. *Hypertension* 2003; 42: 605–612
- Chade AR, Rodriguez-Porcel M, Grande JP *et al.* Distinct renal injury in early atherosclerosis and renovascular disease. *Circulation* 2002; 106: 1165–1171
- Chade AR, Rodriguez-Porcel M, Grande JP *et al.* Mechanisms of renal structural alterations in combined hypercholesterolemia and renal artery stenosis. *Arterioscler Thromb Vasc Biol* 2003; 23: 1295–1301
- Harrison D, Griendling KK, Landmesser U, Hornig B, Drexler H. Role of oxidative stress in atherosclerosis. *Am J Cardiol* 2003; 91: 7A–11A
- Schnackenberg CG. Physiological and pathophysiological roles of oxygen radicals in the renal microvasculature. *Am J Physiol Regul Integr Comp Physiol* 2002; 282: R335–R342
- Chade AR, Krier JD, Rodriguez-Porcel M *et al.* Comparison of acute and chronic antioxidant interventions in experimental renovascular disease. *Am J Physiol Renal Physiol* 2004; 286: F1079–F1086
- Chade AR, Rodriguez-Porcel M, Herrmann J *et al.* Antioxidant intervention blunts renal injury in experimental renovascular disease. *J Am Soc Nephrol* 2004; 15: 958–966
- Zou LX, Imig JD, von Thun AM, Hymel A, Ono H, Navar LG. Receptor-mediated intrarenal angiotensin II augmentation in angiotensin II-infused rats. *Hypertension* 1996; 28: 669–677
- Sharma K, Cook A, Smith M, Valancius C, Inscho EW. TGF-beta impairs renal autoregulation via generation of ROS. *Am J Physiol Renal Physiol* 2005; 288: F1069–F1077
- Forbes JM, Hewitson TD, Becker GJ, Jones CL. Ischemic acute renal failure: long-term histology of cell and matrix changes in the rat. *Kidney Int* 2000; 57: 2375–2385
- Halimi JM, Al-Najjar A, Buchler M *et al.* Transplant renal artery stenosis: potential role of ischemia/reperfusion injury and long-term outcome following angioplasty. *J Urol* 1999; 161: 28–32

19. Devarajan P. Update on mechanisms of ischemic acute kidney injury. *J Am Soc Nephrol* 2006; 17: 1503–1520
20. Sandner P, Hofbauer KH, Tinel H *et al.* Expression of adrenomedullin in hypoxic and ischemic rat kidneys and human kidneys with arterial stenosis. *Am J Physiol Regul Integr Comp Physiol* 2004; 286: R942–R951
21. Rosenberger C, Mandiote S, Jürgensen JS *et al.* Expression of hypoxia-inducible factor 1 α and -2 α in hypoxic and ischemic rat kidneys. *J Am Soc Nephrol* 2002; 13: 1721–1732
22. Brady HR, Brenner BM, Clarkson M, Lieberthal W. In: Brenner BM, ed. *The Kidney*. W.B. Saunders Co., Philadelphia: 2000; 1201–1262
23. Taylor CT, Fueki N, Agah A, Hershberg RM, Colgan SP. Critical role of cAMP response element binding protein expression in hypoxia-elicited induction of epithelial tumor necrosis factor- α . *J Biol Chem* 1999; 274: 19447–19454
24. Bunn HF, Poyton RO. Oxygen sensing and molecular adaptation to hypoxia. *Physiol Rev* 1996; 76: 839–885
25. Matsumoto M, Tanaka T, Yamamoto T *et al.* Hypoperfusion of peritubular capillaries induces chronic hypoxia before progression of tubulointerstitial injury in a progressive model of rat glomerulonephritis. *J Am Soc Nephrol* 2004; 15: 1574–1581
26. Zhang H, Akman HO, Smith EL, Zhao J, Murphy-Ullrich JE, Batuman OA. Cellular response to hypoxia involves signaling via Smad proteins. *Blood* 2003; 101: 2253–2260
27. Roelofs JJ, Rouschop KM, Leemans JC *et al.* Tissue-type plasminogen activator modulates inflammatory responses and renal function in ischemia reperfusion injury. *J Am Soc Nephrol* 2006; 17: 131–140
28. Iwano M, Plieth D, Danoff TM, Xue C, Okada H, Neilson EG. Evidence that fibroblasts derive from epithelium during tissue fibrosis. *J Clin Invest* 2002; 110: 341–350
29. Zeisberg M, Strutz F, Muller GA. Renal fibrosis: an update. *Curr Opin Nephrol Hypertens* 2001; 10: 315–320
30. Johansson M, Herlitz H, Jensen G, Rundqvist B, Friberg P. Increased cardiovascular mortality in hypertensive patients with renal artery stenosis. Relation to sympathetic activation, renal function and treatment regimens. *J Hypertens* 1999; 17: 1743–1750
31. Nordmann AJ, Woo K, Parkes R, Logan AG. Balloon angioplasty or medical therapy for hypertensive patients with atherosclerotic renal artery stenosis? A meta-analysis of randomized controlled trials. *Am J Med* 2003; 114: 44–50
32. Murphy TP *et al.* The Cardiovascular Outcomes with Renal Atherosclerotic Lesions (CORAL) study: rationale and methods. *J Vasc Interv Radiol* 2005; 16: 1295–1300
33. Harden PN, MacLeod MJ, Rodger RS *et al.* Effect of renal-artery stenting on progression of renovascular renal failure. *Lancet* 1997; 349: 1133–1136
34. Caps MT, Perissinotto C, Zierler RE *et al.* Prospective study of atherosclerotic disease progression in the renal artery. *Circulation* 1998; 98: 2866–2872

Received for publication: 23.8.06

Accepted in revised form: 4.12.06