

# Robotic lobectomy: tips, pitfalls and troubleshooting

Gregor J. Kocher<sup>a,b,\*</sup>, Ralph A. Schmid<sup>b</sup> and Franca M.A. Melfi<sup>a</sup>

<sup>a</sup> Division of Thoracic Surgery, Department of Cardiac, Thoracic and Vascular Surgery, University of Pisa, Pisa, Italy

<sup>b</sup> Division of General Thoracic Surgery, University Hospital of Bern, Bern, Switzerland

\* Corresponding author. Division of General Thoracic Surgery, University Hospital Bern, 3010 Bern, Switzerland. Tel: +41-31-6322330; fax: +41-31-6322327; e-mail: gregor.kocher@insel.ch, gkocher@gmx.ch (G.J. Kocher).

Received 5 August 2014; accepted 25 August 2014

## Abstract

The robotic approach in thoracic surgery has rapidly gained popularity in recent years. As with the introduction of any new technology, this warrants not only adaptation of the operative technique itself, but also the evolution of appropriate troubleshooting strategies. A selected number of helpful tips and technical procedural manoeuvres have been compiled to prevent intraoperative problems, as well as to overcome challenging situations that can arise during robotic lobectomies. In robotic surgery, as opposed to open surgery or video-assisted thoracic surgery, these tips serve an important purpose for the operating surgeon, as well as the entire surgical team involved in the procedure. All the assembled recommendations have proved their effectiveness and have been successfully used by the authors in many procedures. Furthermore, these manoeuvres have been found to be of great importance in the training and proctoring of thoracic surgeons, fellows and residents (bed-side assistants). This guide of clearly arranged tips and troubleshooting strategies offers surgeons a useful tool to overcome difficult situations in robotic lobectomy and preferably improve the reproducibility and safety of their procedures.

**Keywords:** Minimally invasive surgery • Robotics • Surgical techniques • Lobectomy • Lung cancer surgery

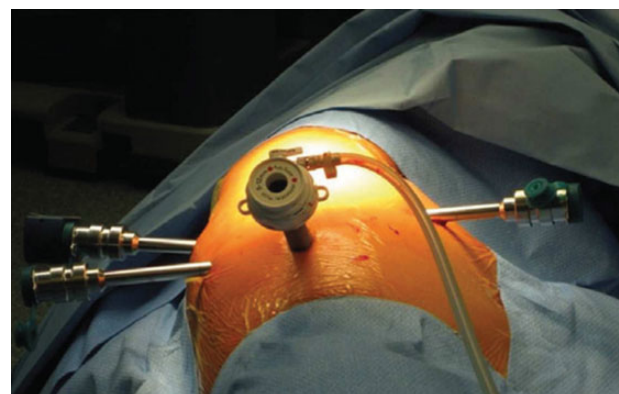
## INTRODUCTION

Since the introduction of the Da Vinci™ robotic surgical system (Intuitive Surgical, Sunnyvale, CA, USA) in thoracic surgery more than 10 years ago, the robotic approach for major lung resection has become increasingly popular worldwide. Besides offering obvious technical advantages, such as 3D high-definition vision and dedicated endo-wristed instruments, there is increasing evidence that this technique is associated with reductions in mortality, length of hospital stay and overall complication rates when compared with both open and video-assisted thoracic surgery (VATS) [1]. Furthermore, in the setting of non-small-cell lung cancer, long-term oncological results have been shown to be at least equal to open surgery and VATS [2]. Nevertheless, with the introduction of this new technology, as already experienced in VATS, a shift in procedural-related problems and challenges can be expected. This prompted us to compile a list of the most useful tips for prevention of intraoperative problems, as well as suggestions on how to overcome challenging situations if and when they occur during robotic thoracic surgery.

## PATIENTS AND METHODS

Our basic robotic approach, which was initially developed and further refined by the senior author (Franca M.A. Melfi), follows the principle of a totally endoscopic procedure with low CO<sub>2</sub> insufflation (maximum 6–8 mmHg) using only the four robotic arms without any assistant port or utility incision (Fig. 1). One of the robotic arms is temporarily removed for the purpose of

introducing an endoscopic stapler. The trocar position remains the same for all lobes and both sides, whereas the camera trocar may be placed slightly more posterior on the left due to the position of the heart. We generally choose an atraumatic grasper (i.e. Prograsper or lung grasper) for retraction of the lung for the fourth arm, the Fenestrated Bipolar Forceps for the left and the Monopolar Cautery Hook for the right arm. Using this aforementioned approach will enable the surgeon to stop the bleeding should this occur, either by monopolar or bipolar cautery, thereby ensuring a clear field of vision. The division of the central structures generally begins with



**Figure 1:** Port mapping for lobectomy on the right. The camera port is placed in the seventh to eighth intercostal space on the midaxillary line (12 mm, 30° angled down scope, CO<sub>2</sub> inlet). The other three 8-mm port incisions are situated in the fifth to sixth intercostal space on the anterior axillary line, the sixth to seventh intercostal space on the posterior axillary line and in the auscultatory area (fourth arm).

**Table 1:** General considerations and common problems and possible solutions

| General considerations   |   |
|--|---|
| Patient positioning  | <ul style="list-style-type: none"> <li>Lateral decubitus position, especially in women, place a pillow under the kidney region to elevate the lower thorax and prevent the camera from colliding with the hip</li> </ul>  |
| Port placement   | <ul style="list-style-type: none"> <li>Keep an adequate distance (<math>\geq 10</math> cm) between ports</li> </ul>   |
| Cart placement   | <ul style="list-style-type: none"> <li>Use a needle for testing the optimal position before creating the porthole</li> <li>Introduce the camera through the port and direct it towards the main target region (central hilum): the robotic cart (central column) should come from imaginary elongation of the line between the camera trocar and the target. Dock patient cart according to the camera arm sweet spot (the blue arrowhead should be in the middle of the blue line).</li> </ul>   |
| Auxiliary material   | <ul style="list-style-type: none"> <li>CO<sub>2</sub> insufflation helps collapse the lung and evacuates smoke</li> <li>Use <i>vessel loops</i> to encircle structures before stapling (easier placement of the anvil)</li> <li>Use <i>gauze</i> for oozing instead of suction (time saving, CO<sub>2</sub> remains)</li> </ul>   |
| Temporarily cease CO <sub>2</sub> insufflation while dissecting/encircling the pulmonary vein, since the vein collapses under intrathoracic pressure levels $\geq 6$ mmHg, which may interfere with safe dissection and encircling of it |   |
| Avoid using clips, since they might slip off or get torn off if caught by gauze or passing stapler/instruments   |   |
| Common problems and possible solutions   |   |
| Pleuropulmonary adhesions  | <ul style="list-style-type: none"> <li>Create space for the camera by digital blunt dissection first, and then introduce VATS endoscopic monopolar shears through the same incision to create more space for the second port etc.</li> </ul>  |
| Exposure problems  | <ul style="list-style-type: none"> <li>Distended lung: let the anaesthetist check the tube and aspirate the airways; simultaneously gently compress the lung, temporarily use higher CO<sub>2</sub> pressure</li> <li>Cauterize bullae (only in the lobe that needs to be resected)</li> </ul>  |
| Collision of robotic arms<br>Collision of the camera with the hip  | <ul style="list-style-type: none"> <li>Angles of proximal joints of the robotic arms might need to be changed a bit</li> <li>Temporarily change the camera angle (from 30° down to up), a pillow under the kidney region elevates the lower chest (especially in women; preoperatively!)</li> </ul>   |
| Area of dissection not reachable by the instrument   | <ul style="list-style-type: none"> <li>Consider switching instruments and their function (dissect with left <math>\leftrightarrow</math> right and retract/expose with right <math>\leftrightarrow</math> left arm)</li> <li>Slightly rearrange proximal joints of the robotic arms</li> </ul>  |
| Lens repeatedly soiled   | <ul style="list-style-type: none"> <li>Remove the camera trocar, ensure haemostasis, place corner of gauze through the porthole and replace the trocar (the gauze will compress and absorb bleeding)</li> </ul>   |
| Trouble passing the stapler around the vessel  | <ul style="list-style-type: none"> <li>Try the other access port; test direction with the straight robotic instrument first</li> <li>Full angulation and slight rotation of the anvil while passing the structure</li> <li>Help passing the anvil by gently guiding it from the other side with a grasper</li> <li>Change the direction of traction of the lobe and/or the vessel loop</li> <li>Consider use of a stapling cartridge with a curved tip</li> <li>Consider use of a short silicon catheter on the stapler anvil tip as a guide [3]</li> <li>Consider ligation of medium-sized vessels and use of a vessel sealer for small vessels</li> </ul> |
| Trouble passing the stapler around the bronchus  | <ul style="list-style-type: none"> <li>See above; if bronchus seems too thick, consider use of a conventional open linear stapler (90° angled; the ventral port needs to be slightly enlarged)</li> </ul>   |
| Air leak   | <ul style="list-style-type: none"> <li>Avoid air leak by gentle lung tissue handling; avoid injuring fragile lung tissue by using 'pushing' instead of 'grasping' manoeuvres; if grasping is required, place a gauze on the lung tissue before grabbing it (as with pot cloth)</li> <li>Submerge the lung under water for air leak testing</li> <li>Seal with a stapling device, clips, lung sealant or suture</li> </ul>   |
| Minor bleeding   | <ul style="list-style-type: none"> <li>In case of fused fissures consider performing the fissure-last technique</li> <li>Diffuse oozing: place thrombostatic material and compress</li> <li>From pulmonary artery: compress for several minutes with a sponge, gauze or thrombostatic material (small bleeders often cease spontaneously)</li> </ul>  |
| Major bleeding   | <ul style="list-style-type: none"> <li>Compress bleeding with a gauze or lung tissue; use robotic suction (you lose one grasper) or let an assistant introduce suction through the additional port</li> <li>Either clip or suture</li> <li>Conversion: either let an assistant compress with a sponge or place a clamp, or grasp the bleeding vessel with the robotic instrument and leave the robotic arm in place while performing thoracotomy</li> </ul>   |

VATS: video-assisted thoracic surgery.

the artery, followed by the vein and finally the division of the bronchus. The fissures are divided at any suitable point during the procedure, either by cautery (if only thin) or by stapling (if thick). In case of fused fissures, a change of the aforementioned strategy might be preferable, such that the vein can be divided first, followed by the arterial branches and the bronchus, leaving for the last the division of the fissure. Smaller arterial branches can be ligated (Linen 2.0), while the vein and the bronchus are divided by means of an endostapler. The specimen is retrieved through the slightly enlarged ventral porthole (wider rib spaces) and one chest

tube inserted through the camera porthole. We work with a completely robotic approach; however, in difficult situations it can be helpful to create an additional ventral assistant port for suction/irrigation, retraction etc.

## RESULTS

Our suggestions have been subdivided into two categories: general (Table 1) and problem-specific considerations. These categories

have been arranged in a tabular format, providing a clear and concise overview of the topic as a whole. These suggestions have evolved over the years, and putting them into practice has proved effective in challenging situations that have arisen. In support of this, for the last 160 patients, who were operated using the described four-arm approach, the conversion rate was as low as 5.6% and hospital mortality rate 0% [4, 5]. While most of our recommendations are specific for a robotic approach and therefore have been applied also by other well-known robotic surgeons [6], others are more non-specific and have, at least in part, also been reported and successfully applied in VATS [7].

## COMMENT

The updated, four-arm versions of the da Vinci system™ [i.e. second (S) and third (Si) generation systems], along with the development of new robotic instruments, allow control of any operative step from the robot's console, with the exception of stapling manoeuvres. We believe that this development was an important step enabling the further refinement of the surgical technique itself, which has had a favourable impact on the safety and reproducibility of the operative procedures [5].

The purpose of this compilation of tips is two-fold: first, to sensitize practitioners to the critical steps of this particular robotic procedure. We believe that, by considering our helpful tips and suggestions, one may be able to not only avoid critical situations, but also to be properly prepared if and when they should arise during the robotic procedure. Second, and equally as important,

this may not only contribute to improving patient safety, but also shorten operative time and hopefully have a positive influence on overall patient outcomes in the end. Although we mainly focused on the intraoperative part, preoperative planning—including proper patient selection—is of course at least as important, but would definitely go beyond the scope of this contribution.

**Conflict of interest:** none declared.

## REFERENCES

- [1] Kent M, Wang T, Whyte R, Curran T, Flores R, Gangadharan S. Open, video-assisted thoracic surgery, and robotic lobectomy: review of a national database. *Ann Thorac Surg* 2014;97:236-42.
- [2] Park H, Melfi F, Mussi A, Maisonneuve P, Spaggiari L, Da Silca RKC *et al.* Robotic lobectomy for non-small cell lung cancer (NSCLC): long-term oncologic results. *J Thorac Cardiovasc Surg* 2012;143:383-9.
- [3] Ito N, Suda T, Inoue T, Yasui S, Suzuki Y, Taniguchi Y *et al.* Use of a soft silicone tube guide for an automatic suture device in video-assisted lung lobectomy. *J Thorac Cardiovasc Surg* 2005;130:931-2.
- [4] Melfi FM, Menconi GF, Mariani AM, Angeletti CA. Early experience with robotic technology for thoracoscopic surgery. *Eur J Cardiothorac Surg* 2002;21:864-8.
- [5] Melfi FM, Fanucchi O, Davini F, Romano G, Lucchi M, Dini P *et al.* Robotic lobectomy for lung cancer: evolution in technique and technology. *Eur J Cardiothorac Surg* 2014;46:626-31.
- [6] Cerfolio RJ, Bryant AS, Minnich DJ. Starting a robotic program in general thoracic surgery: why, how, and lessons learned. *Ann Thorac Surg* 2011;91:1729-36.
- [7] Demmy T, James T, Swanson S, McKenna R, D'Amico T. Troubleshooting video-assisted thoracic surgery lobectomy. *Ann Thorac Surg* 2005;79:1744-53.