

CARDIOVASCULAR FLASHLIGHT

doi:10.1093/eurheartj/ehv211

Online publish-ahead-of-print 3 June 2015

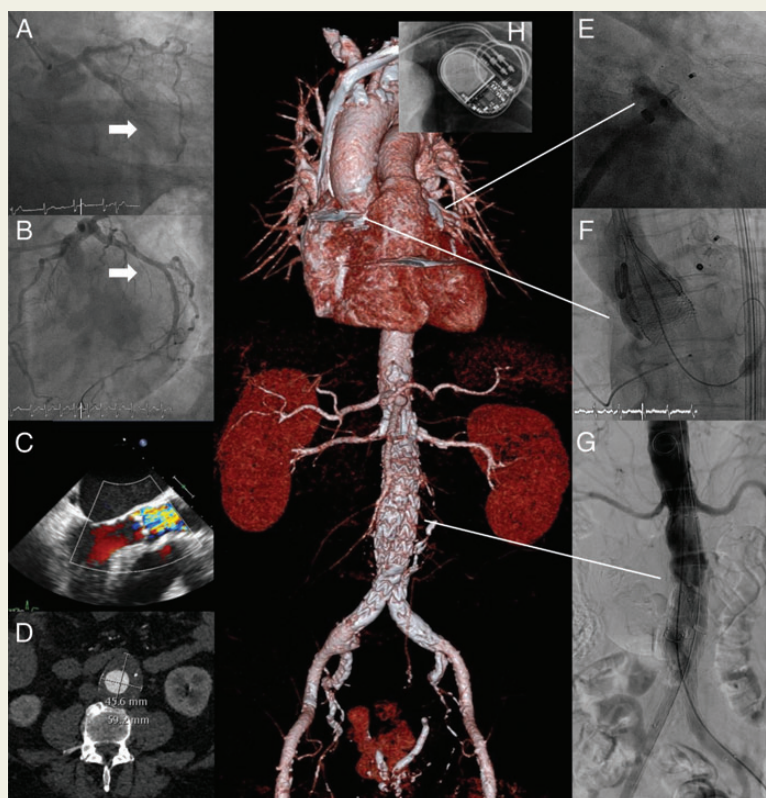
First report of simultaneous transcatheter aortic valve replacement, endovascular aortic aneurysm repair, and permanent pacemaker implantation after multi-vessel coronary stenting and left atrial appendage occlusion

Ronald K. Binder^{1*}, Francesco Maisano², and Mario Lachat²

¹University Heart Center, Department of Cardiology, University Hospital Zürich, Rämistrasse 100, Zürich, CH 8091, Switzerland; and ²University Heart Center, Department of Cardiovascular Surgery, University Hospital Zürich, Zürich, Switzerland

*Corresponding author. Tel: +41 44 255 17 64, Fax: +4144 255 44 01, Email: ronald.binder@usz.ch

A 67-year-old non-compliant alcoholic with chronic renal failure, who stopped taking all medications including oral anti-coagulation a couple of months earlier, was admitted with acute inferior–posterior ST-segment elevation myocardial infarction. From a right radial approach, a proximal occlusion (Panel A) of the dominant circumflex artery was successfully revascularized (Panel B). Significant stenosis of the left anterior descending (LAD) artery, the ramus intermedius, and a high trans-aortic valve gradient was noted during percutaneous coronary intervention (PCI). Echocardiography demonstrated severe aortic valve stenosis (Panel C). Incidentally, an abdominal aortic aneurysm measuring 6 cm was found during computed tomography (Panel D). The situation was interdisciplinary discussed between the cardiologists, heart surgeons, and vascular surgeons. It was decided to pursue a fully percutaneous approach. During a staged PCI, the significant lesions of the LAD and the intermediate branch were treated with drug eluting stents. At the same time, percutaneous left atrial appendage occlusion (Panel E) with an AMPLATZER™ Amulet™ device (St. Jude Medical) was performed. Then simultaneous transcatheter aortic valve implantation (TAVI) (F) from a transfemoral approach using a 27 mm Lotus™ valve (Boston Scientific) and endovascular aneurysm repair (EVAR) with a covered Y-stent-graft was performed (Panel G). Due to intra-procedural complete heart block, a permanent pacemaker (PPM) was implanted (Panel H). The patient recovered well and was found completely asymptomatic 3 months later.



This is the first report of simultaneous TAVI, EVAR, and PPM implantation. It demonstrates in a single patient the evolution of minimally invasive cardiovascular medicine culminating in a fully percutaneous repair of multiple coronary vessels, the aortic valve, and the aortic aneurysm while tackling bradyarrhythmias and excluding the need for oral anti-coagulation by left atrial appendage occlusion.

Conflict of interest: R.K.B. serves as proctor for Boston Scientific and consultant to Edwards Lifesciences. F.M. is consultant for Abbott Vascular, ValtechCardio, Medtronic, Edwards Lifesciences and St Jude.