

Composite graft replacement of the aortic root in acute dissection¹

Urs Niederhäuser *, Hannes Rüdiger, Paul Vogt, Andreas Künzli, Gregor Zünd,
Marko Turina

Clinic for Cardiovascular Surgery, University and City Hospital Triemli, Zurich, Switzerland

Received 30 September 1997; received in revised form 18 November 1997; accepted 2 December 1997

Abstract

Objective: In acute type A dissection the indication for composite graft replacement of the aortic root and the optimal implantation technique are a matter of debate. In this study early and late results of root replacement in acute dissection are determined and compared with supracoronary graft replacement. Two implantation techniques (open vs. inclusion) are evaluated. **Methods:** Between 1985 and 1995, 207 consecutive patients (mean age 58 ± 12 years, 78% men) were operated for acute type A dissection of the aorta. Root replacement in 50 patients (inclusion technique in 34/50 patients with Cabrol shunt in 15/34 patients, open technique in 16/50 patients) was compared with more conservative procedures in 157 patients: supracoronary graft replacement in 143 patients (with aortic valve replacement in 23 patients) and local repair without graft interposition in 14 patients. Preoperative risk factors, like hemodynamic instability, renal failure, neurologic disorder and coronary artery disease did not differ in the two treatment groups. **Results:** Early results, survival and reoperation-free survival after 5 years were insignificantly better after root replacement; mortality 10/50 (20%) vs. 38/157 (24%) $P = \text{n.s.}$; hemorrhage 10/50 (20%) vs. 39/157 (25%) $P = \text{n.s.}$; stroke 5/50 (10%) vs. 27/157 (17%) $P = \text{n.s.}$; survival $70 \pm 7\%$ vs. $63 \pm 4\%$, reoperation free survival $92 \pm 6\%$ vs. $78 \pm 5\%$ $P = 0.0815$). For the open technique, early mortality was 18.8 vs. 20.6%, $P = \text{n.s.}$ and reoperation free survival at 5 years was 80.7 vs. 65.2%, $P = \text{n.s.}$ Perioperative complications did not differ in the two technical groups and a single pseudoaneurysm occurred in the Bentall group. **Conclusion:** In acute dissection composite graft replacement of the aortic root can be carried out with good early and late results not inferior to more conservative procedures. The open technique is the implantation method of choice and the modified Bentall technique is indicated in situations with increased risk of bleeding. © 1998 Elsevier Science B.V. All rights reserved.

Keywords: Ascending aorta; Acute dissection; Composite graft; Survival

1. Introduction

In acute dissection of the ascending aorta, emergency surgery is the therapy of choice to prevent fatal rupture [1]. Despite advances in the diagnostic and therapeutic procedure, early mortality still remains considerable. Long term prognosis is influenced by complications and reoperations due to failures of the primary procedure at

the proximal aortic level or due to distal aortic dissection [2–5]. The correct assessment of the aortic root pathology is difficult but of importance for deciding whether the aortic root has to be replaced. Composite graft implantation in acute dissection allows eradication of the whole aortic root but seems hazardous in view of the technical complexity and the reduced tissue quality of the aortic wall. It was the aim of the present study to determine the early and late results of composite graft replacement of the aortic root in acute dissection. Root replacement was compared with more conservative procedures like supracoronary graft replacement and local repair without graft replacement. Special interest was

* Corresponding author. Tel.: +41 1 4661111; fax: +41 1 4662745.

¹ Presented at the 11th Annual Meeting of The European Association for Cardio-thoracic Surgery, Copenhagen, Denmark, 28 September–1 October, 1997.

focused on the feasibility of the open button technique [6] in acute dissection.

2. Material and methods

Between January 1985 and May 1995, a series of 207 consecutive patients was operated at the university hospital of Zurich for acute type A dissection of the ascending aorta, according the Stanford classification [7]. Clinical data were obtained by retrospective review of hospital records. Postoperative follow-up data contain periodical follow-up reports of cardiologists and written and/or telephone communications with the patients or their physicians. The follow-up was known in 147 long-term survivors (92.5%) with a mean duration of 4.2 years totaling 620 patient-years. Of the 207 patients, 50 (24%) had composite graft replacement of the aortic root. Of the other 157 patients without root replacement, 143 (69%) had supracoronary graft replacement (with aortic valve replacement in 23 patients) and 14 (7%) had local repair without graft interposition or valve replacement. Demographic and preoperative variables are depicted in Table 1. Patients with root replacement were significantly younger ($P = 0.0019$) than all other patients. Besides age no other parameter was significantly different between the two groups.

Marfan disease only occurred in 6 patients (12%) with root replacement ($P = 0.0133$). Cystic media necrosis (Erdheim-Gsell) was found in 10 patients (20%) with composite graft implantation and in 30 patients (19%) of the other group ($P = 0.8894$). For unspecific medial degeneration the corresponding frequencies were 4 (8%) and 18 patients (11%), respectively ($P = 0.4887$). In the root replacement group, a preexisting ascending aortic aneurysm and previous aortic valve replacement was known in 5 patients (10%) each. In the other group, 3 patients (2%) had aneurysmal disease ($P =$

Table 1
Demographic and preoperative patient parameters

Parameter	Composite graft	Other procedure	<i>P</i>
Age (years)	53.5 ± 14.4	60.5 ± 12.4	0.0019
Men	42 (84%)	119 (76%)	0.2243
Women	8 (16%)	38 (24%)	
Interval	13.2 ± 9.8 h	11.7 ± 6.1 h	0.6393
Hemodynamic instability	10 (20%)	28(18%)	0.8080
Neurologic disorder	9 (18%)	48 (31%)	0.0830
Pericardial tamponade	7 (14%)	31 (20%)	0.3608
Renal failure	1 (2%)	10 (7%)	0.2302
Coronary artery disease	4 (8%)	14 (10%)	0.8411

Interval, time interval between onset of symptoms and operation; and hemodynamic instability, systolic blood pressure below 90 mmHg.

0.0098), 3 patients (2%) had previous aortic valve replacement and 7 patients (4%) had CABG ($P = 0.25441$).

Transesophageal echocardiography (TEE) was the standard diagnostic toll and was applied as the only imaging diagnostic procedure in 90% of patients. TEE findings are depicted in Table 2.

2.1. Surgical procedures and techniques

Standard median sternotomy is carried out and total cardiopulmonary bypass is instituted by cannulation of the femoral artery and the right atrium.

Two principal techniques were used for composite graft implantation in 50/207 patients (24%). In 34/50 patients (68%) the classical Bentall [8] procedure was carried out without resection of the aorta. The coronary ostia were implanted to the graft in a side-to-side fashion without detachment from the aortic wall. For

Table 2
Preoperative TEE

Parameter	Composite graft	Other procedure	<i>P</i>
Severe AV regurgitation	28/41 (68%)	36/118 (31%)	<0.0001
Moderate AV degeneration	9/23 (39%)	11/81 (14%)	0.0061
LV Ejection fraction <45%	3/27 (11%)	5/90 (6%)	0.3158
Diameter ascending aorta	62.7 ± 14.6 mm	57.0 ± 15.0 mm	0.0420
Diameter sinus portion	57.9 ± 5.7 mm	39.9 ± 6.8 mm	0.0002
Diameter aortic annulus	27.3 ± 2.1 mm	28.1 ± 7.2 mm	0.8220
Extension of dissection:			
Asc. Aorta	9 (18%)	31 (20%)	0.7855
Asc. Aorta + arch	11 (22%)	21 (13%)	0.1418
Asc. Aorta + arch + desc. Aorta	30 (60%)	105 (67%)	0.3738

Results of different examinations were available in a variable number of patients. The extension of dissection was determined intraoperatively and/or by preoperative TEE.

AV, aortic valve, Asc., ascending, desc., descending, LV, left ventricle.

hemostasis the graft was included with the remnant of the aortic wall. In 15/34 patients (44%) a Cabrol shunt [9] to the right atrium was created. In 16/50 patients (32%) the open technique was carried out. The replaced aortic segment was resected and the coronary ostia were excised with an aortic button. They were implanted into the graft in an end-to-side fashion. The Cabrol modification with graft interposition for coronary revascularization was not used. In 13 patients with root replacement the coronary ostia were dissected and in 4 of them the open technique was applied. In these cases the coronary buttons were reinforced using GRF-glue (gelatine-resorcin-formaldehyde-glue) [10–12] and the sutures were buttressed with an exterior Teflon felt strip. Additionally fibrin glue is used to seal stitch holes. An open distal anastomosis in hypothermic circulatory arrest was carried out in 10/50 patients (20%). In recent years prefabricated zero porosity composite grafts were used with mechanical valve prostheses in 43 patients (86%) and biological prostheses in 7 patients (14%).

Supracoronary graft implantation was carried out in 143 patients (69%) including aortic valve replacement in 23/143 patients (16%). In 37/143 patients (26%) the dissection at the level of the proximal and distal aortic stumps were glued using the two component GRF-glue [10–12]. With this glue dissections can be firmly readapted, the tissue is reinforced making graft interposition and anastomotic suturing safer. The same technique was applied at the distal graft-to-aorta anastomosis in 10/50 patients (20%) with composite graft implantation. A prerequisite for distal gluing was an open anastomosis in hypothermic circulatory arrest.

In 14/207 patients (7%) a local glue aortoplasty was carried out without graft interposition. With this technique the aorta is opened longitudinally, the intimal rupture is closed with a running suture and the dissection is glued with GRF-glue. The aortotomy is closed without need of a buttress. Prerequisite for this technique was the absence of gross aortic pathology besides dissection, no aneurysm, annuloaortic ectasia or Marfan disease.

Total arch replacement was carried out in 1/50 patients (2%) with composite graft implantation and in 3/143 patients (2%) with supracoronary graft implantation. In the former group 39 patients (27%) had partial arch replacement.

In the composite graft group/other group extracorporeal circulation time was 150.4 ± 87.0 / 132.0 ± 70.2 min. ($P = 0.0213$), aortic crossclamp time was 85.0 ± 30.5 / 69.1 ± 30.1 min ($P < 0.0001$) and circulatory arrest time was 16.3 ± 10.1 / 18.2 ± 8.7 ($P = 0.2415$).

3. Statistical analysis

The Statistica software package for Windows (Stat Soft 1993) and the SPSS-program for Windows (SPSS 1989–1995) were used for statistical analysis. Continuous variables were summarized as mean \pm S.D. Predictors for mortality were determined by univariate and multivariate analysis. In univariate analysis discrete variables were analyzed by the χ^2 or Fisher's exact test. Continuous variables were analyzed by the Mann-Whitney test. Statistical significance was associated with a P level of less than 0.05. Selected variables were entered into multivariate analysis by a stepwise logistic regression or by Cox proportional hazard regression to determine independent predictors. The following variables were tested: age, gender, type of dissection, CAD, media necrosis, Marfan, unspecific medial degeneration, preoperative pericardial tamponade, preoperative hemodynamic instability, preop. Neurology, preop. renal failure, entry localized in arch, localization of intimal rupture, reoperation, type of graft implantation, composite graft, procedure on aortic valve, dissection of coronary ostia, technique of graft implantation, Cabrol shunt, crossclamp time, ECC duration, duration of circulatory arrest, IABP, open thorax, use of inotropic drugs, perioperative infarction, use of Aprotinin, rethoracotomy for bleeding, postoperative renal failure, and postoperative sepsis.

4. Results

4.1. Early results

After aortic root replacement with a composite graft early mortality was 10/50 patients (20%). After all other procedures on the proximal aorta early mortality was 38/157 patients (24%, $P = 0.5396$). After composite graft replacement the cause of early death was low cardiac output in 5, cerebral in 2 and hemorrhage in 3 patients after graft inclusion. In the other patient group, the cause of early death was low cardiac output in 10 ($P = 0.2953$), cerebral in 10 ($P = 0.5324$), hemorrhage in 7 ($P = 0.6580$), sepsis with multiorgan failure in 7 and sudden death in 4 patients.

The following postoperative complications occurred after composite graft replacement/non composite graft replacement: rethoracotomy for hemorrhage in 10 (20%)/in 39 patients (25%, $P = 0.4649$); perioperative myocardial infarction in 5 (10%)/in 15 patients (10%, $P = 0.9260$); and persistent neurologic disorder in 5 (10%)/in 27 patients (17%, $P = 0.2202$).

Early results and complications of the two implantation techniques for composite grafts are depicted in Table 3.

Table 3

Early results of the inclusion technique and the open technique for composite graft insertion

Parameter	Inclusion technique (n = 34)	Open technique (n = 16)	P
Early mortality	7 (20.6%)	3 (18.8%)	0.8795
Low cardiac output	14 (41%)	4 (25%)	0.3316
Reexploration (hemorrhage)	7 (21%)	3 (19%)	0.8795
Perioperative Infarction	3 (9%)	2 (13%)	0.6861

Significant univariate predictors for early mortality were: age ($P = 0.0208$), preoperative hemodynamic instability ($P = 0.0589$); preoperative renal failure ($P = 0.0378$); aortic crossclamp time ($P = 0.0257$); use of inotropic drugs ($P = 0.0005$); and open thorax for bleeding complications ($P < 0.0001$).

Significant independent predictors for early mortality were: use of inotropic drugs ($P = 0.0502$); and open thorax ($P = 0.0058$).

4.2. Late results

Survival in the two treatment groups (local repair excluded) is depicted in Fig. 1. After 5 years, survival was $70.1 \pm 6.8\%$ for aortic root replacement and $62.7 \pm 4.3\%$ for supracoronary graft replacement. There was no difference between the two groups ($P = 0.3401$).

In the late follow-up 22 patients died: from cerebral causes 5; myocardial infarction 2; congestive heart failure 3; sudden death 5; malignancy 1; and for unknown causes 6. After composite graft implantation using the inclusion technique actuarial survival after 5 years was 65.2% and for the open technique it was 80.7% ($P = 0.2119$).

A local reoperation at the proximal aorta had to be carried out in 2 patients after root replacement (4%), in 1 patient, replacement of a degenerated biological valve and in the other patient valve replacement and supracoronary graft insertion for valve dysfunction and pseudoaneurysm formation at the distal suture line. Local reoperations after supracoronary graft replacement were necessary in 12 patients (8%, $P = 0.5734$).

Considering only root replacement, the open technique was followed by no local reoperation but one distal reintervention with thoracoabdominal graft insertion for aneurysmal disease of a dissected aorta. After the Bentall technique, two local reoperations were carried out including the only pseudoaneurysm.

Reoperation free survival after root replacement was $91.6 \pm 6.1\%$ at 5 years (Fig. 2). After supracoronary graft replacement the corresponding rate was $78.0 \pm 5.1\%$. The difference was not significant ($P = 0.0815$).

5. Discussion

The optimal treatment of the aortic root in acute dissection is still a matter of debate [13–15]. In situations with marginal annuloaortic ectasia, radical root replacement is often avoided in fear of technical difficulties and increased risk when the coronary ostia are involved in the dissection process. The reconstruction of a morphological normal aortic valve proved to be safe [16,17]. The question is if a dissected aortic root, dissected coronary ostia and a certain dilatation of the sinus portion and annulus can be reconstructed with good outcome. The optimal technique for composite graft insertion in acute dissection is another technical problem under discussion.

With this background the study has evaluated the results of 50 patients with composite graft replacement of the aortic root in acute dissection and compared them with other more conservative procedures (supracoronary graft replacement 143, local repair 14). Besides younger age in the root replacement group there was no difference in other known preoperative risk factors. Early mortality (20% after root replacement, 24% after conservative root surgery) and long-term survival were not increased after radical root replacement and there was no statistically significant difference between the two surgical procedures. These results compare with the literature. In mostly small patient series with aortic root replacement in acute dissection early mortality is documented between 15% [18,15] and 29% [19] and 5 year survival between 51% [13] and 87.5% [15]. In the present study early mortality after composite graft insertion was not increased despite significantly longer operation times (ECC, crossclamp). This may reflect recent improvements in circulatory support and organ protection allowing extended procedures without increased risk. In the whole study population however duration of the crossclamp time was a univariate significant risk factor for early death. The rate of postoperative complications was similar in both groups.

Early mortality and morbidity were also not different when the two implantation techniques of composite grafts are compared. With a reexploration rate for hemorrhage of 19% the open button technique did not entail more bleeding complications. In combined patient series with dissection and non dissection similar

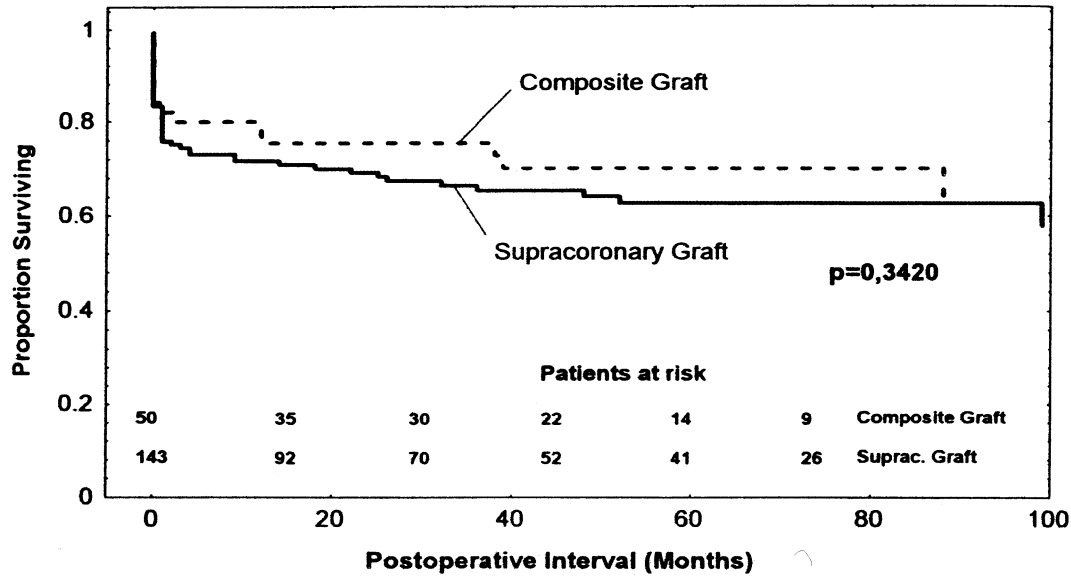


Fig. 1. Survival (Kaplan-Meier) comparing root replacement and supracoronary graft replacement in acute dissection. Local repair is excluded.

results for the open technique were found by Kouchoukos [6], Svensson [20], Hilgenberg [18] and Lepore [19].

Local reoperations at the level of the proximal aorta can be the sequelae of technical errors or malassessment of the aortic pathology during the first intervention. They were more frequent after supracoronary graft replacement and never occurred after open composite graft implantation. Kouchoukos and coworkers [6] reported a significant reduction of reoperations following the open technique (2 vs. 13%) In his series pseudoaneurysms at anastomotic suture lines occurred in 9% and only after the inclusion technique. In the series of

Svensson [20] no patient operated on with the open technique required reoperation in contrast to 12 patients with a Bentall repair (6 pseudoaneurysms). Similar experiences were made by Crawford [21], who advocates the open technique and in acute dissection the Cabrol modification of coronary ostial implantation with use of a vein graft interposition. In our series a pseudoaneurysm occurred in a single patient and never when the open technique was applied. This low rate of pseudoaneurysms may be explained by the fact that we strictly performed a drainage of the perigraft space to the right atrium (44% of inclusion procedures) in case of excessive bleeding. This technical modification de-

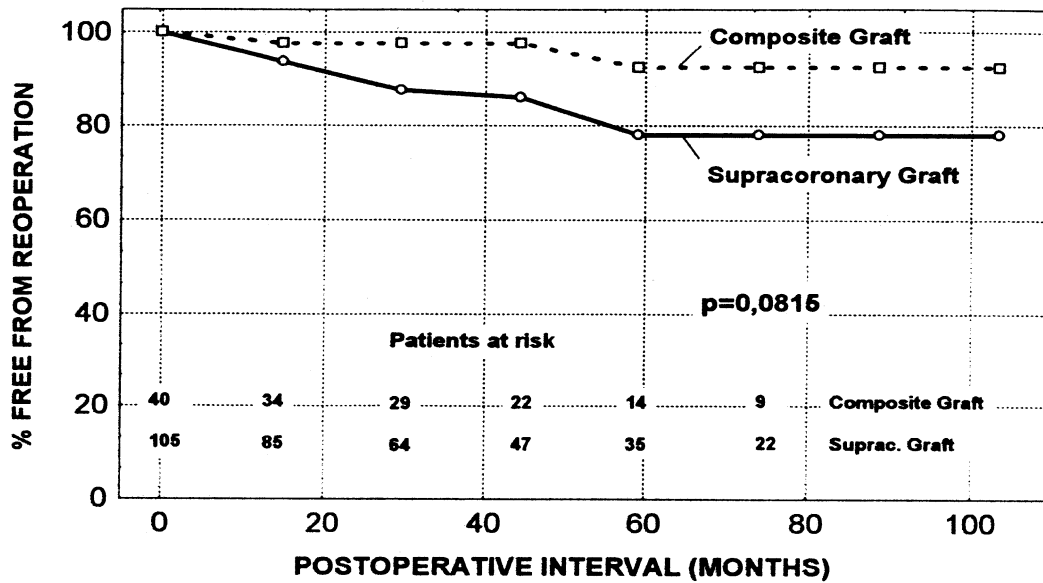


Fig. 2. Actuarial freedom from reoperation comparing root replacement with supracoronary graft replacement in acute dissection. Early mortality, early reinterventions for hemorrhage and local repair excluded.

scribed by Cabrol [9] decompresses the perigraft space in order to reduce tension on suture lines, a principal mechanism of pseudoaneurysm formation. In a series of 192 inclusion procedures (92% elective indications, 35% with Cabrol shunt) Lewis [14] reported a similar experience with only two pseudoaneurysms. In the long-term follow-up reoperation free survival (early mortality excluded) after 5 years was 92% after root replacement and 77% after supracoronary graft replacement. This difference was approaching statistical significance.

In view of the good early and late results, composite graft replacement in patients with acute dissection is considered a safe procedure. In marginal ectasia of the aortic root it is a valuable alternative to supracoronary graft implantation and valve preservation. This is in contrast to Lytle [13] who reports about inferior long-term results of composite grafts in acute dissections and strongly advocates preserving the aortic valve except in Marfan patients and annuloaortic ectasia. Composite grafts in most patients need anticoagulant therapy because of a mechanical valve exposing these patients to the risk of hemorrhage especially in persistent aortic dissection. In the series of Lytle [13] 43% of late deaths were sudden or caused by rupture of a remote aortic segment and in the report of DeBakey [2] 29.3% of all late deaths followed development and rupture of an aneurysm. Late after repair of type A dissection Haverich [3] found 18% of all deaths related to aortic rupture. In our patients, sudden death of unknown origin was responsible for 31% of late deaths and hemorrhage did not occur. Careful long-term monitoring and antihypertensive treatment of patients treated for aortic dissection is essential to avoid such complications and is widely recommended in the literature [3,2,22]. It is concluded that composite graft replacement of the aortic root in acute dissection is a safe procedure with good early and late results not inferior to supracoronary graft replacement. It is mandatory in Marfan disease and annuloaortic ectasia. In marginal root pathology it is a valuable alternative to supracoronary graft replacement. With this approach the rate of local reoperations could be favorably influenced. The open technique avoids pseudoaneurysm formation and is the method of choice. The Bentall technique may be indicated in situations with a high risk of bleeding (reoperation, coagulation disorders). With a concomitant Cabrol shunt the rate of pseudoaneurysms could be reduced.

Acknowledgements

We acknowledge the assistance of our statistical consultant Dr Burkhard Seifert

References

- [1] Masuda Y, Yamada Z, Morooka N, Watanabe S, Inagaki Y. Prognosis of patients with medically treated aortic dissections. *Circulation* 1991;84(Suppl III):7–13.
- [2] DeBakey ME, McCollum CH, Crawford ES, Morris GC, Howell J, Noon GP, Lawrie G. Dissection and dissecting aneurysms of the aorta: 20-year follow-up of 527 patients treated surgically. *Surgery* 1982;92:1118–34.
- [3] Haverich A, Miller DC, Scott WC, Mitchell RS, Oyer PE, Stinson EB, Shumway NE. Acute and chronic aortic dissections—determinants of long-term outcome for operative survivors. *Circulation* 1985;Suppl II:22–34.
- [4] Svensson LG, Crawford ES, Hess KR, Coselli JS, Safi HJ. Dissection of the aorta and dissecting aortic aneurysms. *Circulation* 1990;82(Suppl IV):24–38.
- [5] Ergin MA, Phillips RA, Galla JD, Lansman SL, Mendelson DS, Quintana CS, Griep RB. Significance of distal false lumen after type A dissection repair. *Ann Thorac Surg* 1994;57:820–5.
- [6] Kouchoukos NT, Wareing TH, Murphy SF, Perrillo JB. Sixteen-year experience with aortic root replacement. Results of 172 operations. *Ann Surg* 1991;214:308–20.
- [7] Daily PO, Trueblood HW, Stinson EB. Management of acute aortic dissections. *Ann Thorac Surg* 1970;10:237–47.
- [8] Bentall H, De Bono A. A technique for complete replacement of the ascending aorta. *Thorax* 1968;23:338–9.
- [9] Cabrol C, Pavie A, Gandjbakhch I, Villemont JP, Guiraudon G, Laughlin L, Etievent Ph, Cham B. Complete replacement of the ascending aorta with reimplantation of the coronary arteries. New surgical approach. *J Thorac Cardiovasc Surg* 1981;81:309–15.
- [10] Guilmet D, Bachet J, Goudot B, Laurian C, Gigou F, Bical O, Barbagelatta M. Use of biological glue in acute aortic dissection. A new surgical technique. Preliminary clinical results with a new surgical technique. *J Thorac Cardiovasc Surg* 1979;77:516–21.
- [11] Fabiani JN, Jebara VA, Deloche A, Carpentier A. Use of glue without graft replacement for type A dissections: a new surgical technique. *Ann Thorac Surg* 1990;50:143–5.
- [12] Bachet J, Goudot B, Teodori G, Brodaty D, Dubois C, De Lentdecker P, Guilmet D. Surgery of type A acute aortic dissection with gelatine-resorcine-formol biological glue: a 12-year experience. *J Cardiovasc Surg* 1990;31:263–73.
- [13] Lytle BW, Mahfood SS, Cosgrove DM, Loop FD. Replacement of the ascending aorta. Early and late results. *J Thorac Cardiovasc Surg* 1990;99:651–8.
- [14] Lewis CT, Cooley DA, Murphy MC, Talledo O, Vega D. Surgical repair of aortic root aneurysms in 280 patients. *Ann Thorac Surg* 1992;53:38–46.
- [15] Ergin MA, McCullough J, Galla JD, Lansman SL, Griep RB. Radical replacement of the aortic root in acute type A dissection: indications and outcome. *Eur J Cardio-thorac Surg* 1996;10:840–5.
- [16] Von Segesser LK, Lorenzetti E, Lachat M, Niederhauser U, Schonbeck M, Vogt PR, Turina MI. Aortic valve preservation in acute type A dissection: is it sound? *J Thorac Cardiovasc Surg* 1996;111:381–91.
- [17] Fann JI, Glower DD, Miller DC, Yun KL, Rankin JS, White WD, Smith LR, Wolfe WG, Shumway NE. Preservation of aortic valve in type A aortic dissection complicated by aortic regurgitation. *J Thorac Cardiovasc Surg* 1991;102:62–75.
- [18] Hilgenberg AD, Akins CW, Logan DL, Vlahakes GJ, Buckley MJ, Madsen JC. Composite aortic root replacement with direct coronary artery implantation. *Ann Thorac Surg* 1996;62:1090–5.
- [19] Lepore V, Larsson S, Bugge M, Mantovani V, Karlsson T. Replacement of the ascending aorta with composite valve grafts: long-term results. *J Heart Valve Dis* 1996;5:240–6.

- [20] Svensson LG, Crawford ES, Hess KR, Coselli JS, Safi HJ. Composite valve graft replacement of the proximal aorta: comparison of techniques in 348 patients. *Ann Thorac Surg* 1992;54:427–39.
- [21] Crawford ES, Svensson LG, Coselli JS, Safi HJ, Hess KR. Surgical treatment of aneurysm and/or dissection of the ascending aorta, transverse aortic arch and ascending aorta and transverse aortic arch. Factors influencing survival in 717 patients. *J Thorac Cardiovasc Surg* 1989;98:659–74.
- [22] Fann JI, Smith JA, Miller DC, Mitchell RS, Moore KA, Grunkemeier G, Stinson EB, Oyer PE, Reitz BA, Shumway NE. Surgical management of aortic dissection during a 30-year period. *Circulation* 1995;92(II):113–21.

Appendix A. Conference discussion

Dr Westaby (Oxford, UK): Can I ask you very quickly, what were your indications for replacing the aortic root in non-Marfan's patients? And do you use glue repair or resuspension with Teflon in the conventional way?

Dr Niederhäuser: During the first 5 years of the study period, commissural suture resuspension of the aortic valve was carried out in 9.5% of patients with conservative treatment of the aortic root. Root reconstruction using French glue was carried out in the other 90.5% of patients. Aortic valve and/or aortic root preservation was possible in 63% of all patients with acute dissection. In the long term follow up root reconstruction using French glue was superior to suture resuspension, with a significantly better reoperation-free and event-free survival.

Dr Westaby: So which ones do you use to replace the root?

Dr Niederhäuser: Root replacement was carried out in definite annuloaortic ectasia and Marfan.

Dr Althaus (Bern, Switzerland): I would like to know in what percent of your patients with acute aortic dissection you actually use a composite graft? I think that in most instances with aortic dissection, the aortic valve is morphologically normal and can be preserved. My second question is related to the incidence of false aneurysm. How often did you find a false aneurysm when you used the inclusion technique?

Dr Niederhäuser: Root replacement with a composite graft was carried out in 24% of patients. In TEE, 19% of all patients had moderate to severe degeneration of the aortic valve.

Dr Althaus: What is the incidence of false aneurysm when you used the inclusion technique.

Dr Niederhäuser: The inclusion technique (Bentall technique) was carried out in 34/50 patients (68%) with composite graft replacement of the aortic root. Pseudoaneurysm formation occurred only in 1 patient with graft inclusion (1/34 patients = 3%) and never in the open technique group.

Dr Okita (Osaka, Japan): I totally agree with you regarding your open technique and the Bentall procedure, it's quite safe. However, I have to disagree with your indications for Bentall operation. We have

acute aortic type A dissection in more than 100 patients, including 11 Marfan patients. And we did only nine Bentall operations. The others had repair of the aortic valve, transecting the aorta immediately above the sinotubular junction and resuspension of the aortic commissure. Glue or not, it doesn't matter. And over a 15-year span, we had to reoperate on only 1 patient because of aortic regurgitation. That was the bicuspid valve. We are very satisfied about that. As a policy of acute type A dissection, we tried not to do a Bentall operation, because a prosthetic valve added a new risk of anticoagulation which prevents thrombosis of the distal false lumen in this setting. And I have one question for you. What is the cause of reoperation in your patients who had grafts in this group?

Dr Niederhäuser: Local reoperations after supracoronary graft replacement were carried out in 12/143 patients (8%). The indications for reoperation in this subgroup were: aortic valve regurgitation and persistent dissection in 5 patients, aneurysm formation of the aortic sinus in 2 patients, aortic valve regurgitation in 2 patients, valve regurgitation and aneurysm formation of the aortic arch in 2 patients and endocarditis in 1 patient.

Dr Bachet (Suresnes, France): We have now operated on 193 patients with acute type A dissection; and among those, 36 underwent a composite graft replacement. All those patients had Marfan syndrome or annuloaortic ectasia. I do believe and I hope that you share my opinion, that in patients with acute dissection the aortic valve should be spared as often as possible. And I would like to ask your opinion concerning the operation described in the 1980s by Magdi Yacoub, and more recently by Tirone David, in which you totally replace the aortic root, while preserving the aortic valve. We have done that three times and I think this could be a nice option for those patients. Neither did I understand in what patients, of those who were not Marfan patients, you decided to replace the valve, and on what basis you made this decision. Can you explain that again?

Dr Niederhäuser: In acute dissection valve replacement depends on the morphology of the valve itself and of the aortic root. If there is moderate to severe degeneration or in the case of a calcified bicuspid valve a prosthetic replacement is carried out. Significant valve degeneration was documented in 19% of all patients. In annuloaortic ectasia and in Marfan a valved composite graft is implanted.

Dr Bachet: And last but not least, may I disagree totally with your conclusion about using the Cabrol operation in these kind of patients. We have studied the different means of reimplanting the coronary arteries in those patients and obviously the best way of getting immediate and long-term excellent results is to use the button technique, especially in acute dissection, because it's the only way, then you can see that you take the whole thickness of the aortic wall in your suture. The classical Bentall technique and the Cabrol technique are not in my opinion very good techniques for these kind of patients.

Dr Turina (Zurich, Switzerland): May I just bring a word of clarification. Dr. Niederhäuser is speaking of the connection to the right atrium, calling it the Cabrol shunt. It is not the Cabrol technique which anastomoses the coronaries to the piece of graft, which we very rarely use, and then only for the redos.

Dr Bachet: Well, in my opinion this is worse.