

Cost-effective therapy remission assessment in lymphoma patients using 2-[fluorine-18]fluoro-2-deoxy-D-glucose–positron emission tomography/computed tomography: is an end of treatment exam necessary in all patients?

K. Strobel^{1*}, N. G. Schaefer², C. Renner², P. Veit-Haibach¹, D. Husarik¹, A. Y. Koma¹ & T. F. Hany¹

¹Department of Nuclear Medicine, University Hospital Zurich; ²Department of Internal Medicine, Oncology, University Hospital Zurich, Zurich, Switzerland

Background: The aim of this study was to evaluate the necessity of 2-[fluorine-18]fluoro-2-deoxy-D-glucose–positron emission tomography/computed tomography (FDG–PET/CT) after end of treatment in lymphoma patients who had an interim FDG–PET/CT.

Patients and methods: In 38 patients with Hodgkin's disease (HD) and 30 patients with non-Hodgkin's lymphoma (NHL) interim PET/CT (intPET) after two to four cycles of chemotherapy and PET/CT after completion of first-line treatment (endPET) were carried out. Cost reduction was retrospectively calculated for the potentially superfluous endPET examinations.

Results: In 31 (82%) HD patients, intPET demonstrated complete remission (CR) which was still present on endPET. The remaining seven HD patients (18%) had partial remission (PR) on intPET. For NHL, 22 (73%) patients had CR on intPET analysis which was still present on endPET. In the remaining eight NHL patients, intPET revealed PR in seven and stable disease in one patient. None of all intPET complete responders progressed until the end of therapy. Thus, of the 196 PET/CT's carried out in our study population, 53 endPET's (27.0%) were carried out in interim complete responders.

Conclusion: End-treatment PET/CT is unnecessary if intPET shows CR and the clinical course is uncomplicated. An imaging cost reduction of 27% in our study population could have been achieved by omitting end of treatment FDG–PET/CT in interim complete responders.

Key words: lymphoma, therapy, remission assessment, FDG–PET/CT, cost effectiveness

introduction

Lymphomas are very sensitive to chemotherapy and radiotherapy. Recent developments in treatment have improved the outcome markedly and are cost-effective [1, 2]. Most patients with Hodgkin's disease (HD) or non-Hodgkin's lymphoma (NHL) can be treated successfully with curative intent. Because of its superior diagnostic performance 2-[fluorine-18]fluoro-2-deoxy-D-glucose–positron emission tomography/computed tomography (FDG–PET/CT) has replaced CT alone in many institutions for primary staging in patients with newly diagnosed lymphoma [3–6]. In several studies, FDG–PET has also proven to be the best noninvasive imaging tool for early remission assessment [7]. The use of PET/CT in staging and therapy remission assessment in lymphoma patients are under discussion and the published recommendations are controversial [8–10]. PET/CT is a relatively

expensive imaging technique with mean costs per scan of ~1900 US dollars [11]. Furthermore, the effective radiation dose of a single whole body PET/CT scan can reach up to 25 mSv—another argument to avoid unnecessary PET/CT examinations, especially in young patients [12]. Only a few studies deal with the topic of cost-effective use of PET/CT in oncology [13–15].

The purpose of this retrospective study was to evaluate the clinical value and necessity of FDG–PET/CT after the end of first-line therapy in patients with HD and NHL compared with results of interim staging FDG–PET/CT after two to four cycles of chemotherapy. The second aim of the study was to calculate the potential cost reduction by omitting the end of treatment PET/CT examinations in complete interim responders.

patients and methods

patients

We received approval from our institutional review board to undertake this study.

*Correspondence to: Dr K. Strobel, Division of Nuclear Medicine, University Hospital Zurich, Raemistr. 100, CH-8091 Zurich, Switzerland. Tel: +41-1-255-28-50; Fax: +41-1-255-44-14; E-mail: klaus.strobel@usz.ch

All PET/CT investigations carried out from January 2001 to August 2005 in our institution for staging and therapy assessment in lymphoma patients were reviewed retrospectively. Inclusion criteria for this study were: (i) a histologically proven HD or NHL [large B-cell lymphoma (DLBCL), burkitt-like lymphoma or Burkitt's lymphoma], (ii) an interim PET/CT (intPET) after two to four cycles of chemotherapy and (iii) an end of treatment PET/CT, carried out 6 weeks after chemo-/chemoimmunotherapy or 10 weeks after radiotherapy. This resulted in a study population of 68 patients; 38 patients with HD [27 male, 11 female; mean age 34.2 years, range 10–71 years, 24 (63.2%) stage I/II and 14 (36.8%) stage III/IV]. Of these HD patients, 25 had nodular sclerosis, five had mixed cellularity and eight had lymphocyte-rich classical type. Thirty patients with NHL (20 male, 10 female; mean age 46.3 years, range 17–74 years), comprised of 15 (50%) stage I/II and 15 (50%) stage III/IV. Twenty-six patients had a DLBCL, two patients a burkitt-like lymphoma, one a Burkitt's lymphoma and one a post-transplantation lymphoproliferative B-cell NHL lymphoma (PTLD). Patient characteristics are summarized in Table 1.

treatment

Patients were treated according to departmental protocols. Twelve of the 38 Hodgkin's patients were treated with four to eight cycles of bleomycin, etoposide, adriamycin, cyclophosphamide, oncovin, procarbazine and prednisone, 26 with four to eight cycles of ABVD (adriamycin, bleomycin, vinblastin and dacarbazine). Thirteen HD patients received additional radiotherapy.

Twenty-three of the 26 patients with DLBCL were treated with four to six cycles of R-CHOP (rituximab, cyclophosphamide, doxorubicin, vincristine and prednisone). One patient with DLBCL was treated with six cycles CHOP. Three patients (one DLBCL, one Burkitt's lymphoma, one burkitt-like B-cell lymphoma) were treated with rituximab, hyperfractionated cyclophosphamide, vincristine, doxorubicin and dexamethason. Two patients (one DLBCL, one PTL) were treated with four cycles rituximab and one patient with burkitt-like lymphoma was treated with two cycles R-CHOP and four cycles of etoposide, prednisone, vincristine, cyclophosphamide and doxorubicin. Seven of the 30 NHL patients received additionally radiotherapy.

PET/CT imaging

All data were acquired on a combined PET/CT in-line system (Discovery LS or Discovery ST, GE Health Systems, Milwaukee, WI). This system integrates a PET scanner (GE Advance Nxi, GE Health Systems, Milwaukee, WI) with a multislice helical CT (LightSpeed plus or Lightspeed 16; GE

Health Systems, Milwaukee, WI) and permits the acquisition of coregistered CT and PET images in one session.

Patients fasted for at least 4 h before scanning, which started 60 min after the injection of 350–400 MBq of ^{18}F -FDG. Oral CT contrast agent (Micropaque Scanner, Guerbet AG, Aulnay-sous-bois, France) was administered 15 min before the injection of ^{18}F -FDG. Patients were examined in the supine position. No intravenous contrast agent was given. Initially, the CT scan was acquired starting from the level of the head using the following parameters: 40 mAs, 140 kV, 0.5 sec/tube rotation, slice thickness 4.25 mm, scan length 867 mm, data-acquisition time 22.5 s. The CT scan was acquired during breath holding in the normal expiratory position. For patients with lymphoma manifestations in the lower extremities, scanning of the lower legs was added.

Immediately following the CT acquisition, a PET emission scan was carried out with an acquisition time of 3 min per cradle position with a one-slice overlap. The eight to nine cradle positions from the knees to the head resulted in an acquisition time of ~24–27 min. The CT data were used for the attenuation correction and images were reconstructed using a standard iterative algorithm (OSEM). All images acquired were viewed with a software providing multiplanar reformatted images of PET alone, CT alone and fused PET/CT with linked cursors using a commercially available workstation (Xeleris, GE Health Systems, Milwaukee, WI).

SUV max measurement

Semiquantitative analysis of FDG uptake in the lymphoma deposits was carried out by measuring the standard uptake value (SUV) max. A personal scale (Tanita, model 2001; Tanita, Tokyo, Japan) with an integrated foot-to-foot bioelectric impedance analyzer was used to determine the lean body mass (LBM) of the patients. The manufacture-supplied equations for this model incorporate sex, mass, height and a measured impedance value to determine the percentage of body fat and for calculation of LBM. By using attenuation-corrected PET data, SUV max. were calculated with the following equation by creating a freehand region of interest over the complete visible lesion on the fused PET/CT image: $\text{SUV}_{\text{max(lbm)}} = (\text{LBM} - C_{\text{FDG}}) / \text{dose}$ where LBM is measured in grams, C_{FDG} is the concentration of ^{18}F -FDG in Becquerel's per milliliter, and dose is the injected dose measured in Becquerel's.

PET/CT interpretation

The PET/CT investigations were reviewed by two experienced readers (one reader double board certified in radiology and nuclear medicine and the other reader board certified in radiology and with 2 years experience in PET/CT reading) by consensus. All PET/CT examinations were evaluated regarding the presence and extent of FDG-positive lymphoma and FDG-negative structural residual soft-tissue abnormalities during/after therapy. Therapy remission was assessed using the following criteria: complete remission, FDG uptake resolved completely; partial remission, >25% decrease of SUV max; stable disease, <25% increase or <15% decrease of SUV max; progressive disease (PD), >25% increase of SUV max, new FDG-positive manifestations [16]. In accordance with the recommendations of the International Harmonization Project (IHP) for PET use in patients with lymphoma mediastinal blood pool structures (MBPS) uptake being used as a 'reference background tissue' to define PET positivity for a residual mass (RM) ≥ 2 cm in greatest transverse diameter [9]. RM was only considered positive when uptake intensity was greater than MBPS. RM's <2 cm were considered positive if the uptake was greater than their background activity.

FDG-PET/CT costs

Costs for a partial body FDG-PET/CT investigation with our standard low-dose CT protocol which is used in our institution for staging and therapy assessment of lymphoma patients, were calculated at 1900 US dollars.

Table 1. Patients' characteristics

Characteristic	HD	NHL
N	38	30
M : F	27 : 11	20 : 10
Mean age	34.2	46.3
Age range	10–71	17–74
Histology/type	Nodular sclerosis: 25, Mixed cellularity: 5, Lymphocytic-rich classic: 8	DLBCL: 26, Burkitt-like: 2, Burkitt: 1, PTL: 1
Stage I/II	24	15
Stage III/IV	14	15

HD, Hodgkin's disease; NHL, non-Hodgkin lymphoma; M, male; F, female; DLBCL, diffuse large B-cell lymphoma; PTL, post-transplantation lymphoproliferative B-cell NHL lymphoma.

This figure approximates the actual costs of a PET/CT scan in the United States [11].

results

HD patients

All 37 baseline PET/CTs (100%) in the HD patients were FDG positive (mean SUV max 10.6, range 4.0–29.9). In 31 of 38 HD patients (82%) intPET showed CR. PET/CT after completion of first-line treatment (endPET) confirmed CR in all of these patients (Fig. 4). In seven HD patients (18%) intPET showed PR (mean SUV max 4.3, range 1.8–6.8) followed by CR in three, PR in three (mean SUV max 2.5, range 1.9–2.5) and PD (SUV max 8.9) in one patient. Results of the HD group are summarized in Figure 1.

NHL patients

All 23 baseline PET/CTs in the NHL patients were FDG positive (mean SUV max 16.5, range 5.4–40.0). In 22 of 30 NHL patients (73%) intPET showed CR and endPET was negative in all of these patients. None of these patient progressed until the end of therapy. In the remaining eight NHL patients seven (20%) showed PR on intPET (mean SUV max 3.6, range 2.6–6.5) followed by CR in five, by PR in one (SUV max 3.2) and PD (SUV max 12.7) in another patient. One patient had stable disease at intPET (SUV max 6.1) and CR at endPET. Results of the NHL group are summarized in Figure 2.

Eleven of 68 patients who were in CR on intPET still had remaining soft-tissue abnormalities on the corresponding CT.

In three patients therapy was changed because of the findings in the intPET; one patient with a vaginal B lymphoma showed stable disease on inPET after four cycles of chemotherapy so that the chemotherapy was stopped and radiotherapy was carried out. The PET/CT scan after the end of radiotherapy showed a complete remission (CR). In one patient with DLBCL of the mediastinum intPET showed partial remission (PR) after four cycles of R-CHOP and chemotherapy was stopped and radiation therapy was carried out showing CR at the end of treatment. The last of the three patients with mediastinal Hodgkin’s lymphoma showed CR after two cycles of ABVD so that six cycles were completed but additionally planned radiotherapy was omitted

because of the inPET findings. PET/CT after end of treatments showed again CR.

cost calculation

One hundred and ninety-six PET/CT’s were carried out in our study population. Fifty-three endPET’s were carried out in complete interim responders. Overall costs for 196 18F-FDG–PET/CT scans (60 basPET’s, 68 intPET’s, 68 endPET’s) in our population were calculated with 372 400 US dollars. In our study population, an overall diagnostic imaging cost reduction of 27.0% or 102 600 US dollars could have been achieved by omitting 53 end of treatment FDG–PET/CT’s in the interim complete responders.

discussion

In contradiction to the current recommendations [8, 10], our results indicate that PET/CT after end of treatment is unnecessary in HD and DLBCL patients if intPET shows a complete remission and the clinical course is uncomplicated. In our study population, an overall diagnostic imaging cost reduction of 27% could have been achieved by omitting end of treatment FDG-PET/CT in interim complete responders.

Because many lymphoma types are reliably FDG positive, some authors recommend a baseline PET/CT only for lymphoma types where the FDG avidity is less predictable such as marginal-zone lymphoma, mantle cell lymphoma or follicular lymphoma [17]. Several studies confirmed that PET/CT is superior to other imaging methods such as CT or Gallium scintigraphy in the staging situation and provides a more accurate assessment of the stage of the disease [18–20]. Partridge et al. [21] reported a stage and therapy change of 25% in Hodgkin’s patients with baseline PET compared with baseline CT. A disadvantage of a missing baseline investigation is that the interpretation of an interim scan can be very difficult and the categorization into progressive, stable disease or PR according to the established criteria may be even impossible if the baseline SUV max of the lesions is not available.

The assessment of therapy remission is one of the most challenging aspects in lymphoma patients. Morphological imaging modalities such as CT and magnetic resonance imaging

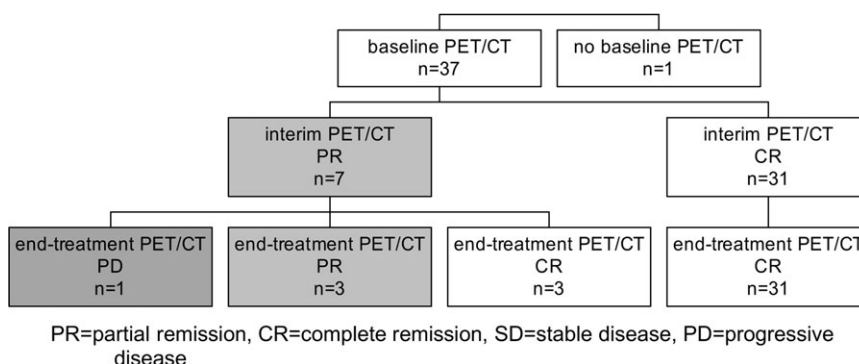


Figure 1. Results of therapy assessment with (PET/CT) in 38 HD patients. Positron emission tomography/computed tomography.

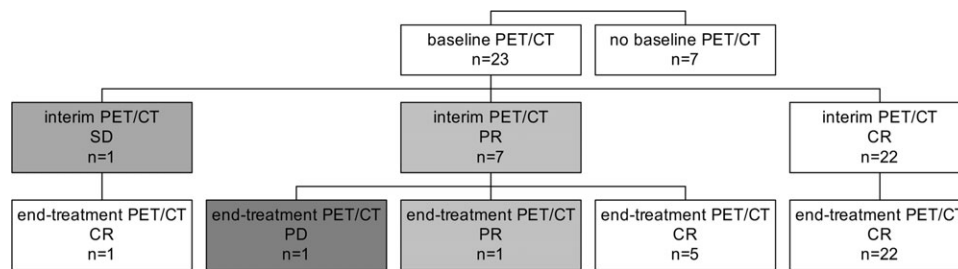


Figure 2. Results of therapy assessment with positron emission tomography/computed tomography (PET/CT) in 30 NHL patients. Positron emission tomography/computed tomography; SD, stable disease; PR, partial remission; CR, complete remission; PD, progressive disease.

fail to predict the clinical outcome after therapy in lymphoma patients [22, 23]. 18F-FDG–PET/CT has been established quickly after introducing into clinical practice in staging and therapy monitoring in lymphoma patients [5–7]. The main goal of first-line treatment in lymphoma patients is to obtain a CR, because a CR is associated with a better clinical outcome [1]. A negative FDG–PET alone after first-line treatment is associated with a better progression-free survival (PFS) and overall survival. Jerusalem et al. [24] evaluated a mixed population of 54 HD and DLBCL patients and found a 1-year PFS of 0% for patients with a PET-positive lesion versus 86% for patients with CR at the end of therapy. Thirty-one (82%) of 38 HD patients in our study showed CR in intPET and all remained FDG negative in end-treatment PET/CT. In our NHL group, 22 of 30 patients (73.3%) had CR at intPET and all of them also had a negative end-treatment PET/CT. In other words, at the end of first-line treatment we had no progress in all interim complete responders. Our results are supported by findings of other studies. Hutchings et al. investigated 85 patients with HD after two or three cycles of chemotherapy. In 63 patients intPET was negative. In 27 of these 63 patients an endPET was carried out which was negative in 25 patients and positive at site of previous disease in two patients. None of the 27 intPET-negative patients relapsed (median follow-up 3.3 years), although two endPET's were positive [25]. Hutchings et al. also investigated 121 DLBCL patients. In 50 patients intPET was negative. In 19 of these patients an endPET was carried out, which was negative in every case. Interestingly, in the 31 patients without endPET there was a higher rate of progression (four patients = 13%) than in the intPET-negative and endPET-negative patients (one patient = 5%) [26]. Haioun et al. [27] investigated 90 patients with aggressive lymphoma and reported that none of the 54 'early-PET' negative patients became positive after four cycles. Spaepen et al. investigated 70 patients with aggressive DLBCL. They had 37 patients with a negative midtreatment PET reported. All of these patients had negative PET's after completion of first-line therapy. Thirty-one of these patients had a durable complete remission and, five patients relapsed after a median of 365 days. One patient had a negative PET after end of treatment but never achieved a CR because of persistence lymphoma in the bone marrow [28]. Kostakoglu et al. [29] reported that an interim FDG–PET after one cycle of chemotherapy correlates better with the outcome than scans after completion of chemotherapy. These data indicate that the interim FDG–PET scan provides more prognostic information

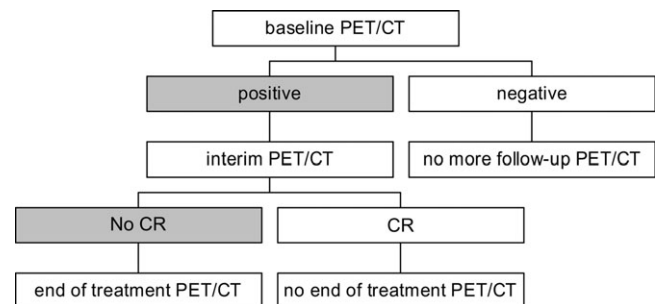


Figure 3. Proposed simplified algorithm for effective use of 2-[fluorine-18]fluoro-2-deoxy-D-glucose–positron emission tomography/computed tomography (FDG–PET/CT) in therapy assessment of lymphoma patients. CR, complete remission.

than the FDG–PET after end of treatment. Results from outcome studies, where therapy is changed in patients with PET-positive interim scans, are still not available. Thus, the IHP group recommends that intPET should only be done in clinical trials. We observed in our study population that PET/CT findings of intPET changed therapy in three patients; in two patients additional radiotherapy was carried out because of persistent FDG-uptake in intPET and in one patient radiotherapy was omitted because of complete remission in intPET. Since this study was conducted retrospectively, no definitive conclusions can be drawn regarding the influence of PET/CT on therapy management in these patients. According to other authors, we believe that PET/CT clearly has the potential to influence the lymphoma therapy [30].

From this data the question arises, whether it is necessary to carry out an end of treatment scan in interim complete responders or if these costs can be spared. From a psychological point of view, it might be understandable that the patient and treating oncologist want to document the successful treatment at the end of the therapy with imaging but in our opinion, this argument is not strong enough to justify a costly investigation with additional radiation exposure in patients already at risk for second tumors. It has also to be taken into account that every PET/CT imaging has the risk of producing misleading PET-positive findings such as thymus rebound, infections or uptake in brown fat all of which can be misinterpreted as a disease recurrence [31–33].

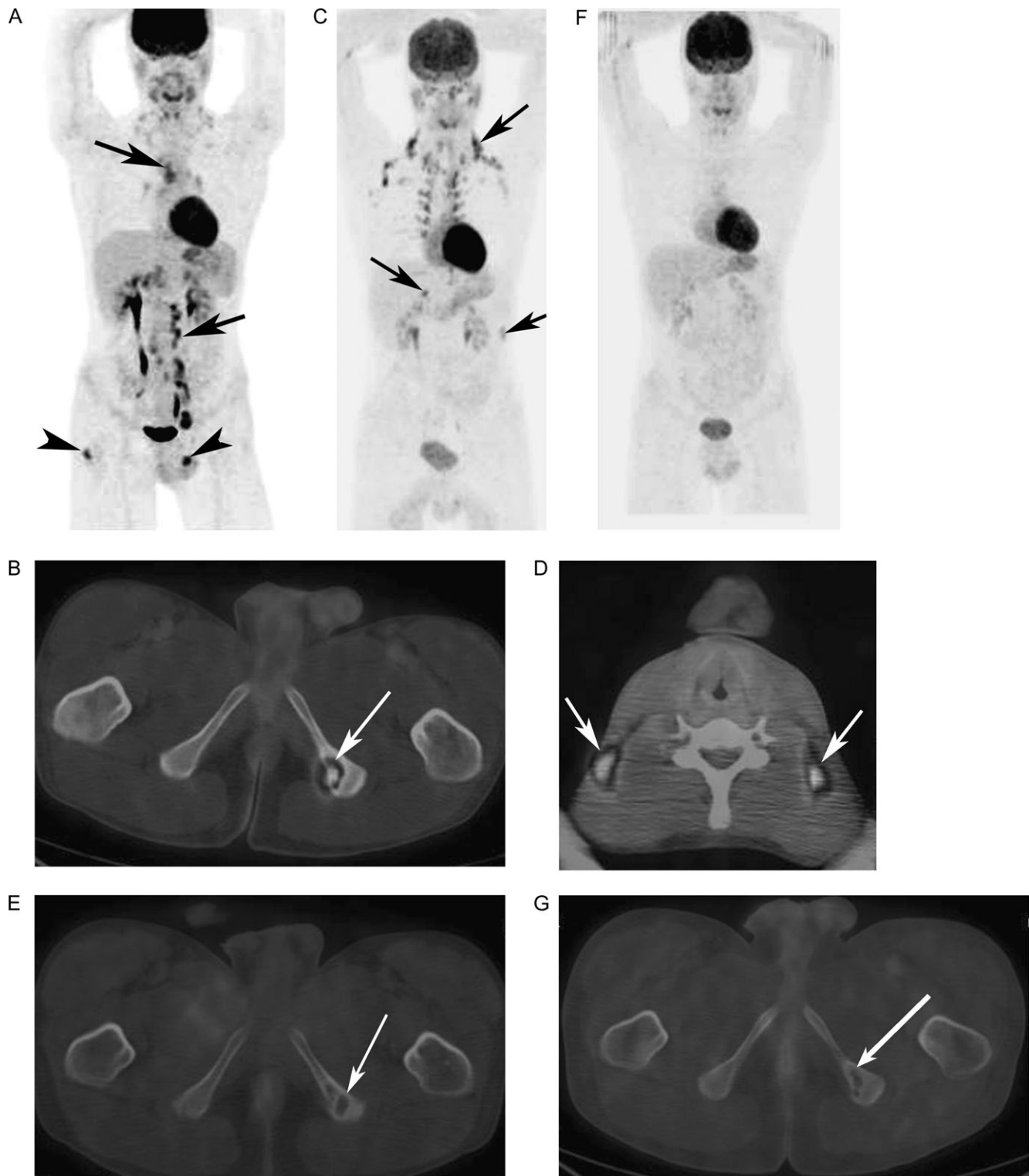


Figure 4. A 17-year-old patient with histologically proven Hodgkin's disease (HD). Coronal maximum intensity projection (MIP) image (a) of the baseline positron emission tomography/computed tomography (PET/CT) before therapy showing supradiaphragmatic (upper arrow) and infradiaphragmatic (lower arrow) lymph node involvement. Additionally, multifocal bone involvement (arrowheads) is observed. Axia-fused PET/CT image (b) showing one focal FDG-active osteolytic lesion in the left ischiac bone (arrow). Stage IV lymphoma was diagnosed. Interim PET/CT after three cycles of chemotherapy [adriamycin, bleomycin, vinblastin and dacarbazine (ABVD)] showing complete disappearance of pathologic FDG uptake but increased uptake in the brown fatty tissue in the cervical, supraclavicular (c, MIP image, upper arrow), mediastinal and abdominal region (lower arrow). Axial PET/CT image (d) demonstrating that the FDG uptake is localized in the supraclavicular brown fatty tissue (arrows) and not in cervical lymph nodes. The bone lesion (e, arrow) shows no FDG uptake anymore. Complete remission was diagnosed. PET/CT after end of treatment (eight cycles ABVD) showing disappearance of all pathologic FDG uptakes (f, g arrow) as well as complete restitution of FDG uptake in the brown fatty tissue consistent with persistent complete remission.

Our finding, therefore, do not support the work by Spaepen et al. [8] who proposed an algorithm for the implementation of FDG–PET in the management of lymphoma patients where they recommended an endPET in patients with negative intPET. Spaepen et al. even recommended follow-up scans in complete responders with DLBCL independent of the initial stage and in HD patients stage III and IV. In patients with HD stage I/II and CR they recommended no follow-up scans. Recently published recommendations of the IHP group state, “PET should be routinely used for remission assessment at the conclusion of therapy in patients with HD and DLBCL” [9]. There might still be the rare situation of a very early progress between inPET and endPET in complete interim responders although neither in our study population nor in one of the studies mentioned above such a case was described. In our experience these patients develop clinical symptoms such as night sweats, palpable masses or increasing lactate dehydrogenase, and thus restaging with PET/CT in this situation is strongly recommended.

We have summarized our approach cost-effective use of FDG–PET/CT in patients with HD and NHL in a simplified algorithm (Figure 3).

In conclusion, our data indicates that PET/CT after end of treatment is superfluous if intPET shows CR. Therefore, a substantial cost reduction might be achieved by omitting end of treatment FDG–PET/CT in interim complete responders.

acknowledgement

The authors thank our guest Victor Kalff for his help to prepare the manuscript.

references

- Coiffier B, Lepage E, Briere J et al. CHOP chemotherapy plus rituximab compared with CHOP alone in elderly patients with diffuse large-B-cell lymphoma. *N Engl J Med* 2002; 346: 235–242.
- Knight C, Hind D, Brewer N, Abbott V. Rituximab (MabThera) for aggressive non-Hodgkin's lymphoma: systematic review and economic evaluation. *Health Technol Assess* 2004; 8:iii, ix–xi, 1–82.
- Schaefer NG, Hany TF, Taverna C et al. Non-Hodgkin lymphoma and Hodgkin disease: coregistered FDG PET and CT at staging and restaging—do we need contrast-enhanced CT? *Radiology* 2004; 232: 823–829.
- Newman JS, Francis IR, Kaminski MS, Wahl RL. Imaging of lymphoma with PET with 2-[F-18]-fluoro-2-deoxy-D-glucose: correlation with CT. *Radiology* 1994; 190: 111–116.
- Hicks RJ, Mac Manus MP, Seymour JF. Initial staging of lymphoma with positron emission tomography and computed tomography. *Semin Nucl Med* 2005; 35: 165–175.
- Raanani P, Shasha Y, Perry C et al. Is CT scan still necessary for staging in Hodgkin and non-Hodgkin lymphoma patients in the PET/CT era? *Ann Oncol* 2006; 17: 117–122.
- Jerusalem G, Hustinx R, Beguin Y, Fillet G. Evaluation of therapy for lymphoma. *Semin Nucl Med* 2005; 35: 186–196.
- Spaepen K, Stroobants S, Verhoef G, Mortelmans L. Positron emission tomography with [(18)F]FDG for therapy remission monitoring in lymphoma patients. *Eur J Nucl Med Mol Imaging* 2003; 30 (Suppl 1): S97–105.
- Juweid ME, Stroobants S, Hoekstra OS et al. Use of Positron Emission Tomography for Response Assessment of Lymphoma: Consensus of the Imaging Subcommittee of International Harmonization Project in Lymphoma. *J Clin Oncol* 2007.
- Juweid ME, Wiseman GA, Vose JM et al. Response assessment of aggressive non-Hodgkin's lymphoma by integrated International Workshop Criteria and fluorine-18-fluorodeoxyglucose positron emission tomography. *J Clin Oncol* 2005; 23: 4652–4661.
- Berger M, Gould MK, Barnett PG. The cost of positron emission tomography in six United States Veterans Affairs hospitals and two academic medical centers. *Am J Roentgenol* 2003; 181: 359–365.
- Brix G, Lechel U, Glatting G et al. Radiation exposure of patients undergoing whole-body dual-modality 18F-FDG PET/CT examinations. *J Nucl Med* 2005; 46: 608–613.
- Heinrich S, Goerres GW, Schafer M et al. Positron emission tomography/computed tomography influences on the management of resectable pancreatic cancer and its cost-effectiveness. *Ann Surg* 2005; 242: 235–243.
- Valk PE, Abella-Columa E, Haseman MK et al. Whole-body PET imaging with [18F]fluorodeoxyglucose in management of recurrent colorectal cancer. *Arch Surg* 1999; 134:503–511; Discussion 511–503.
- Klose T, Leidl R, Buchmann I, Brambs HJ, Reske SN. Primary staging of lymphomas: cost-effectiveness of FDG-PET versus computed tomography. *Eur J Nucl Med* 2000; 27: 1457–1464.
- Young H, Baum R, Cremerius U et al. Measurement of clinical and subclinical tumour remission using [18F]-fluorodeoxyglucose and positron emission tomography: review and 1999 EORTC recommendations. European Organization for Research and Treatment of Cancer (EORTC) PET Study Group. *Eur J Cancer* 1999; 35: 1773–1782.
- Guermazi A, Juweid ME. Commentary: PET poised to alter the current paradigm for remission assessment of non-Hodgkin's lymphoma. *Br J Radiol* 2006; 79: 365–367.
- la Fougere C, Hundt W, Brockel N et al. Value of PET/CT versus PET and CT performed as separate investigations in patients with Hodgkin's disease and non-Hodgkin's lymphoma. *Eur J Nucl Med Mol Imaging* 2006.
- Kostakoglu L, Leonard JP, Kuji I et al. Comparison of fluorine-18 fluorodeoxyglucose positron emission tomography and Ga-67 scintigraphy in evaluation of lymphoma. *Cancer* 2002; 94: 879–888.
- Schaefer NG, Strobel K, Taverna C, Hany TF. Bone involvement in patients with lymphoma: the role of FDG-PET/CT. *Eur J Nucl Med Mol Imaging* 2006.
- Partridge S, Timothy A, O'Doherty MJ et al. 2-Fluorine-18-fluoro-2-deoxy-D-glucose positron emission tomography in the pretreatment staging of Hodgkin's disease: influence on patient management in a single institution. *Ann Oncol* 2000; 11: 1273–1279.
- Hill M, Cunningham D, MacVicar D et al. Role of magnetic resonance imaging in predicting relapse in residual masses after treatment of lymphoma. *J Clin Oncol* 1993; 11: 2273–2278.
- Mikhaeel NG, Timothy AR, O'Doherty MJ et al. 18-FDG-PET as a prognostic indicator in the treatment of aggressive Non-Hodgkin's Lymphoma-comparison with CT. *Leuk Lymphoma* 2000; 39: 543–553.
- Jerusalem G, Beguin Y, Fassotte MF, et al. Whole-body positron emission tomography using 18F-fluorodeoxyglucose for posttreatment evaluation in Hodgkin's disease and non-Hodgkin's lymphoma has higher diagnostic and prognostic value than classical computed tomography scan imaging. *Blood* 1999; 94: 429–433.
- Hutchings M, Mikhaeel NG, Fields PA et al. Prognostic value of interim FDG-PET after two or three cycles of chemotherapy in Hodgkin lymphoma. *Ann Oncol* 2005; 16: 1160–1168.
- Mikhaeel NG, Hutchings M, Fields PA et al. FDG-PET after two to three cycles of chemotherapy predicts progression-free and overall survival in high-grade non-Hodgkin lymphoma. *Ann Oncol* 2005; 16: 1514–1523.
- Haioun C, Itti E, Rahmouni A et al. [18F]fluoro-2-deoxy-D-glucose positron emission tomography (FDG-PET) in aggressive lymphoma: an early prognostic tool for predicting patient outcome. *Blood* 2005; 106: 1376–1381.

28. Spaepen K, Stroobants S, Dupont P et al. Early restaging positron emission tomography with (18)F-fluorodeoxyglucose predicts outcome in patients with aggressive non-Hodgkin's lymphoma. *Ann Oncol* 2002; 13: 1356–1363.
29. Kostakoglu L, Coleman M, Leonard JP et al. PET predicts prognosis after 1 cycle of chemotherapy in aggressive lymphoma and Hodgkin's disease. *J Nucl Med* 2002; 43: 1018–1027.
30. Juweid ME, Cheson BD. Positron-emission tomography and assessment of cancer therapy. *N Engl J Med* 2006; 354: 496–507.
31. Brink I, Reinhardt MJ, Hoegerle S et al. Increased activity in the thymus gland studied with 18F-FDG PET: age dependency and frequency after chemotherapy. *J Nucl Med* 2001; 42: 591–595.
32. Castellucci P, Nanni C, Farsad M, et al. Potential pitfalls of 18F-FDG PET in a large series of patients treated for malignant lymphoma: prevalence and scan interpretation. *Nucl Med Commun* 2005; 26: 689–694.
33. Sandherr M, von Schilling C, Link T et al. Pitfalls in imaging Hodgkin's disease with computed tomography and positron emission tomography using fluorine-18-fluorodeoxyglucose. *Ann Oncol* 2001; 12: 719–722.