

An optical coherence tomography study of a biodegradable vs. durable polymer-coated limus-eluting stent: a LEADERS trial sub-study

Peter Barlis^{1,2}, Evelyn Regar², Patrick W. Serruys², Konstantinos Dimopoulos^{1,3}, Willem J. van der Giessen², Robert-Jan M. van Geuns², Giuseppe Ferrante¹, Simon Wandel⁴, Stephan Windecker^{4,5}, Gerrit-Anne van Es⁶, Pedro Eerdmans⁷, Peter Jüni^{4,8}, and Carlo di Mario^{1,3*}

¹Royal Brompton Hospital, Sydney Street, London SW3 6NP, UK; ²Thoraxcenter, Erasmus Medical Center, Rotterdam, The Netherlands; ³National Heart and Lung Institute, Imperial College, London, UK; ⁴CTU Bern, Bern University Hospital, Bern, Switzerland; ⁵Bern University Hospital, Bern, Switzerland; ⁶Cardialys BV, Rotterdam, The Netherlands; ⁷Biosensors Europe SA, Morges, Switzerland; and ⁸Institute of Social and Preventive Medicine, University of Bern, Switzerland

Received 4 February 2009; revised 9 October 2009; accepted 14 October 2009; online publish-ahead-of-print 4 November 2009

See page 139 for the editorial comment on this article (doi:10.1093/eurheartj/ehp481)

Aims

Incomplete endothelialization has been found to be associated with late stent thrombosis, a rare but devastating phenomenon, more frequent after drug-eluting stent implantation. Optical coherence tomography (OCT) has 10 times greater resolution than intravascular ultrasound and thus appears to be a valuable modality for the assessment of stent strut coverage. The LEADERS trial was a multi-centre, randomized comparison of a biolimus-eluting stent (BES) with biodegradable polymer with a sirolimus-eluting stent (SES) using a durable polymer. This study sought to evaluate tissue coverage and apposition of stents using OCT in a group of patients from the randomized LEADERS trial.

Methods and results

Fifty-six consecutive patients underwent OCT during angiographic follow-up at 9 months. OCT images were acquired using a non-occlusive technique at a pullback speed of 3 mm/s. Data were analysed using a Bayesian hierarchical random-effects model, which accounted for the correlation of lesion characteristics within patients and implicitly assigned analytical weights to each lesion depending on the number of struts observed per lesion. Primary outcome was the difference in percentage of uncovered struts between BESs and SESs. Twenty patients were included in the analysis in the BES group (29 lesions with 4592 struts) and 26 patients in the SES group (35 lesions with 6476 struts). A total of 83 struts were uncovered in the BES group and 407 out of 6476 struts were uncovered in the SES group [weighted difference -1.4% , 95% confidence interval (CI) -3.7 to 0.0 , $P = 0.04$]. Results were similar after adjustment for pre-procedure lesion length, reference vessel diameter, number of implanted study stents, and presence of stent overlap. There were three lesions in the BES group and 15 lesions in the SES group that had $\geq 5\%$ of all struts uncovered (difference -33.1% , 95% CI -61.7 to -10.3 , $P < 0.01$).

Conclusion

Strut coverage at an average follow-up of 9 months appears to be more complete in patients allocated to BESs when compared with SESs. The impact of this difference on clinical outcome and, in particular, on the risk of late stent thrombosis is yet to be determined.

Keywords

Optical coherence tomography • Stent thrombosis • Biodegradable polymer • Drug-eluting stents

* Corresponding author. Tel: +44 20 7352 8121, Fax: +44 20 7351 8473, Email: c.dimario@rbht.nhs.uk

Published on behalf of the European Society of Cardiology. All rights reserved. © The Author 2009. For permissions please email: journals.permissions@oxfordjournals.org.

Introduction

Until recently, trials comparing drug-eluting stents (DESs) and bare metal stents (BMSs) used intravascular ultrasound (IVUS) to confirm that DESs reduce restenosis and intimal proliferation.^{1–5} However, the thin layer of neointima observed after implantation of DESs is often below the 100 μm axial resolution of IVUS. Incomplete stent strut endothelialization has recently received attention with studies suggesting an association with the long-term risk of stent thrombosis,⁶ but it cannot be detected by IVUS. Optical coherence tomography (OCT) has 10 times greater resolution than IVUS and thus appears to be an improved imaging modality for the assessment of tissue coverage of DESs. Observational data using OCT in first-generation sirolimus-eluting stents suggest that stent struts may still remain uncovered 2 years after implantation.⁷ Evidence of a small but clear increase of late stent thrombosis has led to the increase in the duration of dual anti-platelet therapy beyond the customary 3–6-month period of the initial DES trials,^{8,9} with 1 year now recommended by the AHA/ACC/SCAI guidelines,¹⁰ mainly based on theoretical reasoning, without robust studies supporting this recommendation.

The LEADERS (Limus Eluted from A Durable vs. ERodable Stent coating) study was a multi-centre, randomized non-inferiority trial comparing a biolimus-eluting stent (BES) using a biodegradable polymer with a widely used sirolimus-eluting stent (SES) with a durable polymer. At 9 months, BESs were non-inferior to SESs for the primary composite endpoint of cardiac death, myocardial infarction (MI), or clinically indicated target vessel revascularization (TVR).¹¹ Frequency of cardiac death, MI, and clinically indicated TVR were similar for both stent types (composite endpoint of 9.1% for BESs, 9.9% for SESs, $P = 0.59$). In the angiographic sub-study, BESs were non-inferior to SESs in in-stent percentage diameter stenosis at 9-month follow-up with an in-stent restenosis rate of 5.5 vs. 8.7% ($P = 0.20$), respectively.¹¹

Durable polymer surface coatings may be one of the causes for incomplete endothelialization of first-generation DESs. The BES uses biodegradable polylactic acid, which is co-released with biolimus during 6–9 months and degrades into carbon dioxide and water. Since the stainless steel surface of the BES used in the LEADERS trial is free of additional primer permanent polymer coating (e.g. parylene that is present in the currently available Biomatrix stent; Biosensors, Singapore), only the metal stent backbone remains *in situ* once the polymer has degraded. A second feature distinguishing BESs and SESs is that the coating is only abluminal, possibly favouring endothelialization of the stent. In a sub-study of the LEADERS trial, we therefore set out to compare tissue coverage and apposition between BESs and SESs using OCT. The primary endpoint was the difference in percentage of uncovered struts between BESs and SESs.

Methods

The design of the LEADERS study has been published elsewhere.¹¹ The study applied an 'all-comers' approach including patients aged 18 years or more with chronic stable coronary artery disease or acute coronary syndromes, including non-ST-elevation and ST-elevation MI. There was no limit for the number of treated lesions, vessels, or lesion length, and no

patients were excluded on the basis of co-morbid disorders or age, apart from the following pre-specified criteria: known allergy to acetylsalicylic acid, clopidogrel, heparin, stainless steel, sirolimus, biolimus, or contrast material; planned surgery within 6 months of percutaneous coronary intervention (PCI) unless the dual anti-platelet therapy could be maintained throughout the peri-surgical period; pregnancy; participation in another trial before reaching the primary endpoint; and inability to provide informed consent. All patients were discharged on acetylsalicylic acid of at least 75 mg daily indefinitely and clopidogrel 75 mg daily for at least 12 months. The study complied with the Declaration of Helsinki and was approved by all institutional ethics committees. The trial is registered with ClinicalTrials.gov, number NCT00389220. All patients provided written informed consent for participation in this trial.

Randomization was done centrally after diagnostic coronary angiography and before PCI by use of a telephone allocation service. Patients were randomly allocated on a one-to-one basis to treatment with BESs (BioMatrix Flex, Biosensors, Inc., Newport Beach, CA, USA) or SESs (Cypher SELECT, Cordis, Miami Lakes, FL, USA), and to active angiographic follow-up at 9 months or clinical follow-up only on a 1:3 basis using a factorial design. The OCT sub-study was performed at two of the 10 LEADERS sites (Royal Brompton Hospital, London, UK, $n = 12$, and Thoraxcenter, Erasmus Medical Center, Rotterdam, the Netherlands, $n = 34$). Randomized patients were eligible if they underwent follow-up angiography. Exclusion criteria specific to follow-up with OCT imaging were renal impairment (serum creatinine ≥ 200 $\mu\text{mol/L}$) and left ventricular ejection fraction $< 30\%$. The OCT sub-study was approved by the trial steering committee and local institutional review boards.

Optical coherence tomography

For the purpose of this study, OCT was performed at follow-up only using the M3 system (LightLab Imaging, Westford, MS, USA) at 20 frames per second allowing retrieval of the imaging core at 3 mm/s for 30 s (90 mm) with a non-occlusive imaging technique,¹² following administration of intravenous heparin and intracoronary nitrates. A standard guide wire was advanced distally in the target vessel. A single lumen (e.g. Transit, Cordis, Johnson & Johnson, Miami, FL, USA or ProGreat, Terumo Co., Tokyo, Japan) or a double lumen catheter (0.023" TwinPass, Vascular Solutions, Inc., Minneapolis, MN, USA) was then advanced distal to the previously stented region. Following withdrawal of the guide wire, the optical ImageWire (LightLab Imaging, Westford, MS, USA) was passed through the catheter and OCT imaging commenced at a pullback of 3.0 mm/s, during flush of 2–4 mL/s of iso-osmolar contrast (Iodixanol 320, VisipaqueTM, GE Health Care, Cork, Ireland) through the guiding catheter to replace blood flow and permit visualization of the stented segment and intima–lumen interface. Scanning was prematurely terminated if there was any haemodynamic instability, arrhythmia, or patient intolerance. If the stented segment was too long to be safely imaged in a single pullback, image acquisition was stopped and re-commenced from the same position during a second contrast injection. Anatomic landmarks such as side branches, calcifications, or stent overlap segments were used for longitudinal view orientation.

Offline OCT data analysis was undertaken by an independent core laboratory (Cardialysis BV, Rotterdam, the Netherlands) blinded to stent-type allocation and clinical and procedural characteristics of the patients. Analysis of contiguous cross-sections at 1 mm longitudinal intervals within the stented segment was performed using proprietary software (LightLab Imaging, Westford, MA, USA). Intra- and inter-observer reliability were evaluated in previous studies and found to be > 0.95 ,^{13–15} as could be expected in view of the clear visualization of intimal tissue and struts allowed by OCT. Recently, Barlis et al.¹⁶

demonstrated a low intra- and inter-observer variability when assessing OCT strut tissue coverage at follow-up (reproducibility coefficient of 26.7 and 24.1 μm and intraclass correlation coefficient of 99.4 and 99.6%, respectively).

Metallic stent struts typically appear as bright, signal-intense structures with dorsal shadowing. The number of stent struts was determined in each cross-section. Stent coverage was classified as not visible/incomplete when there were points of the stent struts with no visible tissue coverage or as complete when tissue was seen overlying the strut. Thickness (μm) of the tissue coverage on the luminal side of each strut was measured at the middle of the long axis of the strut. A linear measurement line was drawn from the endoluminal leading edge perpendicular to the long axis of the strut towards the luminal leading edge of the strut. Struts were classified as apposed (when the strut was in contact with the vessel wall) or malapposed if protruding into the lumen at a distance greater than the strut thickness (154 μm for the SES and 112 μm for the BES).

For malapposed struts, the presence of tissue was qualitatively assessed also on the abluminal surface to confirm circumferential coverage.

Sample size calculation and statistical analysis

The OCT sub-study was a superiority study. To estimate differences between BESs and SESs, we used a Bayesian hierarchical random-effects model based on Markov chain Monte Carlo simulation methods with vague priors.¹⁷ The model included random-effects at the level of

lesions and patients, fully accounting for the correlation of lesion characteristics within patients and their variation between patients and implicitly assigning analytical weights to each lesion depending on the number of struts observed per lesion. The pre-specified primary endpoint of the sub-study was the difference in percentage of uncovered struts between BESs and SESs. Assuming average numbers of 1.5 lesions per patients, 160 struts per lesion, and a design factor of 1.5 (defined as the standard error derived from the Bayesian hierarchical random-effects model assuming clustering of lesions within patients divided by the crude standard error derived from conventional analysis assuming independency of lesions), we estimated that the inclusion of 22 patients per group would yield greater than 90% power to detect a difference in uncovered struts of 4% between BESs and SESs at a two-sided type I error of 0.05. Secondary endpoints were the differences in percentage of malapposed struts and in percentage of malapposed and uncovered struts. After logarithmic transformation of the data, we also estimated the difference between groups in neointimal thickness. Then, we determined differences in the percentage of lesions with any struts with unfavourable outcome, with at least 5%, and with at least 10% of struts with unfavourable outcome, with unfavourable outcomes defined in accordance with definitions used for primary and secondary endpoints. In view of the baseline imbalance in the proportion of lesions located in small vessels, we performed a *post hoc* sensitivity analysis of the primary endpoint restricted to small vessels only.

Differences between groups were estimated from the median of the posterior distribution of the 50 001–100 000 iterations, with the initial 50 000 iterations discarded as 'burn-in'. We derived the 95% confidence interval (95% CI) from the 2.5th and 97.5th percentiles of the posterior

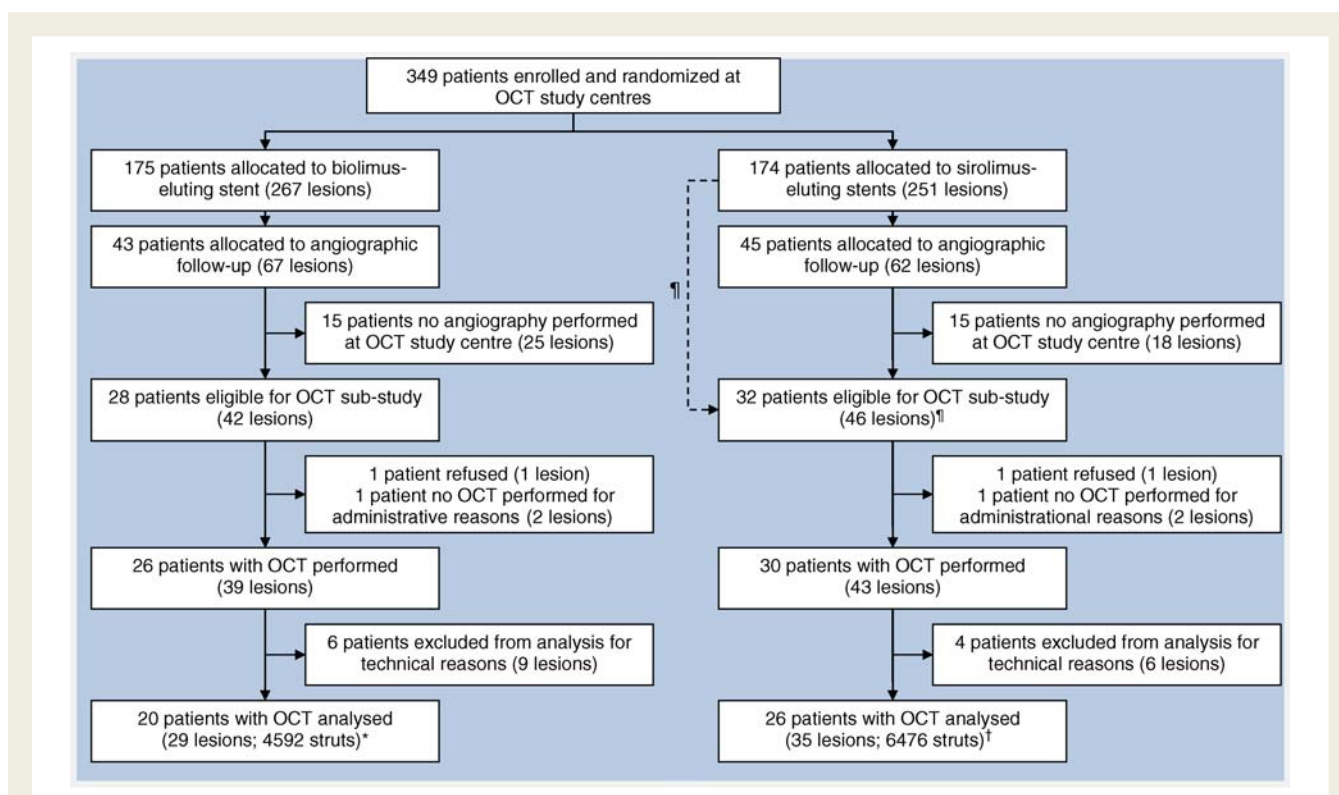


Figure 1 Trial profile. [†]Two patients allocated to sirolimus-eluting stents and clinical follow-up only (two lesions) had a clinically indicated angiography and underwent optical coherence tomography; ^{*}One patient allocated to biolimus-eluting stents (two lesions) had one lesion excluded from the analysis for technical reasons; [†]Two patients allocated to sirolimus-eluting stents (four lesions) had one lesion excluded each from the analysis for technical reasons.

distribution, also calculating two-sided *P*-values from the posterior distribution. 95% CI and *P*-values from posterior distributions can be interpreted similarly to the conventional 95% CI and *P*-values. Sensitivity analyses were adjusted for pre-procedure lesion length, reference vessel diameter, number of implanted study stents, and presence of stent overlap. Finally, we restricted the analysis of the primary endpoint to patients with analysable OCT data who had been randomly allocated to angiographic follow-up. Baseline characteristics of lesions, procedural results, and angiographic follow-up data were analysed as previously described,⁸ using mixed maximum-likelihood logistic and linear

regression models that allowed for correlation of more than one lesion within patients. Statistical analyses were performed using WinBUGS version 1.4.3 (Imperial College and MRC, UK) and Stata, version 10.0 (StataCorp, College Station, TX, USA).

Results

Figure 1 shows the profile of the OCT sub-study. Twenty-eight patients allocated to BESs and 32 patients allocated to SESs

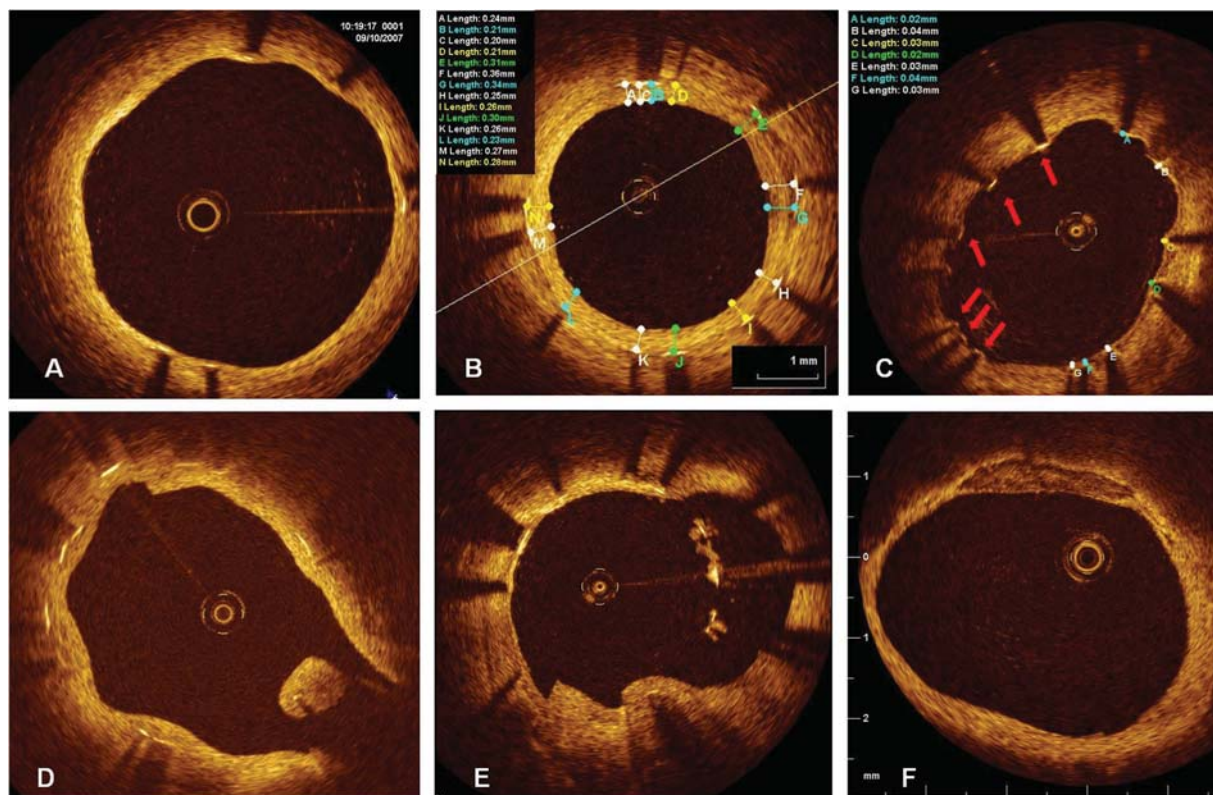


Figure 2 Examples of optical coherence tomography findings. (A) This 73-year-old male received a biolimus-eluting stent 9 months prior to the right coronary artery. The stent is seen covered by a thin, uniform layer of tissue overlying all stent struts that are well apposed to the vessel wall. (B) Offline optical coherence tomography analysis. A total of 14 stent struts are visible in this cross-section with the observer having measured the thickness of tissue overlying each of the struts, expressed in the coloured panel (top left) in mm. The mean neointimal thickness in this frame was 0.27 mm (270 μ m). (C) Sirolimus-eluting stent struts are observed circumferentially. Struts between 7 and 11 o'clock are apposed but uncovered by tissue. Struts from 1 to 5 o'clock are observed covered with a very thin layer of tissue (mean thickness 0.03 mm or 30 μ m). The stent was implanted in a patient who received two sirolimus-eluting stents to the mid-left anterior descending artery 9 months prior following a presentation with a non-ST-elevation myocardial infarction. He was asymptomatic at 9-month follow-up. (D) Nine-month follow-up of a biolimus-eluting stent implanted in the left anterior descending artery across the diagonal bifurcation. A solitary strut is observed (arrow) malapposed at the level of the carina. The strut was seen covered by a thick, uniform and homogenous tissue. (E) This optical coherence tomography pullback frame from a 78-year-old male with prior stenting to the left anterior descending artery/diagonal bifurcation with a sirolimus-eluting stent. Struts are observed (1–3 o'clock) to be malapposed to the vessel wall with a heterogeneous tissue with different signal attenuations that may represent thrombotic material. The patient was asymptomatic at 9-month follow-up and on dual antiplatelet therapy. (F) Left main coronary artery optical coherence tomography. This patient had a proximal left anterior descending stent implanted 9 months prior. We extended the pullback beyond the stent into the left main coronary artery which demonstrates a well-demarcated, non-flow limiting, low-attenuation plaque (12 o'clock) consistent with calcium. Our sub-study exclusively used a non-occlusive technique for optical coherence tomography imaging that requires pullback of the image wire during simultaneous flush of contrast via the guiding catheter. This is a significant advance over the traditional method of optical coherence tomography imaging in which a proximally positioned balloon is inflated during image acquisition. Hence, ostial and proximal segments of coronary arteries were all able to be imaged, thereby supporting the 'all-comer' design of the LEADERS trial without any optical coherence tomography anatomical exclusions.

were eligible for the sub-study, and 26 and 30 patients, respectively, underwent OCT, all undertaken using the non-occlusive technique. Figure 2 presents some examples of the spectrum of OCT findings observed. Six patients in the BES and four patients in the SES group were excluded from the analysis because of low quality of OCT images. Twenty patients were included in the analysis in the BES group (29 lesions with 4592 struts) and 26 patients in the SES group (35 lesions with 6476 struts).

Baseline clinical and angiographic characteristics of the 46 patients are presented in Tables 1 and 2. Characteristics were similar in both groups, except for differences in the percentage of patients with small-vessel disease and in reference vessel and minimal lumen diameter at lesion level. In addition, more patients had a history of hypercholesterolemia in the SES group, even though overall cholesterol levels were comparable between groups (4.31 mmol/L in the BES vs. 4.17 mmol/L in the SES group, difference -0.13 , 95% CI -0.90 to 0.63 , $P = 0.73$). The left anterior descending (LAD) artery and the right coronary artery (RCA) were the most frequently imaged vessels (Table 2). Procedural results were similar between

groups, with a trend towards smaller minimal lumen diameters in-stent in patients allocated to SESs (Table 3). Control angiography was performed at a median of 9.1 months (interquartile range 9.0–9.3 months). Table 4 presents results of angiographic follow-up, which were similar between groups and compatible with results of the main trial.⁸

Optical coherence tomography analysis

Figure 3 shows a graphical representation of stent strut coverage in lesions. Table 5 (top) presents results of the principal analysis of the primary endpoint. A total of 83 out of 4592 struts in 29 lesions were uncovered in the BES group (weighted estimate 0.6%, 95% CI 0.2–1.6) and 407 out of 6476 struts in 35 lesions were uncovered in the SES group (2.1%, 95% CI 0.9–4.4), with a weighted difference between groups of -1.4% (95% CI -3.7 to 0.0 , $P = 0.04$). Results were similar after adjustment for pre-procedure lesion length, reference vessel diameter, number of implanted study stents, and presence of stent overlap (difference -2.0% , 95% CI -5.7 to -0.1 , Table 6). None of the 41 struts

Table 1 Baseline characteristics of patients

	Biolimus-eluting stent (n = 20)	Sirolimus-eluting stent (n = 26)	P-value
Age (years)	64.9 (10.2)	63.0 (11.4)	0.56
Males	14 (70.0%)	18 (69.2%)	0.61
Diabetes mellitus	4 (20.0%)	5 (19.2%)	1.00
Diabetes requiring insulin	2 (10.0%)	1 (3.9%)	0.40
Hypertension	10 (50.0%)	17 (65.4%)	0.37
Hypercholesterolaemia	9 (45.0%)	20 (76.9%)	0.04
Current smoker	5 (25.0%)	10 (38.5%)	0.37
Family history of CAD	11 (55.0%)	17 (65.4%)	0.55
History of MI	5 (25.0%)	9 (34.6%)	0.54
History of PCI	3 (15.0%)	6 (32.1%)	0.71
With drug-eluting stents	2 (10.0%)	1 (3.9%)	0.57
Previous CABG	1 (5.0%)	4 (15.4%)	0.37
Stable angina pectoris	12 (60.0%)	16 (61.5%)	1.00
Acute coronary syndrome	8 (40.0%)	10 (38.5%)	0.48
Unstable angina	1 (5.0%)	4 (15.4%)	
Non-ST-elevation MI	2 (10.0%)	2 (7.7%)	
ST-elevation MI	5 (25.0%)	4 (15.4%)	
Multi-vessel disease	5 (25.0%)	3 (11.5%)	0.27
Small-vessel disease (RVD < 2.75 mm)	8 (40.0%)	21 (80.8%)	<0.01
Study lesions per patient			0.89
One	12 (60.0%)	17 (65.4%)	
Two	7 (35.0%)	7 (26.9%)	
Three	0 (0.0%)	2 (7.7%)	
Four or more	1 (5.0%)	0 (0.0%)	
De novo lesions only	18 (90.0%)	25 (96.2%)	0.57
Long lesions (>20 mm)	7 (35.0%)	13 (50.0%)	0.38
Number of lesions per patient	1.5 (0.8)	1.4 (0.6)	0.71
Off-label use	14 (70.0%)	23 (88.5%)	0.15

Data are mean (SD) or number (%). P-values are from t-test for continuous and from Fisher's test for categorical data. CAD, coronary artery disease; PCI, percutaneous coronary intervention; CABG, coronary artery bypass grafting; MI, myocardial infarction; RVD, reference vessel diameter.

Table 2 Baseline characteristics of lesions

	Biolimus-eluting stent	Sirolimus-eluting stent	P-value
Target lesion coronary artery			0.18
Left main	0/29 (0.0%)	0/35 (0.0%)	
Left anterior descending	15/29 (51.7%)	12/35 (34.3%)	
Left circumflex	3/29 (10.3%)	10/35 (28.6%)	
Right	11/29 (37.9%)	13/35 (37.1%)	
Bypass graft	0/29 (0.0%)	0/35 (0.0%)	
De novo lesions	27/29 (93.1%)	34/35 (97.1%)	0.45
Lesion length (mm)			
Assessed ^a	14.3 (14.5)	13.3 (9.1)	0.80
Assessed or estimated ^b	17.3 (14.7)	20.9 (19.0)	0.41
Reference vessel diameter (mm) ^b	2.7 (0.6)	2.4 (0.5)	0.02
Minimal lumen diameter (mm) ^c	0.93 (0.60)	0.63 (0.53)	0.04
Stenosis (% lumen diameter) ^c	66.9 (20.3)	73.4 (21.0)	0.20
Total occlusion	5/28 (17.9%)	9/34 (26.5%)	0.42
Severe calcification	3/29 (10.3%)	3/33 (9.1%)	0.87
Pre-procedure TIMI flow			0.35
Grade 1	5/28 (17.9%)	9/34 (26.5%)	
Grade 2	1/28 (3.6%)	3/34 (8.8%)	
Grade 3	1/28 (3.6%)	4/34 (11.8%)	
Grade 4	21/28 (75.0%)	18/34 (52.9%)	

Data are mean (SD) or number of lesions/number assessed (%). Assessments were not possible in all 64 lesions with angiographic assessments and therefore the number of lesions differs according to outcome. *P*-values are from mixed maximum-likelihood models, which allowed for the correlation of more than one lesion within patients, except for *P*-values referring to target lesion coronary artery and pre-procedure TIMI flow, which are from Fisher's exact test. TIMI, thrombolysis in myocardial infarction.

^aTwenty-one lesions assessed in the biolimus-eluting stent group and 22 in the sirolimus-eluting stent group.

^bTwenty-nine lesions assessed in the biolimus-eluting stent group and 35 in the sirolimus-eluting stent group.

^cTwenty-seven lesions assessed in the biolimus-eluting stent group and 34 in the sirolimus-eluting stent group.

located in areas with stent overlap were uncovered in the BES group and six out of 235 struts in the SES group. Twelve lesions in the BES group (41.4%) and 25 lesions in the SES group (71.4%) were located in small vessels, with 24 out of 2207 struts uncovered in BESs (weighted estimate 0.5%, 95% CI 0.1–2.0) and 343 out of 4402 struts in SESs (weighted estimate 2.4%, 95% CI 0.9–5.4). When restricting the analysis to these lesions, we found differences somewhat more pronounced (weighted difference –1.8%, 95% CI –4.9 to 0.1, *P* = 0.064). There were two and eight lesions with ≥10% uncovered struts in the BES and SES groups, respectively (difference –10.2%, 95% CI –30.9 to 1.3, *P* = 0.08), 3 and 15 lesions with ≥5% uncovered struts (difference –33.1%, 95% CI –61.7 to –10.3, *P* < 0.01), and 17 and 24 lesions with any uncovered struts (difference –11.1%, 95% CI –44.8 to 19.7, *P* = 0.48).

A total of 28 and 86 struts were malapposed in the BES and SES groups, respectively (difference –0.2%, 95% CI –0.8 to 0.2, *P* = 0.19). Results were similar in adjusted analyses (difference –0.3%, 95% CI –0.6 to 0.0, *P* = 0.08, Table 6). A total of 0 and 1 lesions had ≥10% malapposed struts in the BES and SES groups, respectively (difference –0.4%, 95% CI –7.6 to 0.0, *P* = 0.05), one and six lesions had ≥5% malapposed struts (difference –8.4%, 95% CI –25.5 to –0.1, *P* = 0.05), and 11 and 17 lesions had any malapposed struts (difference –13.7%, 95% CI –47.8 to 20.9, *P* = 0.42).

A total of 11 and 41 struts were both malapposed and uncovered in the BES and SES groups, respectively (difference –0.1%, 95% CI –0.4 to 0.0, *P* = 0.13). Results were similar in adjusted analyses (difference –0.2%, 95% CI –0.6 to 0.0, *P* = 0.08, Table 6). None of the lesions had ≥10% struts, which were both malapposed and uncovered, zero and two lesions had ≥5% (difference –5.1%, 95% CI –20.1 to 1.5, *P* = 0.12), and 6 and 14 lesions had any malapposed and uncovered struts (difference –21.0%, 95% CI –48.7 to 5.9, *P* = 0.12).

Figure 4 presents the distribution of neointimal thickness across all struts. In 67% of all struts, tissue thickness was below 100 μm, the resolution of IVUS. The average tissue thickness was 67.6 μm (95% CI 56.0–81.7 μm) in the BES and 57.1 μm (95% CI 48.4–67.6 μm) in the SES group (*P* = 0.19).

Safety of optical coherence tomography

Mean contrast volume used for coronary flushing was 37.4 mL (SD 12.3). There were no cases of contrast-induced nephropathy. In one patient, contrast flushing during OCT imaging induced ventricular fibrillation. Sinus rhythm was promptly restored following external cardioversion. Deep guide catheter intubation during contrast injection was thought to have caused the arrhythmia. The patient made an uneventful recovery and was discharged as planned the following day.

Table 3 Procedural results

	Biolimus-eluting stent	Sirolimus-eluting stent	Difference	
			Estimate (95% CI)	P-value
No. of study stents per lesion ^a	1.4 (0.7)	1.7 (0.9)	-0.3 (-0.7 to 0.1)	0.18
Maximal stent diameter per lesion (mm) ^a	3.1 (0.4)	2.9 (0.5)	0.2 (-0.1 to 0.4)	0.17
Total stent length per lesion (mm) ^a	26.7 (18.6)	33.5 (24.3)	-5.7 (-19.4 to 7.0)	0.38
Direct stenting	15/29 (51.7%)	14/35 (40.0%)	11.7 (-10.9 to 34.4)	0.31
Implantation of study stent	29/29 (100.0%)	35/35 (100.0%)	0 (n/e)	1.00
Device success	29/29 (100.0%)	35/35 (100.0%)	0 (n/e)	1.00
Lesion success	29/29 (100.0%)	35/35 (100.0%)	0 (n/e)	1.00
Minimal lumen diameter (mm) ^a				
In-stent	2.40 (0.47)	2.22 (0.43)	0.18 (-0.05 to 0.40)	0.13
In-segment	2.06 (0.55)	1.95 (0.45)	0.09 (-0.17 to 0.35)	0.49
Diameter stenosis (%) ^a				
In-stent	13.13 (6.37)	15.18 (6.97)	-2.12 (-5.74 to 1.50)	0.25
In-segment	23.24 (8.27)	22.90 (7.70)	0.64 (-3.54 to 4.83)	0.76
Acute gain (mm) ^b				
In-stent	1.50 (0.57)	1.58 (0.45)	-0.05 (-0.36 to 0.25)	0.73
In-segment	1.15 (0.63)	1.31 (0.44)	-0.17 (-0.50 to 0.15)	0.30

Data are mean (SD) or number of lesions/number assessed (%), unless otherwise stated. Mixed maximum-likelihood models were used for comparisons between groups to account for the correlation of multiple lesions within patients. n/e, CI for difference in percentages could not be estimated.

^aTwenty-nine lesions assessed in the biolimus-eluting stent group and 35 in the sirolimus-eluting stent group.

^bTwenty-seven lesions assessed in the biolimus-eluting stent group and 34 in the sirolimus-eluting stent group.

Discussion

The LEADERS trial is the first, large, multi-centre randomized study to incorporate an OCT sub-study to help address the issue of tissue coverage following DES implantation. Quantitative coronary angiography and IVUS lack the spatial resolution to accurately quantify tissue coverage. Hence, OCT, with a resolution of approximately 15 μm , is ideal for the purpose of comparing the presence and extent of tissue coverage in the two stents studied.

The SES was the first DES to be introduced and is covered by two layers of durable polymer with a top coating for slow drug release. The availability of up to 8 years clinical follow-up after SES implantation and evidence of greater efficacy in reducing restenosis and late lumen loss in direct or indirect comparison with other DESs^{9,18–20} have made SESs the current gold standard of treatment. Pathological follow-up examinations at autopsy following implantation of an SES have shown that neointimal healing is still incomplete after 16 months,²¹ a specific problem that may prolong the period of thrombotic risk. Struts directly exposed to the blood flow may be surrogates for thrombotic risk given that pathological studies have identified a lack of tissue healing in cases of stent thrombosis.^{6,22} Furthermore, exposed struts, particularly if malapposed, are also likely to result in flow disturbance that can be pro-thrombotic.^{23,24}

The polymer coating as a system for drug delivery has been implicated as being pro-inflammatory and retard healing and coverage.²² A number of OCT results after implantation of DESs have been reported^{13,14,25–27} Takano *et al.*^{7,14} undertook OCT examination at 3 months and 2 years following SES implantation in 21 patients. The

thickness of tissue at 2 years was greater than that at 3 months (71 \pm 93 vs. 29 \pm 41 μm , respectively; $P < 0.001$). Frequency of struts with no visible coverage was lower in the 2-year group compared to the 3-month group (5 vs. 15%, respectively; $P < 0.001$), with a prevalence of patients with uncovered struts between 3 months and 2 years falling from 95 to 81%, respectively. Matsumoto *et al.*¹³ examined 57 SESs in 34 patients at 6 months after implantation and found the median tissue thickness to be 52.5 μm with 89% of struts covered and 11% exposed. These studies are limited by the small sample size and by the fact the population consisted almost exclusively of single short SES because of the limitations of the balloon occlusive technique used for OCT image acquisition.

Recently, results from a randomized trial of OCT in long lesions requiring overlap stenting were presented.²⁶ In 22 patients receiving SESs, 6% of all struts had no visible coverage at 6-month follow-up. In our study, 407 out of 6476 struts were uncovered among patients allocated to SESs, which corresponds to approximately 6% in a naive analysis ignoring the clustered nature of the data. Accounting for the nature of the data in a Bayesian hierarchical random-effects model yields a lower estimate of 2.1% in this study, which suggests that the type of analysis has dramatic effects not only on the precision of estimates, but also on their estimated magnitude.

We exclusively used a non-occlusive method to acquire OCT images performed during contrast flush via the guiding catheter with no requirement for the cumbersome occlusion balloon method used in all the other published studies. This ensured that the broad 'all-comer' inclusion criteria for the LEADERS trial

Table 4 Angiographic follow-up results

	Biolimus-eluting stent	Sirolimus-eluting stent	Difference	
			Estimate (95% CI)	P-value
Reference vessel diameter (mm) ^a	2.84 (0.44)	2.60 (0.57)	0.23 (−0.05 to 0.52)	0.11
Minimal lumen diameter (mm)				
In-stent	2.24 (0.69)	2.03 (0.57)	0.19 (−0.15 to 0.53)	0.27
In-segment	2.01 (0.63)	1.83 (0.54)	0.15 (−0.17 to 0.47)	0.37
Diameter stenosis (%) ^b				
In-stent	21.54 (19.51)	21.89 (13.56)	−0.10 (−9.21 to 9.01)	0.98
In-segment	27.85 (17.87)	27.55 (12.33)	0.69 (−7.61 to 8.99)	0.87
Late loss (mm) ^b				
In-stent	0.16 (0.41)	0.18 (0.39)	0.00 (−0.22 to 0.22)	0.99
In-segment	0.06 (0.35)	0.09 (0.36)	−0.03 (−0.22 to 0.16)	0.77
Binary restenosis ^b				
In-stent	2/29 (6.9%)	1/33 (3.0%)	3.9 (−7.1 to 14.9)	0.49
In-segment	2/29 (6.9%)	2/33 (6.1%)	0.8 (−11.4 to 13.1)	0.89

Data are mean (SD) or number of lesions/number assessed (%). Angiographic assessments were not possible in all lesions, therefore the number of lesions differs according to outcome. Mixed maximum-likelihood models were used for comparisons between groups to account for the correlation of multiple lesions within patients. 95% CI and P-values are two-sided, from superiority testing. Twenty-nine lesions were assessed in the biolimus-eluting stent group and 35 in the sirolimus-eluting stent group unless indicated otherwise.

^aTwenty-eight lesions assessed in the biolimus-eluting stent group and 33 in the sirolimus-eluting stent group.

^bTwenty-nine lesions assessed in the biolimus-eluting stent group and 33 in the sirolimus-eluting stent group.

were reproduced in the OCT sub-study in which ostial, proximal, and multi-vessel stenting were all imaged by OCT.

The OCT results of our study in all comers with great lesion complexity confirms previous studies by showing that only a small percentage of SES struts are not covered with tissue 9 months after SES implantation. Still, only a minority of lesions after SES implantation had full lesion coverage at 9 months and half the lesions treated had less than 95% tissue coverage. The absence of longitudinal studies correlating intimal coverage of DESs and late stent thrombosis is the main limitation of this and other OCT studies at this stage. Although OCT has a high resolution permitting clear visualization of the tissue surrounding stent struts, we can only hypothesize as to its exact composition, particularly around unapposed struts. With its homogenous, highly reflective appearance, it is likely in keeping with neointimal proliferation (especially at 9-month follow-up) rather than fibrin or unendothelialized tissue that typically has a heterogeneous appearance.

Contemporary DES technologies are now geared towards eliminating the potential causes of poor tissue coverage and hence, to develop a stent that has similar anti-proliferative properties to the first-generation SES but with the added advantage of no or a lower risk of late stent thrombosis. The low incidence of stent thrombosis with first-generation DESs also means that comparison studies need thousands of patients and several years of follow-up to show differences in clinical outcome and this makes any surrogate end-point valuable.

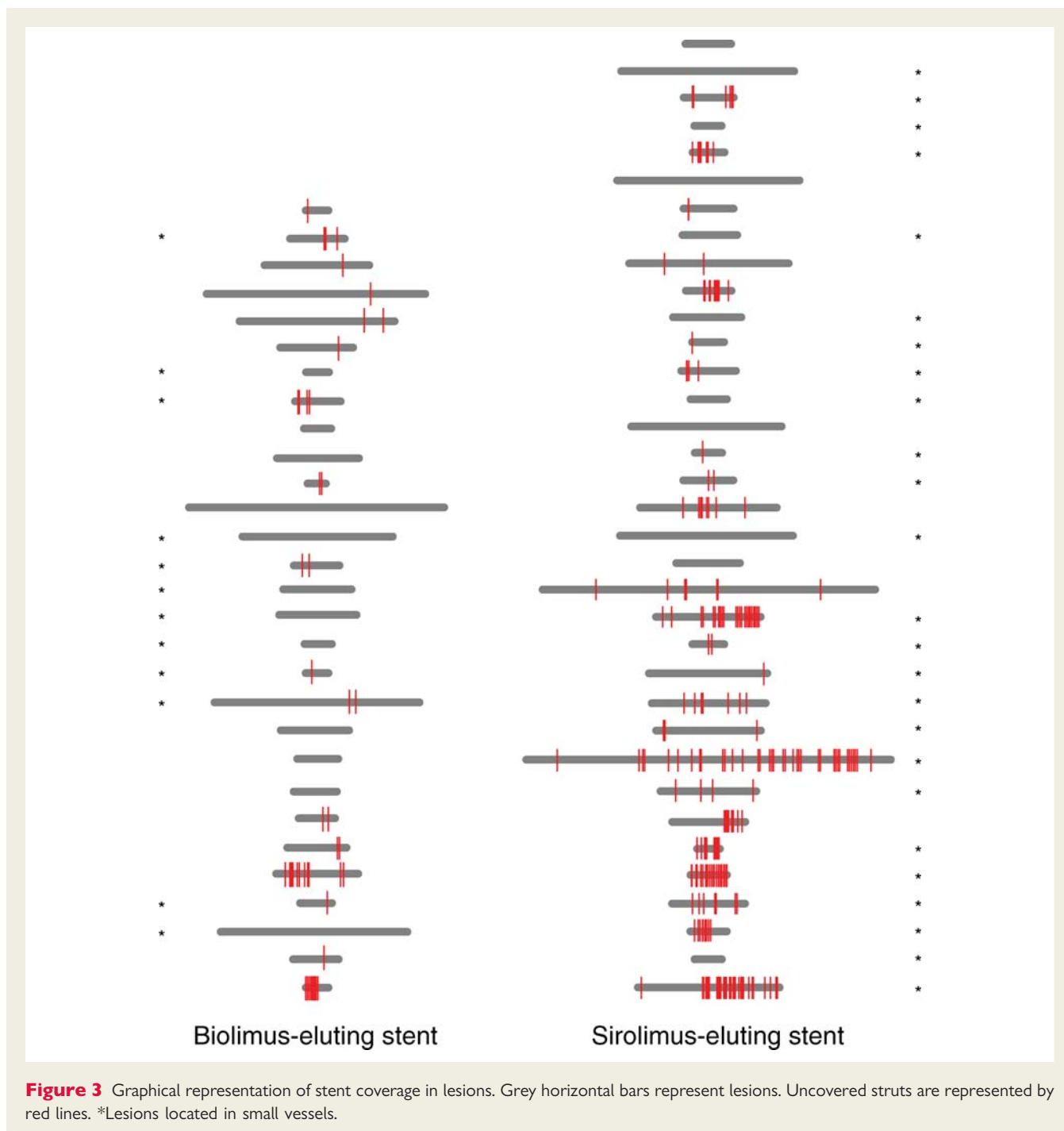
The BES did not differ from the SES in the quantity of tissue overlying the stent struts (67.6 μ m compared with 57.1 μ m for the SES, $P = 0.19$), suggesting similar efficacy in preventing restenosis to

SESs, as confirmed by the results of the main study.⁸ The BES contained fewer exposed stent struts, which translated into more than 95% of the stents showing near-complete coverage vs. less than two-thirds in the SES group. These results suggest that better tissue coverage may be achieved with the BES compared with the SES.

The presence of abluminal coating and the biodegradable polymer is not the only reason that possibly explained this difference. The better apposition observed at 9-month follow-up can be explained by fewer instances of late acquired malapposition due to the absence of hypersensitivity reaction against the biodegradable polymer. It may also reflect a better initial apposition immediately after stent implantation, allowed by the thinner more pliable struts and different stent design. A previous study using OCT immediately following SESs or paclitaxel-eluting stents (PESs; Taxus, Boston Scientific, Natick, USA) implantation found a significantly higher proportion of SES struts to be malapposed compared with the PES.²⁸ This is likely, in part, to be due to the closed cell design and the thicker strut profile of the SES.²⁸

Study limitations

The presence or absence of neointimal coverage is limited by the resolution of OCT and struts reported as bare could have a very thin covering of tissue (<10 μ m), although the biological protection offered by such a thin coverage is debatable.²⁹ Furthermore, the number of patients included was small, enrolled only in two centres, and differences in patient and lesion characteristics may have clouded our conclusions despite the randomized nature of the trial and the robustness of results to adjusting for lesion characteristics.



The choice of a 9-month OCT examination was empiric and in line with the follow-up arm of the main LEADERS trial. An earlier OCT assessment may have helped to assess the rapidity of tissue coverage, while a later examination may have offered more relevant information for the process of very late (>1 year) stent thrombosis. A recent OCT follow-up study with SESs confirmed the presence of ongoing uncovered stent struts even at 2 years follow-up, indicating that failure of early tissue coverage might become a permanent observation.⁷ OCT was not carried out immediately following stent implantation so that the mechanism

of malapposition of struts cannot be accurately determined so that we are unable to distinguish persisting or late acquired malapposition.

Only one autopsy study convincingly linked stent coverage and thrombosis.⁶ This study did not offer a cut-off percentage of uncovered struts associated with stent thrombosis and focused on the prevalence of uncovered struts in individual cross-sections (information we also convey in Figure 3). The division into three classes with complete (100%) and 95 and 90% coverage is arbitrary but corresponds to pre-specified definitions of secondary

Table 5 Results of principal analyses

	Percentage (95% CI)		Difference in percentage	
	Biolimus-eluting stent	Sirolimus-eluting stent	Estimate (95% CI)	P-value
Uncovered struts	0.6 (0.2–1.6)	2.1 (0.9–4.4)	–1.4 (–3.7 to 0.0)	0.04
Lesions with				
At least 10% uncovered struts	2.2 (0.2–12.1)	13.3 (3.4–33.5)	–10.2 (–30.9 to 1.3)	0.08
At least 5% uncovered struts	3.8 (0.4–16.9)	38.3 (16.4–65.5)	–33.1 (–61.7 to –10.3)	<0.01
Any uncovered struts	63.3 (35.2–86.4)	74.9 (51.7–91.8)	–11.1 (–44.8 to 19.7)	0.48
Malapposed struts	0.2 (0.1–0.5)	0.4 (0.2–1.0)	–0.2 (–0.8 to 0.2)	0.19
Lesions with				
At least 10% malapposed struts	0.0 (0.0–0.3)	0.5 (0.0–7.6)	–0.4 (–7.6 to 0.0)	0.05
At least 5% malapposed struts	0.9 (0.0–8.2)	10.0 (2.2–27.2)	–8.4 (–25.5 to –0.1)	0.05
Any malapposed struts	33.5 (12.3–60.1)	47.8 (24.0–72.4)	–13.7 (–47.8 to 20.9)	0.42
Malapposed and uncovered struts	0.1 (0.0–0.2)	0.2 (0.1–0.5)	–0.1 (–0.4 to 0.0)	0.13
Lesions with				
At least 10% malapposed and uncovered struts	0.0 (0.0–0.1)	0.0 (0.0–0.1)	0.0 (0.0 to 0.1)	0.70
At least 5% malapposed and uncovered struts	0.8 (0.0–7.4)	6.5 (1.2–21.8)	–5.1 (–20.1 to 1.5)	0.12
Any malapposed and uncovered struts	12.9 (2.8–34.0)	35.5 (14.4–59.6)	–21.0 (–48.7 to 5.9)	0.12

Four thousand five hundred and eight struts in 29 lesions assessed in the biolimus-eluting stent group and 6083 struts in 35 lesions in the sirolimus-eluting stent group. 95% CI and P-values derived from Bayesian hierarchical models are two-sided, from superiority testing.

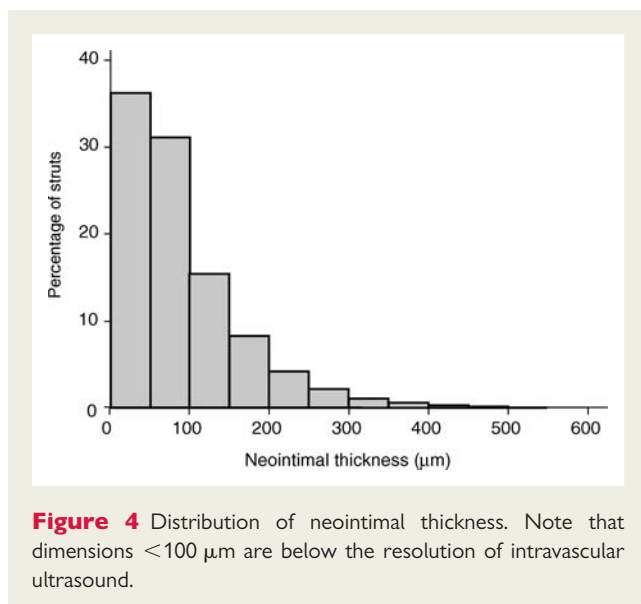
Table 6 Sensitivity analyses

	Percentage (95% CI)		Difference in percentage	
	Biolimus-eluting stent	Sirolimus-eluting stent	Estimate (95% CI)	P-value
Uncovered struts	0.7 (0.3 to 1.8)	2.7 (1.1 to 6.4)	–2.0 (–5.7 to –0.1)	0.04
Lesions with				
At least 10% uncovered struts	1.4 (0.1 to 10.6)	17.1 (3.4 to 45.1)	–14.7 (–43.3 to 0.0)	0.05
At least 5% uncovered struts	3.5 (0.3 to 18.1)	50.5 (20.1 to 80.2)	–45.5 (–76.9 to –14.3)	<0.01
Any uncovered struts	70.0 (37.8 to 91.2)	80.5 (53.3 to 94.8)	–9.5 (–44.9 to 22.8)	0.54
Malapposed struts	0.2 (0.1 to 0.5)	0.5 (0.2 to 1.3)	–0.3 (–0.6 to 0.0)	0.08
Lesions with				
At least 10% malapposed struts	n/e	n/e	n/e	n/e
At least 5% malapposed struts	0.3 (0.0 to 4.2)	6.7 (0.8 to 26.3)	–5.9 (–25.5 to –0.2)	0.04
Any malapposed struts	31.4 (9.2 to 64.2)	49.8 (20.1 to 78.7)	–16.9 (–56.5 to 24.6)	0.42
Malapposed and uncovered struts	0.1 (0.0 to 0.2)	0.3 (0.1 to 0.7)	–0.2 (–0.6 to 0.0)	0.08
Lesions with				
At least 10% malapposed and uncovered struts	n/e	n/e	n/e	n/e
At least 5% malapposed and uncovered struts	0.2 (0.0 to 3.7)	4.3 (0.6 to 22.5)	–3.8 (–21.9 to 0.2)	0.06
Any malapposed and uncovered struts	12.3 (2.3 to 38.5)	37.8 (13.9 to 69.5)	–24.0 (–59.8 to 8.8)	0.14

Four thousand five hundred and eight struts in 29 lesions assessed in the biolimus-eluting stent group and 6083 struts in 35 lesions in the sirolimus-eluting stent group. 95% CI and P-values derived from Bayesian hierarchical model are two-sided, from superiority testing. All analyses are adjusted for pre-procedure lesion length, reference vessel diameter, number of implanted study stents, and presence of stent overlap. n/e, could not be estimated.

endpoints. Only prolonged follow-up and larger studies will answer the question of the appropriate cut-off to be used to identify patients at clinically relevant increased risk of stent thrombosis.

Multilevel analysis was used in this study as standard statistical approaches are inappropriate in data with significant clustering. In fact, even though more than 10 000 strut-related data points



were available, these were not independent observations: struts within the same lesion and lesions within the same patient are likely to be similar and a fundamental assumption of classic statistical tests would be violated if these tests were used to analyse strut-related data points. A large proportion of lesions in both groups had no or very few uncovered struts at all, and the Bayesian model allowed appropriate weighting of these lesions. Estimates will therefore be more conservative than estimates from naïve analyses comparing the proportion of uncovered struts between groups. Formal sample size calculations are difficult in this situation and no power calculation algorithm exists, which is based on generally accepted assumptions regarding intra-cluster correlation or design factors.

Conclusions

Strut coverage appears to be more complete in patients allocated to BESs as compared with SESs. The impact of this difference on clinical outcome and, in particular, on the risk of late stent thrombosis is yet to be determined.

Acknowledgements

We acknowledge Prof. Nicky Best, Department of Epidemiology, Imperial College, London, UK, for advice on the data analysis.

Funding

Biosensors Europe SA, Morges, Switzerland.

Conflict of interest: The hospitals (Royal Brompton Hospital, Erasmus Medical Center, and Bern University Hospital) and the core reference laboratory (Cardialysis BV) have received grants from Biosensors to run the LEADERS trial and the substudy presented. P.B., S.W., P.S. and C.D.M. have received speakers' fees from Biosensors. P.E. is a full-time employee of Biosensors.

References

- Serruys PW, Degertekin M, Tanabe K, Abizaid A, Sousa JE, Colombo A, Guagliumi G, Wijns W, Lindeboom WK, Ligthart J, de Feyter PJ, Morice MC. Intravascular ultrasound findings in the multicenter, randomized, double-blind RAVEL (RAnomized study with the sirolimus-eluting VELOCITY balloon-expandable stent in the treatment of patients with *de novo* native coronary artery lesions) trial. *Circulation* 2002;**106**:798–803.
- Degertekin M, Serruys PW, Foley DP, Tanabe K, Regar E, Vos J, Smits PC, van der Giessen WJ, van den Brand M, de Feyter P, Popma JJ. Persistent inhibition of neointimal hyperplasia after sirolimus-eluting stent implantation: long-term (up to 2 years) clinical, angiographic, and intravascular ultrasound follow-up. *Circulation* 2002;**106**:1610–1613.
- Sonoda S, Morino Y, Ako J, Terashima M, Hassan AH, Bonneau HN, Leon MB, Moses JW, Yock PG, Honda Y, Kuntz RE, Fitzgerald PJ. Impact of final stent dimensions on long-term results following sirolimus-eluting stent implantation: serial intravascular ultrasound analysis from the SIRIUS trial. *J Am Coll Cardiol* 2004;**43**:1959–1963.
- Weissman NJ, Koglin J, Cox DA, Hermiller J, O'Shaughnessy C, Mann JT, Turco M, Caputo R, Bergin P, Greenberg J, Kutcher M, Wong SC, Strickland W, Mooney M, Russell ME, Ellis SG, Stone GW. Polymer-based paclitaxel-eluting stents reduce in-stent neointimal tissue proliferation: a serial volumetric intravascular ultrasound analysis from the TAXUS-IV trial. *J Am Coll Cardiol* 2005;**45**:1201–1205.
- Park SJ, Shim WH, Ho DS, Raizner AE, Park SW, Hong MK, Lee CW, Choi D, Jang Y, Lam R, Weissman NJ, Mintz GS. A paclitaxel-eluting stent for the prevention of coronary restenosis. *N Engl J Med* 2003;**348**:1537–1545.
- Finn AV, Joner M, Nakazawa G, Kolodgie F, Newell J, John MC, Gold HK, Virmani R. Pathological correlates of late drug-eluting stent thrombosis: strut coverage as a marker of endothelialization. *Circulation* 2007;**115**:2435–2441.
- Takano M, Yamamoto M, Inami S, Murakami D, Seimiya K, Ohba T, Seino Y, Mizuno K. Long-term follow-up evaluation after sirolimus-eluting stent implantation by optical coherence tomography: do uncovered struts persist? *J Am Coll Cardiol* 2008;**51**:968–969.
- Stettler C, Allemann S, Wandel S, Kastrati A, Morice MC, Schomig A, Pfisterer ME, Stone GW, Leon MB, de Lezo JS, Goy JJ, Park SJ, Sabate M, Suttrop MJ, Kelbaek H, Spaulding C, Menichelli M, Vermeersch P, Dirksen MT, Cervinka P, De Carlo M, Erglis A, Chechi T, Ortolani P, Schali MJ, Diem P, Meier B, Windecker S, Jüni P. Drug-eluting and bare metal stents in people with and without diabetes: collaborative network meta-analysis. *Br Med J* 2008;**337**:a1331.
- Stettler C, Wandel S, Allemann S, Kastrati A, Morice MC, Schomig A, Pfisterer ME, Stone GW, Leon MB, de Lezo JS, Goy JJ, Park SJ, Sabate M, Suttrop MJ, Kelbaek H, Spaulding C, Menichelli M, Vermeersch P, Dirksen MT, Cervinka P, Petronio AS, Nordmann AJ, Diem P, Meier B, Zwahlen M, Reichenbach S, Trelle S, Windecker S, Jüni P. Outcomes associated with drug-eluting and bare-metal stents: a collaborative network meta-analysis. *Lancet* 2007;**370**:937–948.
- King SB III, Smith SC Jr, Hirshfeld JW Jr, Jacobs AK, Morrison DA, Williams DO, Feldman TE, Kern MJ, O'Neill WW, Schaff HV, Whitlow PL, Adams CD, Anderson JL, Buller CE, Creager MA, Ettinger SM, Halperin JL, Hunt SA, Krumholz HM, Kushner FG, Lytle BW, Nishimura R, Page RL, Riegel B, Tarkington LG, Yancy CW. 2007 focused update of the ACC/AHA/SCAI 2005 guideline update for percutaneous coronary intervention: a report of the American College of Cardiology/American Heart Association Task Force on Practice Guidelines. *J Am Coll Cardiol* 2008;**51**:172–209.
- Windecker S, Serruys PW, Wandel S, Buzman P, Trznadel S, Linke A, Lenk K, Ischinger T, Klauss V, Eberli F, Corti R, Wijns W, Morice MC, di Mario C, Davies S, van Geuns R-JM, Eerdmans P, van Es G-A, Meier B, Jüni P. Biolimus-eluting stent with biodegradable polymer versus sirolimus-eluting stent with durable polymer for coronary revascularisation (LEADERS): a randomised non-inferiority trial. *Lancet* 2008;**372**:1163–1173.
- Prati F, Cera M, Ramazzotti V, Imola F, Giudice R, Giudice M, Propriis SD, Albertucci M. From bench to bedside: a novel technique of acquiring OCT images. *Circ* 2008;**72**:839–843.
- Matsumoto D, Shite J, Shinke T, Otake H, Tanino Y, Ogasawara D, Sawada T, Paredes OL, Hirata K, Yokoyama M. Neointimal coverage of sirolimus-eluting stents at 6-month follow-up: evaluated by optical coherence tomography. *Eur Heart J* 2007;**28**:961–967.
- Takano M, Inami S, Jang IK, Yamamoto M, Murakami D, Seimiya K, Ohba T, Mizuno K. Evaluation by optical coherence tomography of neointimal coverage of sirolimus-eluting stent three months after implantation. *Am J Cardiol* 2007;**99**:1033–1038.
- Van Beusekom HM, Regar E, Peters I, van der Giessen WJ. Long-term effects of endovascular radiation after balloon angioplasty: assessment by OCT and histology. In: Regar E, van Leeuwen AMGJ, Serruys PW, eds. *Optical Coherence Tomography in Cardiovascular Research*. London: Informa Healthcare; 2007.

16. Barlis P, Dimopoulos K, Tanigawa J, Dzielicka E, Ferrante G, Del Furia F, di Mario C. Quantitative analysis of intracoronary optical coherence tomography measurements of stent strut apposition and tissue coverage. *Int J Cardiol* 2009; doi:S0167-5273(08)01379-X [pii] 10.1016/j.ijcard.2008.11.204.
17. Spiegelhalter DJ, Abrams KR, Myles JP. *Bayesian Approaches to Clinical Trials and Health Care Evaluation*. Chichester, UK: Wiley; 2004.
18. Dibra A, Kastrati A, Mehilli J, Pache J, Schuhlen H, von Beckerath N, Ulm K, Wessely R, Dirschinger J, Schomig A. Paclitaxel-eluting or sirolimus-eluting stents to prevent restenosis in diabetic patients. *N Engl J Med* 2005;**353**:663–670.
19. Kastrati A, Dibra A, Eberle S, Mehilli J, Suarez de Lezo J, Goy JJ, Ulm K, Schomig A. Sirolimus-eluting stents vs. paclitaxel-eluting stents in patients with coronary artery disease: meta-analysis of randomized trials. *J Am Med Assoc* 2005;**294**:819–825.
20. Windecker S, Remondino A, Eberli FR, Jüni P, Raber L, Wenaweser P, Togni M, Billinger M, Tuller D, Seiler C, Roffi M, Corti R, Sutsch G, Maier W, Luscher T, Hess OM, Egger M, Meier B. Sirolimus-eluting and paclitaxel-eluting stents for coronary revascularization. *N Engl J Med* 2005;**353**:653–662.
21. Guagliumi G, Farb A, Musumeci G, Valsecchi O, Tespili M, Motta T, Virmani R. Images in cardiovascular medicine. Sirolimus-eluting stent implanted in human coronary artery for 16 months: pathological findings. *Circulation* 2003;**107**:1340–1341.
22. Joner M, Finn AV, Farb A, Mont EK, Kolodgie FD, Ladich E, Kutys R, Skorija K, Gold HK, Virmani R. Pathology of drug-eluting stents in humans: delayed healing and late thrombotic risk. *J Am Coll Cardiol* 2006;**48**:193–202.
23. Davies PF, Spaan JA, Krams R. Shear stress biology of the endothelium. *Ann Biomed Eng* 2005;**33**:1714–1718.
24. Dewey CF Jr, Bussolari SR, Gimbrone MA Jr, Davies PF. The dynamic response of vascular endothelial cells to fluid shear stress. *J Biomech Eng* 1981;**103**:177–185.
25. Chen BX, Ma FY, Luo W, Ruan JH, Xie WL, Zhao XZ, Sun SH, Guo XM, Wang F, Tian T, Chu XW. Neointimal coverage of bare-metal and sirolimus-eluting stents evaluated with optical coherence tomography. *Heart* 2008;**94**:566–570.
26. Guagliumi G, Musumeci G, Sirbu V, Suzuki N, Biondi Zoccai G, Mihalcsik L, Matiashvili M, Trivisonno A, Lortkipanidze N, Fiocca L, Coletta J, Bezerra H, Valsecchi O, Costa M. A prospective, randomized, controlled study using optical coherence tomography to evaluate strut coverage of sirolimus-, paclitaxel-, and zotarolimus-eluting coronary stents in long lesions requiring overlapping. *Transcatheter Cardiovascular Therapeutics*. Cardiovascular Research Foundation, Washington; 2008.
27. Guagliumi G. *Long-term Strut Coverage of Paclitaxel-eluting Stents Compared with Bare-metal Stents Implanted during Primary PCI in Acute Myocardial Infarction: A Prospective, Randomized, Controlled Study Performed with Optical Coherence Tomography (HORIZONS-OCT)*. New Orleans: American Heart Association; 2008.
28. Tanigawa J, Barlis P, Dimopoulos K, Dalby M, Moore P, di Mario C. The influence of strut thickness and cell design on immediate apposition of drug-eluting stents assessed by optical coherence tomography. *Int J Cardiol* 2009;**134**:180–188.
29. Finn AV, Nakazawa G, Joner M, Kolodgie FD, Mont EK, Gold HK, Virmani R. Vascular responses to drug-eluting stents: importance of delayed healing. *Arterioscler Thromb Vasc Biol* 2007;**27**:1500–1510.