

R. Sutter
S. Renaud
L. Bonati
P. Lyrer
M. Tolnay
S. Wetzel
S. Rüegg
S. Engelter

Bilateral vertebral giant cell arteritis – favourable outcome in two cases

Received: 27 January 2007
Received in revised form: 24 March 2007
Accepted: 23 April 2007
Published online: 18 January 2008

Dear Sirs, giant cell arteritis (GCA) of the vertebral arteries (VA) is a rare, potentially treatable disease with serious prognosis. In a recent literature review [7], eight cases of bilateral VA-occlusion resulting from GCA were identified [1, 2, 7–9]. Six of these patients died. Both surviving patients were left dependent on assisted living [7]. We report on two patients with GCA of both VA with a favourable outcome.

Patient 1: A 75-year-old woman suffered from gait disturbance, vertigo, headache and jaw claudication. She lost 10 kilograms in two months. Neurological examination revealed gaze-evoked nystagmus, gait ataxia and pyramidal signs. Erythrocyte sedimentation rate (ESR) was 110 mm/h. The brain MRI showed bilateral cerebellar and left pontine infarction and an enhancement of the intracranial VA

after gadolinium (Fig. 1a, b). Sonology detected a halo around both VA (Fig. 1c). Biopsy of the temporal artery confirmed GCA (Fig. 1d). Her symptoms markedly improved after four days of high-dose IV-methylprednisolone treatment (1000 mg/d). The ESR decreased to 38 mm/h. On sonology, the stenoses regressed but the halos persisted.

Patient 2: A 81-year-old man had a syncope, headache, vertigo, blurred vision and jaw claudication. He lost 13 kilograms in two months. Bitemporal indurated and painful arteries were clinically prominent. The ESR was 90 mm/h. Sonology showed a halo around the temporal arteries and stenoses of the V4-segment (Fig. 1e). Contrast-enhancement of the VA walls was present on MRI (Fig. 1f). GCA was confirmed upon biopsy of the temporal artery (Fig. 1g, h). The symptoms resolved after five days of high-dose IV-methylprednisolone treatment (500 mg/d). The ESR decreased to 40 mm/h. Sonology showed regression of the vertebral stenoses.

Giant cell arteritis of the vertebral arteries is a rare cause of vertebrobasilar stenoses or occlusions. Eight cases of GCA-related bilateral VA-occlusions have been identified between 1966 and 2001, while another 110 cases of VA-occlusions were attributable to atherosclerosis [7]. The majority of GCA-patients with VA-occlusions died [3, 4, 6, 7]. The two patients reported here had a favourable outcome. In contrast to other cases reported with unfavourable courses [1, 2, 7–9], our patients had stenoses rather than occlusions. Although the degree of hemodynamic compromise may be crucial, one recently reported fatal case with VA-stenoses [3] illustrates that patients with stenoses only do not necessarily have a favourable outcome. It remains to be determined why in some patients VA-involvement

caused occlusions while in others the involvement was restricted to the level of stenoses. Other variables theoretically predicting an unfavourable outcome are (i) the involvement of the basilar artery, not directly affected by GCA [9], but resulting from bilateral VA occlusion, and (ii) the lack of sufficient collateralisation from the carotid circulation. It may be postulated that early high-dose immunosuppression is efficacious, as by observation several of the cases with fatal outcome had no immunosuppressive treatment [6, 7]. However in one case reported, even the addition of IV cyclophosphamide to high-dose IV steroids could not prevent the fatal outcome [3]. In another case, conversely, the delay of immunosuppressive treatment resulting from misinterpretation of imaging findings as VA-dissection [5] did not prompt an unfavourable course.

Systematic observation of GCA-patients with symptomatic stenooclusive disease of both VA is warranted to identify reliable outcome predictors. Taking into account the low frequency of the disease, a multicenter registry compiling clinical, laboratory and imaging data would be of great value.

In conclusion, our two cases illustrate favourable courses among patients with GCA-involvement of both vertebral arteries which have not been reported so far. The identification of prognostic features and the role of early immunosuppressive treatment should be addressed in future clinical research.

R. Sutter · S. Renaud · L. Bonati · P. Lyrer ·
S. Rüegg · S. Engelter
Dept. of Neurology
University of Basel, Switzerland

M. Tolnay
Dept. of Pathology
University of Basel, Switzerland

S. Wetzel
Dept. of Neuroradiology
University of Basel, Switzerland

References

1. Buttner T, Heye N, Przuntek H (1994) Temporal arteritis with cerebral complications: Report of four cases. *Eur Neurol* 34:162–167
2. Caselli JR (1990) Giant cell (temporal) arteritis: A treatable cause of multiinfarct dementia. *Neurology* 40:753–755

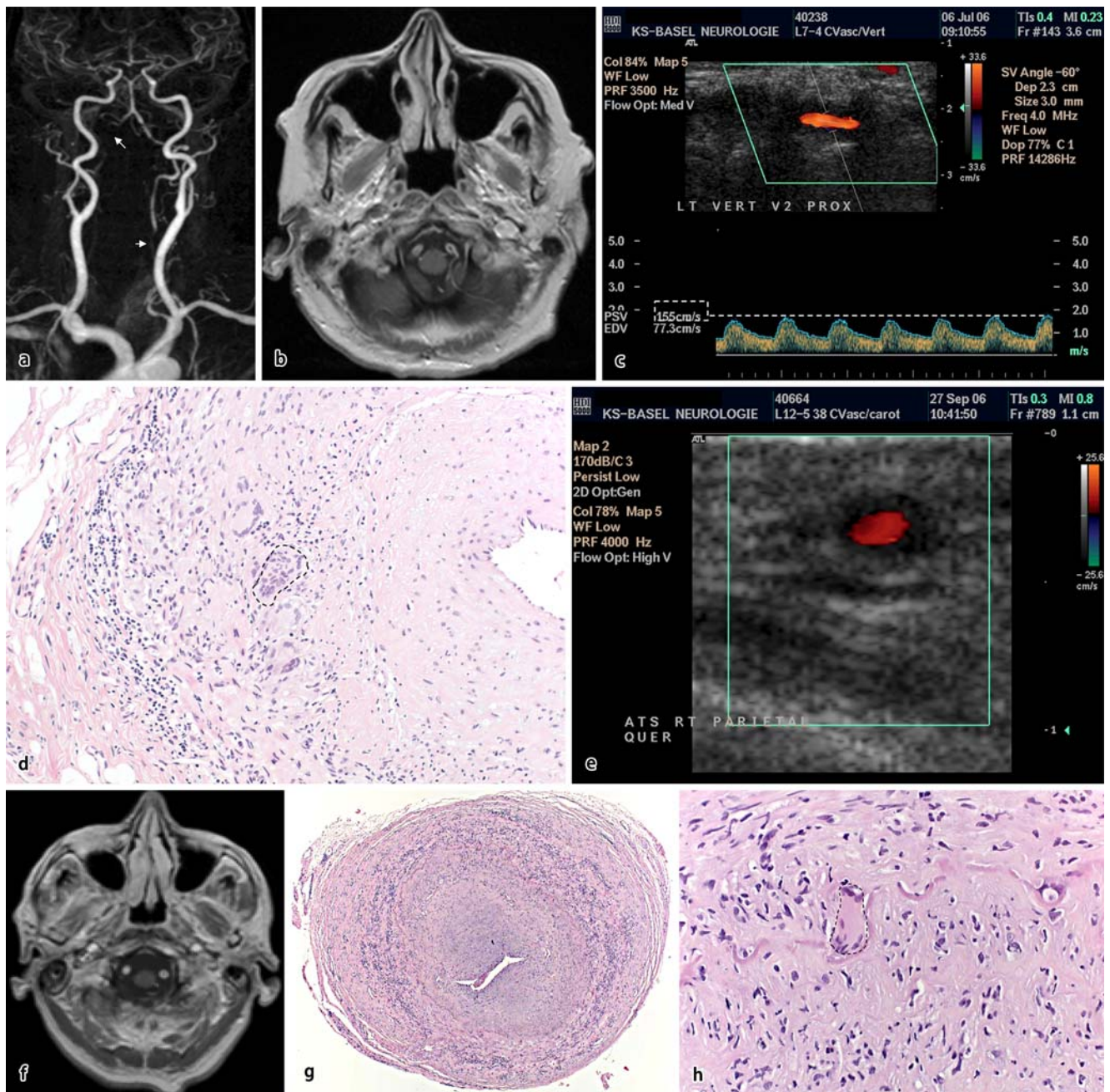


Fig. 1

- Haas S, Jürgens T, Vatankhah B, Schwarz S, Schuierer G, Bogdahn U, Steinbrecher A (2005) Multiple Ischämien im vertebro-basilären Stromgebiet bei Arteriitis temporalis. *Nervenarzt* 76:1527–1531
- Moroianu C, Bentz MH, Revenco E, Clerc C, Richard P, Moulin T, Bataillard M (2006) Fatal giant cell arteritis with bilateral involvement of the vertebral arteries. *Rev Neurol (Paris)* 162 (8–9):876–878
- Reinhard M, Schmidt D, Schumacher M, Hetzel A (2003) Involvement of the vertebral arteries in giant cell arteritis mimicking vertebral dissection. *J Neurol* 250: 1006–1009
- Ronthal M, Gonzalez RG, Smith RN, Frosch MP (2003) Case records of the Massachusetts General Hospital. Weekly clinicopathological exercises. Case 21–2003. A 72-Year Old Man with Repetitive Strokes in the Posterior Circulation. *N Engl J Med* 349:170–180
- Rüegg S, Engelter S, Jeanneret Ch, Hetzel A, Probst A, Steck AJ, Lyrer P (2003) Bilateral vertebral artery occlusion resulting from giant cell arteritis. Report of 3 cases and review of the literature. *Medicine* 82(1):1–12
- Save-Soderbergh J, Malmvall BE, Andersson R, Bengtsson BA (1986) Giant cell arteritis as a cause of death. Report of nine cases. *JAMA* 255:493–496
- Wilkinson IMS, Russel RWR (1972) Arteries of the head and neck in giant cell arteritis. *Arch Neurol* 27:378–391