

Multimodality cardiac imaging

Oliver Gaemperli,^{a,b} and Philipp A. Kaufmann^{b,c}

See related article, pp. 19–26

For the last three decades myocardial perfusion imaging (MPI) with single photon emission computed tomography (SPECT) has been an excellent tool for guiding clinicians in the management of patients with known or suspected coronary artery disease (CAD). However, despite its documented high diagnostic accuracy¹ myocardial perfusion SPECT may fail to detect the true extent of coronary atherosclerosis and thus underestimate the coronary risk in individual patients.² In fact, large observational studies have shown that 43%³ of patients suffering a myocardial infarction and 31%⁴ of patients dying from a cardiac cause had a normal or only mildly abnormal prior perfusion scan. A possible explanation for these shortcomings is inherent in the nature of the technique. MPI evaluates the hemodynamic relevance of coronary stenoses and therefore can only detect obstructive coronary lesions. However, approximately half of patients with normal SPECT perfusion have subclinical CAD on coronary CT angiography (CTA).⁵ Histopathological correlation studies demonstrate that almost 70% of coronary occlusions (leading to myocardial infarction) result from thrombosis of lesions with a stenosis of less than 50% before infarction.⁶ This explains to some extent why—despite evidence of normal myocardial perfusion—patients with subclinical CAD are at higher risk of coronary events, and underlines the importance of assessing the full (i.e., subclinical) extent of CAD to guide therapeutic decisions.⁷

Recent years have witnessed tremendous technological advances in coronary multislice CTA paralleled by an increased use of this technology in clinical practice. Given its high spatial resolution, its noninvasive nature, its relative ease of use, and its complementary value to MPI, CTA has been used as an ideal partner modality for hybrid (or multimodality) imaging with nuclear techniques. Additionally, the increased availability of dedicated fusion software packages for three-dimensional coregistration of CTA and MPI have facilitated the use of hybrid imaging in clinical practice.^{8,9} The feasibility and clinical robustness of noninvasive hybrid imaging was first documented by Namdar and coworkers in a clinical study involving fusion of ¹³N-ammonia positron emission tomography (PET) with 4-slice CTA in 25 patients with CAD.¹⁰ The hybrid PET/CTA images allowed to identify flow-limiting coronary lesions which required a revascularization procedure (as defined by invasive coronary angiography and PET) with a sensitivity, specificity, positive, and negative predictive value of 90%, 98%, 82%, and 99%, respectively. These encouraging results were confirmed by a similar study with SPECT/CTA showing that the hybrid approach resulted in a significant improvement in specificity (from 63% to 95%) and positive predictive value (from 31% to 77%) compared to CTA alone for detecting flow-limiting coronary stenoses.¹¹ Santana and colleagues showed significantly higher diagnostic performance for fused SPECT/CT imaging compared to SPECT alone ($P < 0.001$) and to the side-by-side analysis of SPECT and CT ($P = 0.007$) for the diagnosis of obstructive CAD on invasive coronary angiography. Interestingly, this improved diagnostic performance was mainly a result of a higher sensitivity in patients with multivessel disease.¹² A recent study implementing motion-frozen SPECT data and CTA-guided SPECT contour and territory adjustments, found that the improved diagnostic value of hybrid imaging was mainly driven by higher diagnostic indices in the left circumflex (LCX) and right coronary artery (RCA) territories.¹³ Traditionally, LCX and RCA are subject to more variable patterns of coronary artery anatomy than the left anterior descending artery, which explains the particular value of hybrid imaging in these territories.

The study presented in this issue of the *Journal of Nuclear Cardiology* by Sato and coworkers¹⁴ adds importantly to previously published studies and further underscores the complementary and incremental

From the MRC Clinical Sciences Centre and National Heart and Lung Institute,^a Hammersmith Hospital, Imperial College, London, United Kingdom; Cardiac Imaging,^b University Hospital Zurich, Switzerland; Zurich Center for Integrative Human Physiology (ZIHP),^c University of Zurich, Switzerland.

Reprint requests: Oliver Gaemperli, MRC Clinical Sciences Centre and National Heart and Lung Institute, Hammersmith Hospital, Imperial College London, Hammersmith Campus, Du Cane Road, London W12 0NN, United Kingdom; oliver.gaemperli@csc.mrc.ac.uk.

J Nucl Cardiol 2010;17:4–7.

1071-3581/\$34.00

Copyright © 2009 by the American Society of Nuclear Cardiology.

doi:10.1007/s12350-009-9161-2

diagnostic value of SPECT and CTA. They report on the accuracy of combined imaging with 64-slice CTA and ²⁰¹Thallium SPECT for detecting significant coronary stenoses on invasive coronary angiography in 130 patients with suspected CAD and an intermediate pretest likelihood of disease. The analysis was performed on intention-to-diagnose, considering nonevaluable segments (14%) on CTA as positive. Compared to CTA alone, the combined SPECT/CTA analysis resulted in a significant increase in specificity (from 80% to 92%) and positive predictive value (from 69% to 85%) without any change in sensitivity and negative predictive value. This effect was preserved across all vascular territories and on a patient-based analysis. These results indicate that—in line with findings from prior studies—CTA tends to overestimate coronary stenoses and the combination with SPECT allows identification of many false positive CTA findings. Specificity and positive predictive value are particularly suboptimal in the presence of motion artifacts or severe coronary calcifications. In their study, Sato and colleagues were also able to shed some light on the distribution of perfusion defects among nonevaluable coronary arteries. Interestingly, perfusion defects were rarely observed in vessels with motion artifacts, but were more frequent in severely calcified vessels (59%). Thus, a severely calcified nonevaluable segment should prompt further testing due to its relatively high likelihood of obstructive disease, whereas segments (particularly in the RCA territory) with motion artifacts are usually rather “benign”.

Sato and colleagues, together with previously published data, provide a basis to guide our choice of diagnostic tests in patients with suspected CAD with an intermediate pretest probability of disease. In patients in the lower spectrum of intermediate probability, CTA may be the preferred test due to its high negative predictive value (97% in the study by Sato et al) and lower prevalence of disease in this group of patients. In the presence of equivocal CTA findings or nonevaluable findings, MPI may detect hemodynamically relevant CTA lesions or identify obstructive lesions requiring revascularisation. In patients with an intermediate-to-high pretest probability, the likelihood of coronary calcifications is higher and a lower positive predictive value of CTA can be anticipated. Therefore, MPI may be considered a better first-line test. CTA can be added in the presence of equivocal MPI findings suggestive of attenuation artifacts or microvascular disease.¹⁵ Of note, a combined SPECT/CTA approach is most useful in patients where the initial diagnostic test yields equivocal findings but should not be used routinely in all patients with suspected CAD. Thus, the most practical approach for clinical effectiveness and minimization of costs and radiation dose is sequential scanning (as practiced by

Sato et al) with the preferred imaging modality first and a complementary test added if required for clinical diagnosis and decision-making.

An important limitation commonly encountered in studies assessing the value of hybrid imaging is the lack of an appropriate gold standard, to which noninvasive hybrid imaging could be compared. As shown before, the findings from angiographic techniques differ very often from perfusion findings by SPECT.¹⁶ Therefore, the simple angiographic stenosis (albeit accurately measured with quantitative coronary angiography by Sato et al) is probably a poor standard to reflect the pathophysiologic and prognostic severity of CAD. This is why, to a certain extent, disagreement between SPECT/CTA and coronary angiography is unavoidable by nature of the tests used. For instance, if a 60% stenosis is correctly identified by CTA and coronary angiography, this will result in agreement between both techniques. However, if the lesion is not associated with a perfusion defect on SPECT, the combined SPECT/CTA analysis will classify this lesion as a “false negative” finding which will contribute to reducing the diagnostic accuracy of the combined technique. This apparent disagreement occurs because this particular 60% stenosis is not flow-limiting, a feature that is not assessed by quantitative coronary angiography.

Finally, the added radiation dose from nuclear Imaging techniques and CT is an important issue limiting its clinical use. In the study by Sato et al the total radiation dose from helical CTA (without tube current modulation) and ²⁰¹Thallium SPECT exceeded 30 mSv. However, implementation of modern CT acquisition protocols such as prospective ECG-triggering¹⁷ and body mass adapted tube voltage and current modulation¹⁸ allows reduction of the radiation dose from CTA by 60–80%. Additionally, SPECT perfusion tracers with shorter physical half-lives (^{99m}Tc-tetrofosmin or ^{99m}Tc-sestamibi) are associated with lower radiation doses than ²⁰¹Thallium. A recent study with stress-only hybrid SPECT/CTA imaging reported a total radiation dose of 5.4 mSv for a combined study.¹⁹

The role of percutaneous coronary interventions (PCI) in patients with stable CAD remains a controversial issue, and it is a recognized fact, that stent implantations represent a key cost driver in modern cardiological practice. The current evidence from published trials emphasizes that, in patients with stable CAD and preserved left ventricular function, PCI fails to offer any prognostic benefit over optimal medical therapy, unless a significant amount (generally more than 10%) of the left ventricular myocardium is ischemic.^{20,21} In this case PCI might be more effective than medical therapy in reducing the ischemic burden and thereby improving the patients’ prognosis.²² However,

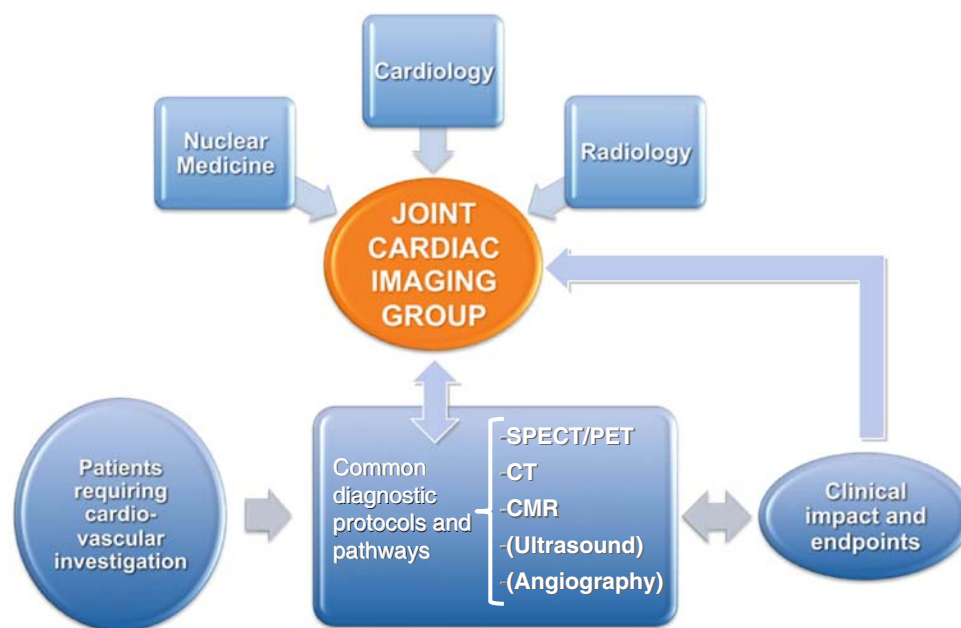


Figure 1. Fusion beyond images. Possible organization of joint multi-disciplinary diagnostic services. Reprinted from Fraser et al²⁴ with permission of Oxford University Press.

in some patients, it may be challenging to identify the culprit lesion from the side-by-side evaluation of MPI and angiography (either CT or invasive). This may contribute to stent overuse to avoid “missing” any significant stenosis. The combination of MPI and CTA into a three-dimensional hybrid image allows the superimposition of myocardial territories onto their subtending coronary arteries, thereby reliably identifying the culprit lesion requiring revascularization. In a previous report of 38 patients with perfusion defects on SPECT, the number of lesions with equivocal hemodynamic relevance was significantly reduced with SPECT/CTA fusion compared to the side-by-side analysis.⁹ This comprehensive noninvasive approach might help to avoid PCI in nonobstructive lesions, thereby reducing stent overuse, cutting on healthcare costs and preventing excess coronary events.²³

Cardiac multimodality imaging is a new and highly dynamic field of continuing research driven by the constant technological advances and innovation of non-invasive imaging and the increasing clinical interest. Its impact extends beyond its clinical utility onto the organization of diagnostic healthcare structures. Traditionally, the different diagnostic tests in CAD diagnosis (i.e., CTA, MPI, and invasive coronary angiography) have been firmly in the hands of different medical specialities, such as radiology, nuclear medicine, and cardiology. However, it is foreseeable that the appropriate use of alternative and complementary tests will require their integration into

joint clinical diagnostic services where experts in all methods collaborate (Figure 1).²⁴ Colleagues with clinical and technical expertise together can exploit the potential of new techniques for studying both anatomy and pathophysiology. This process will be supported by a shift from specializing in a particular technique that is applied by cross-sectional imaging to multiple organs, to an organ or system-based approach where the diagnostic expert is more concerned with function, the integration of results into clinical decision-making, and the impact of diagnostic imaging on clinical outcomes.²⁴

Acknowledgments

O.G. was financially supported by an European Society of Cardiology (ESC) Research grant. P.A.K. was financially supported by the Swiss National Science Foundation (SNSF).

Disclosures

No conflicts of interest to disclose.

References

1. Klocke FJ, Baird MG, Lorell BH, Bateman TM, Messer JV, Berman DS, et al. ACC/AHA/ASNC guidelines for the clinical use of cardiac radionuclide imaging—executive summary: A report of the American College of Cardiology/American Heart Association

- Task Force on Practice Guidelines (ACC/AHA/ASNC Committee to Revise the 1995 Guidelines for the Clinical Use of Cardiac Radionuclide Imaging). *J Am Coll Cardiol* 2003;42:1318-33.
2. Dorbala S, Vangala D, Sampson U, Limaye A, Kwong R, Di Carli MF. Value of vasodilator left ventricular ejection fraction reserve in evaluating the magnitude of myocardium at risk and the extent of angiographic coronary artery disease: A ⁸²Rb PET/CT study. *J Nucl Med* 2007;48:349-58.
3. Hachamovitch R, Berman DS, Shaw LJ, Kiat H, Cohen I, Cabico JA, et al. Incremental prognostic value of myocardial perfusion single photon emission computed tomography for the prediction of cardiac death: Differential stratification for risk of cardiac death and myocardial infarction. *Circulation* 1998;97:535-43.
4. Berman DS, Kang X, Hayes SW, Friedman JD, Cohen I, Abidov A, et al. Adenosine myocardial perfusion single-photon emission computed tomography in women compared with men. Impact of diabetes mellitus on incremental prognostic value and effect on patient management. *J Am Coll Cardiol* 2003;41:1125-33.
5. Gaemperli O, Schepis T, Valenta I, Koepfli P, Husmann L, Scheffel H, et al. Functionally relevant coronary artery disease: Comparison of 64-section CT angiography with myocardial perfusion SPECT. *Radiology* 2008;248:414-23.
6. Falk E, Shah PK, Fuster V. Coronary plaque disruption. *Circulation* 1995;92:657-71.
7. van Werkhoven JM, Schuijf JD, Gaemperli O, Jukema JW, Boersma E, Wijns W, et al. Prognostic value of multislice computed tomography and gated single-photon emission computed tomography in patients with suspected coronary artery disease. *J Am Coll Cardiol* 2009;53:623-32.
8. Gaemperli O, Schepis T, Kalff V, Namdar M, Valenta I, Stefani L, et al. Validation of a new cardiac image fusion software for three-dimensional integration of myocardial perfusion SPECT and stand-alone 64-slice CT angiography. *Eur J Nucl Med Mol Imaging* 2007;34:1097-106.
9. Gaemperli O, Schepis T, Valenta I, Husmann L, Scheffel H, Duerst V, et al. Cardiac image fusion from stand-alone SPECT and CT: Clinical experience. *J Nucl Med* 2007;48:696-703.
10. Namdar M, Hany TF, Koepfli P, Siegrist PT, Burger C, Wyss CA, et al. Integrated PET/CT for the assessment of coronary artery disease: A feasibility study. *J Nucl Med* 2005;46:930-5.
11. Rispler S, Keidar Z, Ghersin E, Roguin A, Soil A, Dragu R, et al. Integrated single-photon emission computed tomography and computed tomography coronary angiography for the assessment of hemodynamically significant coronary artery lesions. *J Am Coll Cardiol* 2007;49:1059-67.
12. Santana CA, Garcia EV, Faber TL, Sirineni GK, Esteves FP, Sanyal R, et al. Diagnostic performance of fusion of myocardial perfusion imaging (MPI) and computed tomography coronary angiography. *J Nucl Cardiol* 2009;16:201-11.
13. Slomka PJ, Cheng VY, Dey D, Woo J, Ramesh A, Van Kriekinge S, et al. Quantitative analysis of myocardial perfusion SPECT anatomically guided by coregistered 64-slice coronary CT angiography. *J Nucl Med* 2009;50:1621-30.
14. Sato A, Nozato T, Hikita H, Miyazaki S, Takahashi Y, Kuwahara T, et al. Incremental value of combining 64-slice computed tomography angiography with stress nuclear myocardial perfusion imaging to improve noninvasive detection of coronary artery disease. *J Nucl Cardiol* 2009. doi:10.1007/s12350-009-9150-5.
15. Abidov A, Gallagher MJ, Chinnaiyan KM, Mehta LS, Wegner JH, Raff GL. Clinical effectiveness of coronary computed tomographic angiography in the triage of patients to cardiac catheterization and revascularization after inconclusive stress testing: Results of a 2-year prospective trial. *J Nucl Cardiol* 2009;16:701-13.
16. Schuijf JD, Wijns W, Jukema JW, Atsma DE, de Roos A, Lamb HJ, et al. Relationship between noninvasive coronary angiography with multi-slice computed tomography and myocardial perfusion imaging. *J Am Coll Cardiol* 2006;48:2508-14.
17. Husmann L, Valenta I, Gaemperli O, Adda O, Treyer V, Wyss CA, et al. Feasibility of low-dose coronary CT angiography: First experience with prospective ECG-gating. *Eur Heart J* 2008;29:191-7.
18. Tatsugami F, Husmann L, Herzog BA, Burkhard N, Valenta I, Gaemperli O, et al. Evaluation of a body mass index-adapted protocol for low-dose 64-MDCT coronary angiography with prospective ECG triggering. *AJR Am J Roentgenol* 2009;192:635-8.
19. Husmann L, Herzog BA, Gaemperli O, Tatsugami F, Burkhard N, Valenta I, et al. Diagnostic accuracy of computed tomography coronary angiography and evaluation of stress-only single-photon emission computed tomography/computed tomography hybrid imaging: Comparison of prospective electrocardiogram-triggering vs. retrospective gating. *Eur Heart J* 2009;30:600-7.
20. Boden WE, O'Rourke RA, Teo KK, Hartigan PM, Maron DJ, Kostuk WJ, et al. Optimal medical therapy with or without PCI for stable coronary disease. *N Engl J Med* 2007;356:1503-16.
21. Hachamovitch R, Hayes SW, Friedman JD, Cohen I, Berman DS. Comparison of the short-term survival benefit associated with revascularization compared with medical therapy in patients with no prior coronary artery disease undergoing stress myocardial perfusion single photon emission computed tomography. *Circulation* 2003;107:2900-7.
22. Shaw LJ, Berman DS, Maron DJ, Mancini GB, Hayes SW, Hartigan PM, et al. Optimal medical therapy with or without percutaneous coronary intervention to reduce ischemic burden: results from the Clinical Outcomes Utilizing Revascularization and Aggressive Drug Evaluation (COURAGE) trial nuclear sub-study. *Circulation* 2008;117:1283-91.
23. Tonino PA, De Bruyne B, Pijls NH, Siebert U, Ikeno F, van't Veer M, et al. Fractional flow reserve versus angiography for guiding percutaneous coronary intervention. *N Engl J Med* 2009;360:213-24.
24. Fraser AG, Buser PT, Bax JJ, Dassen WR, Nihoyannopoulos P, Schwitzer J, et al. The future of cardiovascular imaging and non-invasive diagnosis: A joint statement from the European Association of Echocardiography, the Working Groups on Cardiovascular Magnetic Resonance, Computers in Cardiology, and Nuclear Cardiology, of the European Society of Cardiology, the European Association of Nuclear Medicine, and the Association for European Paediatric Cardiology. *Eur Heart J* 2006;27:1750-3.