

Three-dimensional imaging of the larynx for pre-operative planning of laryngeal framework surgery

Claudio Storck · Philipp Juergens · Claude Fischer · Olivia Haenni · Franz Ebner · Markus Wolfensberger · Erich Sorantin · Gerhard Friedrich · Markus Gugatschka

Received: 23 April 2009 / Accepted: 8 October 2009 / Published online: 28 October 2009
© Springer-Verlag 2009

Abstract Modern laryngeal framework surgery (LFS) requires an exact understanding of the laryngeal biomechanics and precise pre-operative planning, for which bi-planar imaging is not sufficient. The aim of the study was to test whether MIMICS®, a commercially available software package for three-dimensional (3D) rendering of high-resolution computerised tomography (HRCT), is suitable for 3D imaging of the larynx, analysis of laryngeal biomechanics and pre-operative planning. We examined four cadaver larynx and one patient larynx. In the five larynges, all relevant structures and landmarks could be 3D visualised.

Superimposing of two HRCT scans shows that when the arytenoids move from ‘respiration’ to ‘phonation’, they perform a rotating, translating and tilting motion. Moreover, we could demonstrate that the vocal fold elongates by 7% with cricothyroid approximation. We conclude that MIMICS® is well suited for 3D imaging of the larynx, analysis of laryngeal biomechanics and pre-operative planning of LFS procedures.

Keywords 3D visualisation · Larynx · High-resolution computer tomography · Biomechanics · MIMICS

C. Storck (✉) · C. Fischer · O. Haenni · M. Wolfensberger
Department of Otorhinolaryngology,
Head and Neck Surgery and Phoniatics,
University Hospital Basel, Petersgraben 4,
4031 Basel, Switzerland
e-mail: cstorck@uhbs.ch

P. Juergens
Hightech Research Centre of Cranio-Maxillofacial Surgery,
University Hospital of Basel, Schanzenstrasse 46,
4031 Basel, Switzerland

F. Ebner
Section of Neuroradiology, Department of Radiology,
Medical University of Graz, Auenbruggerplatz 9,
8036 Graz, Austria

E. Sorantin
Section of Paediatric Radiology, Department of Radiology,
Medical University Graz, Auenbruggerplatz 34,
8036 Graz, Austria

G. Friedrich · M. Gugatschka
Department of Phoniatics, ENT University Hospital,
Medical University Graz, Auenbruggerplatz 26,
8036 Graz, Austria

Introduction

Modern laryngeal framework surgery (LFS) aims at vocal fold medialisation (in cases of vocal fold palsy), thyroid expansion (for the treatment of spastic dysphonia), vocal fold relaxation (in cases of incomplete mutation) or vocal fold tensioning (after sex change procedures) [1]. Much more so than ablative surgery (be it for cancer resection or removal of benign vocal fold lesions), LFS requires an exact understanding of the laryngeal biomechanics as well as anatomically precise planning of the intervention [2]. Routine pre-operative workup in these cases usually includes imaging by high-resolution computerised tomography (HRCT) and/or magnetic resonance tomography (MRT) [3]. However, we consider the standard, bi-planar imaging insufficient in the context of LFS, since only three-dimensional imaging is able to depict the precise anatomy of the laryngeal cartilages, both at rest and in different positions (e.g. respiration, phonation) [4]. So, what we are looking for is software, which is robust and sufficiently fast to be useful for research purposes as well as for clinical work, and which, to avoid repeat radiological

examinations, is able to handle already existing imaging data. These data should preferably be HRCT data, since HRCT is more readily available and better suited to the examination of cartilage (and less expensive) than MRT. So far, we have not been aware of any 3D imaging software in clinical use that fulfils these criteria. MIMICS® Version 12.0 (Materialise™ Interactive Medical Image Control System, Leuven, Belgium) is an interactive software package, which is used in reconstructive maxillofacial surgery and in heart surgery for precise pre-operative planning [5, 6].

The purpose of this pilot study was to answer the following three questions: (1) Is MIMICS® suitable (with regard to image quality, software robustness and time consumption) for 3D imaging of both, hard and soft tissues of the larynx? (2) Are 3D images obtained by HRCT and MIMICS® adequate for biomechanical studies of laryngeal function? (3) Are these images adequate and helpful for pre-operative planning of LFS?

In a first step, we examined four cadaver larynges to answer the question, whether all relevant anatomical structures and landmarks can be three-dimensionally visualised reliably, with sufficient precision and within an acceptable time frame, irrespective of laryngeal calcification (i.e. age and sex of the patient).

Two of us (C.S. and G.F.) routinely perform vocal fold medialisation and vocal fold tensioning procedures. Both procedures affect the movements of the arytenoid cartilages and/or the form of the glottic chink. As mentioned below, there exists no consensus on the subject of the functioning of the cricoarytenoid joint despite all the research that has been done in the past. So, in a second step (again performed on a cadaver larynx), we tried to find out whether it was possible to visualise the movement of the arytenoid cartilages in three dimensions, when they moved from the respiratory to the phonatory position. Moreover, we checked whether it was possible to measure

the lengthening of the vocal folds on cricothyroid approximation.

Finally, having answered these questions in the affirmative, we examined the normal larynx of a patient to make sure that the limitations inherent in a routine clinical exam (e.g. movement artefacts) did not jeopardise the results.

Materials and methods

We examined four cadaver larynges (2 male, 32 and 78 years, and 2 female, 49 and 71 years) and one patient larynx (male, 74 years old with no laryngeal pathology). The study was approved by the medical ethics committees of the University of Basel (Switzerland) and the University of Graz (Austria).

Preparation of the larynges

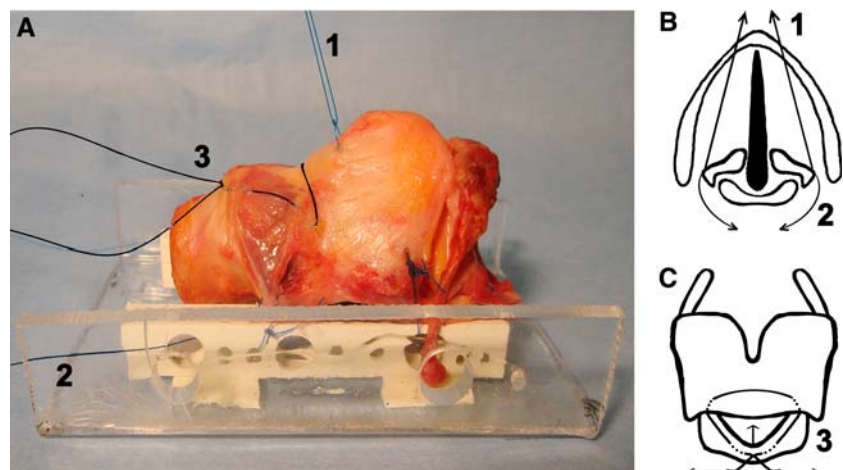
The fresh cadaver larynges were excised and examined within less than 24 h after death. Inclusion criteria were intact larynx without pathology, no previous laryngeal radiation or surgery and no infectious or rheumatologic disease.

The pre-laryngeal strap muscles, as well as the pharyngeal mucosa of the piriform sinus and the post-cricoid area, were removed. The conical ligament was exposed by removing the fat tissue between the cricothyroid muscles. The trachea was transected below the second cartilage ring.

The larynges were mounted on a custom-made device, which consists of two perforated straight acrylic bars measuring $80 \times 10 \times 5$ mm (Fig. 1a).

To simulate the movement of the arytenoid cartilages in the cricoarytenoid joints, two non-absorbable threads were placed on each side, one mimicking the function of the thyroarytenoid muscle (Fig. 1b, thread 1) and the other mimicking the function of the posterior cricoarytenoid muscle (Fig. 2b, thread 2). Pulling on thread 1 closed the

Fig. 1 **a** Side view of a cadaver larynx fixed on a mounting device. **b** Top view draft of a larynx on the level of the glottis. **c** Front view draft of a larynx. 1, 2, and 3: threads denote the simulation of the positions 'phonation' (1), 'respiration' (2) and 'cricothyroidopexy' (3)



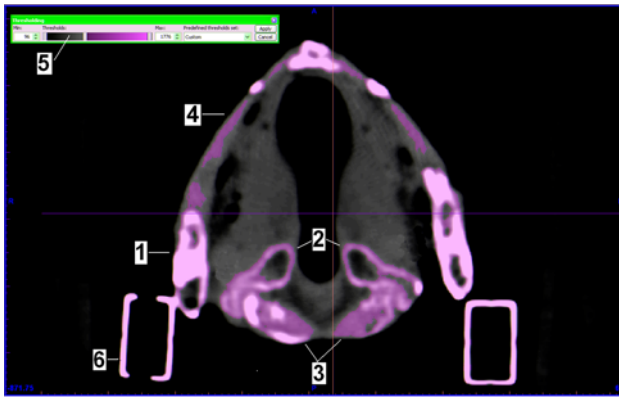


Fig. 2 Screen of MIMICS® (axial view). The ossified areas of thyroid cartilage (1), arytenoid cartilages (2) and cricoid cartilage (3) are detected automatically. The non-ossified thyroidal laminae (4) can be detected by adjusting the threshold (5). Mounting device (6)

membranous part of the glottis by adduction of the arytenoid cartilages, whereas pulling on thread 2 opened the glottis by abducting the arytenoid cartilages. We scanned three distinct positions, which we labelled ‘neutral’, ‘phonatory’ and ‘respiratory’.

Finally, to simulate cricothyroid approximation, a third thread was placed mimicking the action of the two cricothyroid muscles (Fig. 1c, thread 3). Pulling on the two ends of this thread, the cricoid and the thyroid cartilage were approximated. We labelled this the ‘cricothyroidopexy’ position.

HRCT examination

HRCT examination was performed with an Aquilion ONE scanner (Toshiba®). The optimal setting was found to be 120 kV and 150 mA. The slice thickness was 1.0 mm. The rotation time was 1 s for cadaver larynges and 0.5 s for the patient’s larynx. The radiation dosage for one exam was 1.2 mSv. Of course, this number has to be multiplied by the

number of laryngeal positions examined. The HRCT DICOM data were then imported and converted to MIMICS® for post-process imaging.

Post-process imaging

MIMICS® is a general-purpose segmentation programme for grey value images. It offers an interactive tool for the visualisation, segmentation and 3D rendering of objects with HRCT as well as MRT data. MIMICS® interfaces with all common scanner formats. In a first step, one can select the interested range of grey values. This can be done automatically by choosing a pre-defined range (e.g. for cartilage) or manually by setting the range on a scale of grey values. In addition, manual editing functions make it possible to erase or restore parts of the images as well as to fill internal gaps (Fig. 2). This is typically used for smoothing surfaces and eliminating artefacts. Whereas three windows on the screen show axial, coronal and frontal planes, the fourth window shows the 3D image. Visualisation functions include real-time rotation (e.g. to obtain front, side, top or any oblique view) and zoom. In addition, part of the larynx can be virtually cut away or made transparent to allow a look inside the larynx (Fig. 3). Point-to-point measurements on the 3D reconstruction may also be performed. Finally, it is possible to superimpose two (or more) 3D reconstructions by selecting and marking three clearly defined points (e.g. the thyroid notch, the lower border and the superior horns of the thyroid) on both 3D images.

To answer the question whether all relevant anatomical structures and (surgical) landmarks were visible on the 3D images, we identified the superior and inferior horns of the thyroid cartilage, the thyroid notch and laminae, the vocal and muscular processes of the arytenoid cartilages, the accessory cartilages, the epiglottis, the cricoid cartilage, the cricoarytenoid and cricothyroid joints, and the hyoid bone, as well as the thyroid notch, the inferior border and the

Fig. 3 3D-rendered male cadaver larynx (a) and patient’s larynx (b). All relevant anatomical structures and landmarks can be visualised in both 3D images (1: thyroid cartilage; 2: cricoid cartilage; 3: arytenoid cartilages; 4: epiglottis; 5: hyoid bone)

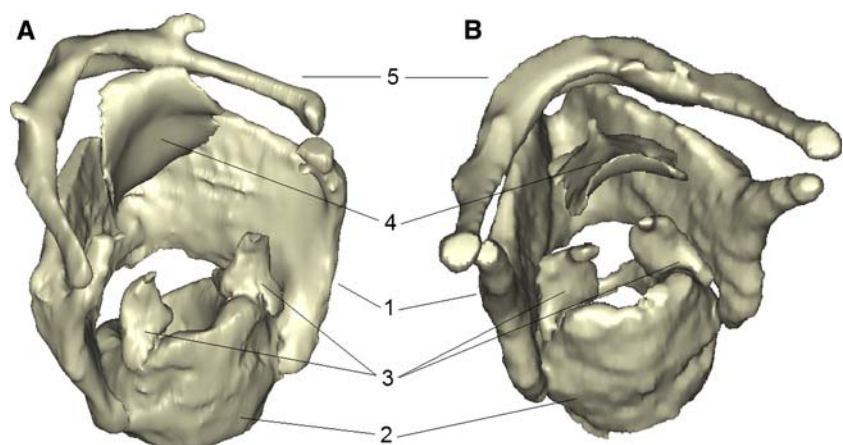
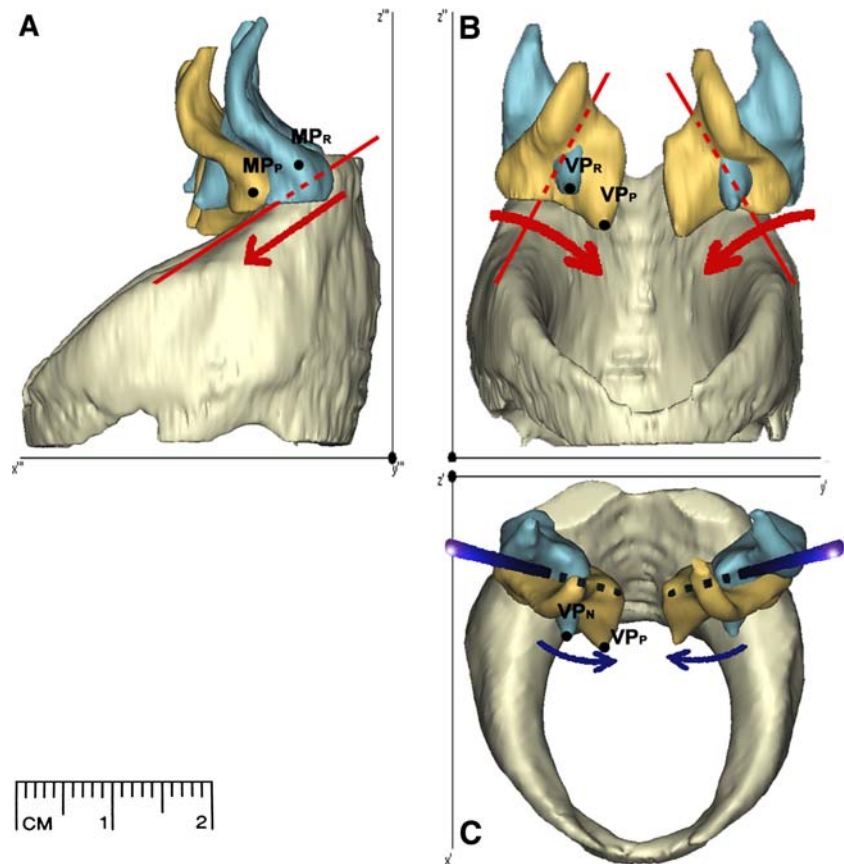


Fig. 4 Side view (a), front view (b), and top view (c) of the superimposed and 3D-rendered HRCT scans from the positions ‘phonation’ (yellow) and ‘respiration’ (blue). Side view (a): Arytenoid cartilages sliding along the axis of the cricoarytenoid joint (red line). Front view (b): rotation of the arytenoid cartilages around the axis of the cricoarytenoid joint (red line). Top view (c): Tilting movement of the arytenoid cartilages around a virtual axis (blue line). MP_R: Muscular process, ‘respiration’; MP_P: Muscular process, ‘phonation’; VP_R: Vocal process, ‘respiration’; VP_P: Vocal process, ‘phonation’



oblique line of the thyroid cartilage, and the annular border of the cricoid cartilage.

To depict the movement of the arytenoid cartilages in the cricoarytenoid joint, we overlaid the 3D images of the positions ‘phonation’ and ‘respiration’ (Fig. 4). To measure the lengthening of the vocal fold during cricothyroid approximation, we overlaid the 3D images of the positions ‘neutral’ and ‘cricothyroidopexy’ (Fig. 5).

Finally, by setting the grey range (automatically or manually) for mucosa, it is possible to visualise the mucosal surface, thereby performing a ‘virtual endoscopy’ (Fig. 6a, b).

Results

Time necessary for post-processing

Whereas in the research laboratory, time may be of secondary importance, in clinical use it is of paramount importance. The most time-consuming part is segmentation. Depending on how calcified the larynx is, it takes between 20 and 60 min (average 30 min). Of course, this time has to be multiplied by the number of different positions examined. Overlaying two 3D images takes about 15 min.

Visualisation of the laryngeal cartilages in the cadaver larynges

On all four larynges, all anatomically relevant structures and landmarks could be visualised by MIMICS® (Fig. 3a). However, whereas ossified cartilages (or parts thereof) were adequately segmented (and hence 3D visualised) using the automatic detection threshold of MIMICS®, non-ossified parts of the cartilages could only be segmented adequately by setting the threshold manually.

Visualisation of the movement of the arytenoid cartilages

Figure 4 shows that by superimposing the 3D images of the ‘respiratory’ and ‘phonatory’ scans, the complex three-dimensional movement of the arytenoid cartilages can be visualised. If the arytenoid cartilages move from the respiratory to the phonatory position, the cartilages rotate downward around an axis that runs parallel to the cricoarytenoid joint surface (front view, Fig. 4b) and inward around an axis vertical to the joint surface (top view, Fig. 4c). The side view (Fig. 4a) shows an additional antero-lateral sliding of the arytenoids along the joint surface of the cricoid. In sum, moving from the respiratory to the phonatory position, the arytenoid cartilages show a downward and inward rotation plus an antero-lateral sliding movement. The influence

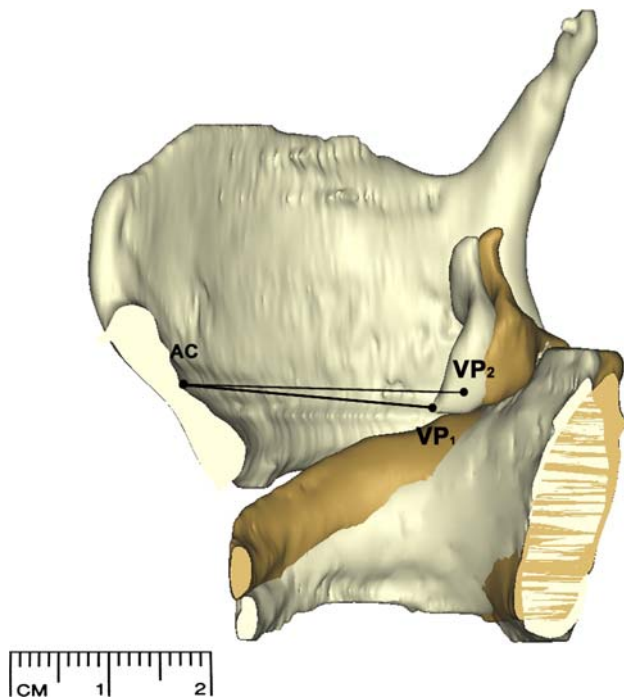


Fig. 5 Right half of a larynx. Superimposed and 3D-rendered HRCT scans of the positions ‘neutral’ (grey) and ‘cricothyroidopexy’ (gold). The cricoid plate and the arytenoid cartilage tilt backwards. Consequently, the distance between the anterior commissure (AC) and the vocal process lengthens from the neutral ‘position’ (VP₁) to the ‘cricothyroidopexy’ position (VP₂)

that this movement has on the configuration of the glottic chink can be seen in the surface (or virtual endoscopy type) images (Fig. 6a, b).

Visualisation of the cricothyroid approximation

To analyse the effect of the cricothyroid approximation on the vocal folds, we superimposed the positions ‘neutral’ and ‘cricothyroidopexy’. Figure 5 shows the right half of a larynx at the two positions. The cricoid plate tilts backwards. Consequently, the arytenoid cartilage, sitting on top of the cricoid plate, moves backwards and thereby elongates

the vocal fold. In our larynx, the distance from the anterior commissure (AC) to the vocal process (VP) measured 25 mm in the neutral position, and 27 mm in the ‘cricothyroidopexy’ position. This corresponds to a vocal fold elongation of 7%.

Visualisation of the laryngeal cartilages in a patient’s larynx

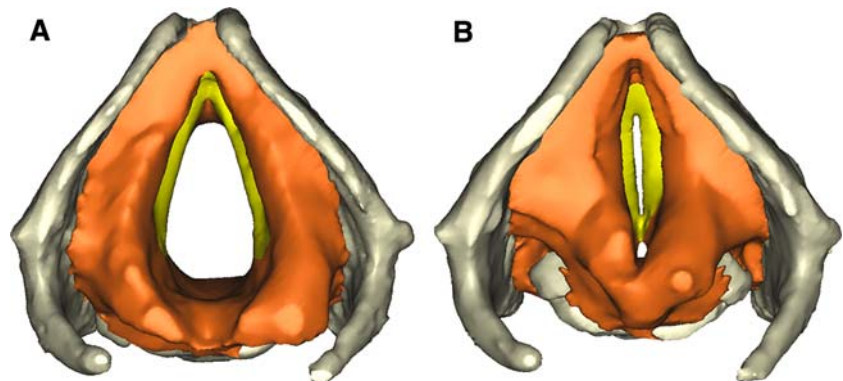
This is primarily an in vitro study. However, as Fig. 3b demonstrates, data from a patient HRCT are perfectly suitable for 3D imaging by MIMICS®.

Discussion

The term ‘laryngeal framework surgery’ (LFS) refers to surgical interventions on the laryngeal cartilages aimed at improving, changing or restoring a patient’s voice [1]. LFS requires an exact understanding of the laryngeal biomechanics as well as anatomically precise planning of the intervention. Pre-operative planning is routinely done by bi-planar (CT or MRT) imaging [3, 7]. Since it is very difficult to mentally form a 3D image of the laryngeal structures, let alone to visualise the movements of the cartilages in three dimensions on the basis of bi-planar scans, we consider bi-planar imaging insufficient in the context of LFS. What we need are good 3D reconstructions. So far, we are not aware of any software in clinical use for 3D reconstruction of laryngeal structures. However, since maxillofacial surgeons and vascular surgeons are successfully using MIMICS® for the planning of three-dimensional reconstructions of both, hard and soft tissues [8, 9], it seems reasonable to test the suitability of MIMICS® for 3D imaging of the larynx. Since HRCT is the imaging technique commonly used in the context of LFS [4], we decided to use HRCT data.

Our pilot study on four cadaver larynges and on one patient larynx shows that with the help of MIMICS®, segmenting and three-dimensional visualisation of all relevant

Fig. 6 Top view of a larynx shows different configurations of the glottic chink in the positions ‘respiration’ (a) and ‘phonation’ (b). Vocal folds (yellow)



laryngeal structures and landmarks is possible. We believe that apart from Hiramatsu et al. [10], no one has done this before.

MIMICS® provides pre-programmed segmentation thresholds for various tissues such as bone, muscle, fat, mucosa or implant materials. Because of the irregular calcification [11–15] and hence inhomogeneity of the laryngeal cartilages, automatic segmentation using pre-programmed thresholds does not work equally well in all larynges. Non-calcified cartilages (or less calcified parts of cartilages) can only be segmented by adjusting the threshold manually. Of course, this takes more time than automatic segmenting. Whereas automatic segmenting takes about 20 min for an entire larynx, manual segmenting may take up to 60 min. We think that this is acceptable not only for research purposes, but also in a clinical setting. Moreover, we are confident that with more experience, we will be able to manually segment a larynx in considerably less time, and that, once the method is established, segmenting can also be done by technical personnel. On setting the threshold for mucosa (either automatically or manually), we were able to produce 3D images of the mucosal surface, comparable to a virtual endoscopy. Of course, virtual endoscopy of the larynx is less interesting than virtual endoscopy of a less easily endoscopically accessible organ such as the colon. Nevertheless, it allows a correlation of mucosal surface and exact cartilage position. Unfortunately, although MIMICS® provides pre-set segmentation thresholds for muscles, we could not visualise individual muscles because the tissue densities of muscle and fat on HRCT were too close.

The exact trajectory of the arytenoid cartilages when they move from an extreme respiratory position through an intermediary position to the phonatory position has been the subject of countless studies [4, 16–21], and yet it is not completely understood. Similarly, what precisely happens during different types of phonation (e.g. singing, whispering) is not completely understood [22–24]. So far, imaging techniques have not added to our understanding of endolaryngeal movements [17–20]. It is our long-term goal to examine these movements in volunteers and patients with different pathologies using 3D imaging. Even if pulling on threads may seem (and indeed is) a primitive way of simulating laryngeal movements, our pilot study shows (1) that the arytenoid cartilages move in all three dimensions (and not just on a plane) and (2) that MIMICS® does allow us to superimpose two (or more) HRCT scans, thereby visualising the trajectory of the arytenoid cartilages. Again, we believe that this has not been done before.

For pre-operative planning of vocal fold medialisation procedures, optimal visualisation of the arytenoid cartilages, not only in the vocal fold plane, but in space, is very important. Whereas in cases of recurrent nerve palsy, the paralysed vocal fold is straight and slightly lateralised, but

on the same plane as the normal vocal fold, in cases of vagal nerve palsy it is excavated, more lateralised and on a slightly deeper plane than the normal vocal fold [25]. Both the excavation and the downward shift are probably due to the reduced tension of the cricothyroid muscle [25]. This difference has surgical consequences. Whereas simple vocal fold medialisation is sufficient for the treatment of recurrent nerve palsy, the vocal fold has to be medialised, tensioned, and smoothly pushed upwards in cases of vagal nerve palsy. Of course, these (subtle) differences can be ‘seen’ on laryngoscopy. However, for pre-operative planning, precise imaging allowing us to quantify the necessary amount of displacement is more helpful. We hope that by demonstrating the exact position (in space) of the arytenoid cartilages in different cases of laryngeal palsies, we will be better able to plan medialisation procedures. We also hope to produce a custom-made medialisation implant one day.

Another laryngeal framework procedure that we believe will benefit from exact pre-operative planning is cricothyroidopexy, performed to raise the pitch of the voice in man-to-female transsexuals. The relationship between the length (and hence tension) of the vocal folds and the pitch of the voice in a given individual is not known. Pre-operatively measuring the amount of lengthening of the vocal fold achievable by maximal cricothyroid adduction and correlating this with the observed pitch will (hopefully) help us better plan the surgery (and to predict the outcome). Previous *in vivo* measurements of vocal fold length were all performed with conventional X-ray images or bi-planar CT scans [26–31]. Again, we believe that this is not adequate. Because the vocal fold plane changes with cricothyroid approximation, only a three-dimensional image allows precise measuring of the vocal fold elongation. Our pilot study shows that precise measurement of vocal fold elongation achieved with cricothyroidopexy is possible in cadavers. We are confident that it will also be possible in patients. Of course, it would be most fascinating to study the voice changes resulting from vocal fold elongation in professional actors or singers with the help of 3D imaging [26].

We conclude that MIMICS®, in conjunction with HRCT scans, is well suited for 3D imaging of the larynx. It is helpful both for the analysis of laryngeal biomechanics and for pre-operative planning of LFS procedures. This feasibility study will serve as a basis for further biomechanical studies on cadaver larynges and for the examination of patients with different pathologies.

Acknowledgments This study was financially supported by the Hippocrate Foundation, the Julia and Gottfried Bangerter-Rhyner Foundation and the Lichtenstein Foundation.

Conflict of interest statement All authors declare that they do not have any conflicts of interest.

References

1. Friedrich G, De Jong FICRS, Mahieu HF, Benninger MS, Isshiki N (2001) Laryngeal framework surgery: a proposal for classification and nomenclature by the Phonosurgery Committee of the European Laryngological Society. *Eur Arch Otorhinolaryngol* 375:1–8
2. Friedrich G, Lichtenegger R (1997) Surgical anatomy of the larynx. *J Voice* 11:345–355
3. Friedrich G, Kainz J (1988) Morphometry of the larynx in horizontal sections. Normal data for the quantitative evaluation of current imaging technics. *Laryngol Rhinol Otol (Stuttg)* 67:269–274
4. Hunter EJ, Titze IR, Alipour F (2004) A three-dimensional model of vocal fold abduction/adduction. *J Acoust Soc Am* 115:1747–1759
5. Jacobs S, Grundert R, Mohr FW, Falk V (2008) 3D-Imaging of cardiac structures using 3D heart models for planning in heart surgery: a preliminary study. *Interact Cardiovasc Thorac Surg* 7:6–9
6. Mavili ME, Canter HI, Saglam-Aydinatay B, Kocadereli I (2007) Tridimensional evaluation of maxillary and mandibular movements in orthognathic surgery. *J Craniofac Surg* 18:792–799
7. Friedrich G, Kainz J, Schneider GH, Anderhuber F (1989) Computed tomography of the larynx in the diagnosis of dysphonia. *Folia Phoniatr (Basel)* 41:283–291
8. Doyle BJ, Grace PA, Kavanagh EG, Burke PE, Wallis F, Walsh MT, McGloughlin TM (2009) Improved assessment and treatment of abdominal aortic aneurysms: the use of 3D reconstructions as a surgical guidance tool in endovascular repair. *Ir J Med Sci* 178:321–328
9. Pham AM, Rafii AA, Metzger MC, Jamali A, Strong EB (2007) Computer modeling and intraoperative navigation in maxillofacial surgery. *Otolaryngol Head Neck Surg* 137:624–631
10. Hiramatsu H, Tokasjiki R, Suzuki M (2008) Usefulness of three-dimensional computed tomography of the larynx for evaluation of unilateral vocal fold paralysis before and after treatment: technique and clinical applications. *Eur Arch Otorhinolaryngol* 265:725–730
11. Nemecek SF, Krestan CR, Noebauer-Huhmann IM, Formanek M, Fruhwald J, Peloschek P et al (2009) Radiological normal anatomy of the larynx and pharynx and imaging techniques. *Radiologe* 49:8–16
12. Ruffing S, Struffert T, Grgic A, Reith W (2005) Imaging diagnostics of the pharynx and larynx. *Radiologe* 45:828–836
13. Castelijns JA, Doornbos J, Verbeeten B Jr, Vielvoye GJ, Bloem JL (1985) MR imaging of the normal larynx. *J Comput Assist Tomogr* 9:919–925
14. Castelijns JA, Golding RP, van Schaik SC, Valk J, Snow GB (1990) MR findings of cartilage invasion by laryngeal cancer: value in predicting outcome of radiation therapy. *Radiology* 174:669–673
15. Steinkamp HJ, Heim T, Zwicker C, Mathe F, Schorner W, Felix R (1992) The value of nuclear magnetic resonance tomography in tumor staging of laryngeal-/hypopharyngeal cancer. *HNO* 40:339–345
16. Frable MA (1961) Computation of motion at the cricoarytenoid joint. *Arch Otolaryngol* 73:73–78
17. von Leden H, Moore P (1961) The mechanics of the cricoarytenoid joint. *Arch Otolaryngol* 73:541–550
18. Ardran GM, Kemp FH (1966) The mechanism of the larynx: part I. The movements of the arytenoid and cricoid cartilages. *Br J Radiol* 39:641–654
19. Wang R (1998) Three-dimensional analysis of cricoarytenoid joint motion. *Laryngoscope* 108(Suppl 86):1–17
20. Probst KX, Schon Ybarra MA, Kashima H, Crosby RW (2004) Topography and interactions of the arytenoid and cricoid articular surfaces: implications for vocal process positional shifts. *Clin Anat* 17:206–213
21. Sellars IE, Keen EN (1978) The anatomy and movements of the cricoarytenoid joint. *Laryngoscope* 88:667–674
22. Sonninen A, Hurme P, Laukkanen AM (1999) The external frame function in the control of pitch, register and singing mode: radiographic observations of a female singer. *J Voice* 13:319–340
23. Rubin AD, Praneetvatakul V, Gherson S, Moyer CA, Sataloff RT (2006) Laryngeal hyperfunction during whispering: reality or myth? *J Voice* 20:121–127
24. Solomon NP, McCall GN, Trosset MW, Gray WC (1989) Laryngeal configuration and constriction during two types of whispering. *J Speech Hear Res* 32:161–174
25. Kruse E, Olthoff A, Schiel R (2006) Functional anatomy of the recurrent and superior laryngeal nerve. *Langenbecks Arch Surg* 391:4–8
26. Roers F, Mürbe D, Sundberg J (2009) Predicted singers' vocal fold lengths and voice classification—a study of X-ray morphological measures. *J Voice* 23:408–413
27. Sonninen A (1954) Is the length of the vocal cords the same at all different levels of singing? *Acta Otol Laryngol Suppl* 118:219–231
28. Damsté PH, Hollien H, Moore GP, Murry T (1968) An X-ray study of vocal fold length. *Folia Phoniatr* 20:349–359
29. Hollien H, Damsté PH, Murry T (1969) Vocal fold length during vocal fry phonation. *Folia Phoniatr* 21:257–265
30. Hollien H, Moore GP (1960) Measurements of the vocal folds during changes in pitch. *J Speech Hear Res* 3:157–165
31. Luchsinger R, Pfister K (1961) Die Messung der Stimmlippenverlängerung beim Steigern der Tonhöhe. *Folia Phoniatr* 13:1–12