

ORIGINAL ARTICLE

Highly Effective Regimen for Decolonization of Methicillin-Resistant *Staphylococcus aureus* Carriers

M. Buehlmann, MD; R. Frei, MD; L. Fenner, MD; M. Dangel, MPH; U. Fluckiger, MD; A. F. Widmer, MD, MS

OBJECTIVE. To evaluate the efficacy of a standardized regimen for decolonization of methicillin-resistant *Staphylococcus aureus* (MRSA) carriers and to identify factors influencing decolonization treatment failure.

DESIGN. Prospective cohort study from January 2002 to April 2007, with a mean follow-up period of 36 months.

SETTING. University hospital with 750 beds and 27,000 admissions/year.

PATIENTS. Of 94 consecutive hospitalized patients with MRSA colonization or infection, 32 were excluded because of spontaneous loss of MRSA, contraindications, death, or refusal to participate. In 62 patients, decolonization treatment was completed. At least 6 body sites were screened for MRSA (including by use of rectal swabs) before the start of treatment.

INTERVENTIONS. Standardized decolonization treatment consisted of mupirocin nasal ointment, chlorhexidine mouth rinse, and full-body wash with chlorhexidine soap for 5 days. Intestinal and urinary-tract colonization were treated with oral vancomycin and cotrimoxazole, respectively. Vaginal colonization was treated with povidone-iodine or, alternatively, with chlorhexidine ovula or octenidine solution. Other antibiotics were added to the regimen if treatment failed. Successful decolonization was considered to have been achieved if results were negative for 3 consecutive sets of cultures of more than 6 screening sites.

RESULTS. The mean age (\pm standard deviation [SD]) age of the 62 patients was 66.2 ± 19 years. The most frequent locations of MRSA colonization were the nose (42 patients [68%]), the throat (33 [53%]), perianal area (33 [53%]), rectum (36 [58%]), and inguinal area (30 [49%]). Decolonization was completed in 87% of patients after a mean (\pm SD) of 2.1 ± 1.8 decolonization cycles (range, 1–10 cycles). Sixty-five percent of patients ultimately required peroral antibiotic treatment (vancomycin, 52%; cotrimoxazole, 27%; rifampin and fusidic acid, 18%). Decolonization was successful in 54 (87%) of the patients in the intent-to-treat analysis and in 51 (98%) of 52 patients in the on-treatment analysis.

CONCLUSION. This standardized regimen for MRSA decolonization was highly effective in patients who completed the full decolonization treatment course.

Infect Control Hosp Epidemiol 2008; 29:510–516

In past decades, methicillin-resistant *Staphylococcus aureus* (MRSA) has become the most important multidrug-resistant pathogen worldwide, causing significant morbidity and increased healthcare costs.^{1,2} MRSA colonization precedes MRSA infection, which occurs in 20%–60% of colonized patients in acute-care facilities and in 3%–15% of those in long-term-care facilities.³ The rate of nosocomial transmission of MRSA in healthcare facilities can be reduced by the use of strict infection-control measures, such as establishment of MRSA surveillance; early identification of carriers; isolation of colonized or infected patients; use of barrier precautions, such as use of gloves, gowns, and masks, for patient care; use of strict hand hygiene with alcohol-based hand rubs; and careful environmental cleaning in patient rooms.^{3,4} Recently, community-associated strains of MRSA have begun to spread in the community, causing intrafamily clusters of infection

and outbreaks among injection drug abusers, prisoners, homeless individuals, sports teams, and children in day care centers.^{5,6}

Studies of surgical patients colonized with methicillin-susceptible *S. aureus* have demonstrated that decolonization treatment—for example, with mupirocin—can reduce the incidence of subsequent infection.⁷ In addition, most authorities recommend that MRSA carriers be decolonized in outbreak situations.

MRSA decolonization may reduce the risk of MRSA infection in individual carriers and could prevent MRSA spread in healthcare facilities and in the community by eliminating a reservoir for the organism. Several topical and systemic antimicrobial agents have been used for MRSA decolonization, with limited success rates.^{8–11} However, most of the studies are limited by the selection of patients (such as when patients with

From the Division of Infectious Diseases and Hospital Epidemiology (M.B., M.D., U.F., A.F.W.) and Microbiology Laboratory (R.F., L.F.), University Hospital Basel, Basel, Switzerland.

Received January 6, 2008; accepted March 12, 2008; electronically published May 30, 2008.

© 2008 by The Society for Healthcare Epidemiology of America. All rights reserved. 0899-823X/2008/2906-0006\$15.00. DOI: 10.1086/588201

MRSA infection are excluded), small sample sizes, and methodological flaws.⁸ Therefore, the effectiveness of MRSA decolonization is still controversial, and it is not routinely recommended.

The present study was performed to evaluate the efficacy of a standardized MRSA decolonization treatment regimen for MRSA-colonized and MRSA-infected patients and to identify factors influencing the failure of the decolonization program.

METHODS

Setting

The University Hospital Basel is a primary- and tertiary-care center with 750 beds and 27,000 admissions/year. Since 1993, data on all patients colonized or infected with MRSA have been prospectively collected by use of case report forms and entered into a database. The local prevalence of methicillin resistance among *S. aureus* isolates has remained low (less than 5%) during the past decade.¹² Screening for MRSA by analysis of nose and throat swab samples is routinely performed for patients who (1) are transferred from areas with MRSA endemicity, (2) have a history of MRSA colonization, (3) have a history of injection drug use, or (4) have been in contact with a known MRSA carrier.

Study Design and Definitions

We conducted a prospective cohort study from January 1, 2002, to April 30, 2007. All patients admitted to the University Hospital who were colonized or infected with MRSA were eligible for decolonization treatment. Patients who were unable or failed to attend follow-up visits were excluded from the analysis. For the purpose of the present study, MRSA colonization was defined as being present in any patient from whom MRSA was cultured from any body site (from routine screening or clinical specimens). MRSA infections were defined by use of the criteria of the Centers for Disease Control and Prevention.¹³

In an adaptation of the Centers for Disease Control and Prevention definition, a case of MRSA colonization was defined as “community acquired” if the patient had (1) no history of MRSA colonization; (2) no history of hospitalization, surgery, or hemodialysis in the previous 12 months; and (3) an MRSA strain that was not epidemiologically linked to the hospital strains. A case was defined as “healthcare associated” if the patient (1) underwent hospitalization in an acute-care or long-term-care facility, hemodialysis, or any surgery in the previous 12 months and (2) had an MRSA strain that was epidemiologically not linked to the hospital strains. A case was defined as “nosocomial” if the patient had MRSA colonization diagnosed more than 48 hours after hospital admission, 30 days after an operation, or 1 year after implantation of persistent foreign body material (eg, a joint prosthesis).

Decolonization

Before initiation of decolonization treatment, all patients with MRSA colonization underwent standardized screening, using samples collected by use of polyester fiber-tipped swabs from the following body sites: the nose, throat, inguinal area, perineal area, rectum, vagina (in women), wounds, and insertion sites of catheters. In addition, urine culture for MRSA was performed for patients with urinary catheters or urinary-tract infection.

Decolonization treatment was offered to all patients. It consisted of a 5-day standard regimen of application of mupirocin ointment (Bactroban; GlaxoSmithKline) twice daily, oral rinsing with 0.2% chlorhexidine solution (Dentohexin; Streuli Pharma) 3 times daily, and daily body washing with 4% chlorhexidine soap (Lifoscrub; B. Braun). In addition, specific decolonization treatment was administered for urogenital and gastrointestinal colonization: for patients with MRSA colonization of the urine, cotrimoxazole (800/160 mg twice daily) was administered for 5 days, if the strain was susceptible. For gastrointestinal colonization (indicated by an MRSA-positive rectal swab sample), oral vancomycin (1 g twice daily) was administered for 5 days. Vaginal colonization was treated with a povidone-iodine ovula (Betadine; Mundipharma Medical Company) administered once daily for 5 days as a first choice or, alternatively, a hexetidine ovula (Vagi-Hex; Drossapharm) administered twice daily for 6 days or octenidine solution (Oc-tensept; Schülke & Mayr) twice daily for 6 days for patients who did not tolerate or had contraindications for the use of a povidone-iodine ovula.

If a first cycle of decolonization treatment failed, the management of treatment was evaluated for potential obstacles to success—for example, noncompliance. Thereafter, a second cycle was started with the same regimen as described above. Systemic antibiotic treatment was recommended for patients whose conditions did not respond to 2 full cycles of decolonization treatment. Such patients were treated with fusidic acid (500 mg 3 times daily) and rifampin (450 mg twice daily) for 5 days. Other antibiotics were chosen on an individual basis for patients colonized with MRSA strains resistant to fusidic acid or rifampin.

MRSA decolonization was considered to be successful if there was no growth in 3 sets of surveillance cultures of samples (from the nose, throat, inguinal area, perianal area, rectum, vagina [in women], wounds, insertion sites, or urine [for patients with urinary-tract colonization]) obtained at least 2–3 days after completion of decolonization treatment at intervals of 2–3 days. After successful MRSA decolonization, follow-up cultures (of nose and throat samples) were performed at every subsequent hospital admission. All patients ever colonized with MRSA are labeled in the hospital mainframe system, and an alarm is sent to the department of hospital epidemiology within minutes after admission.

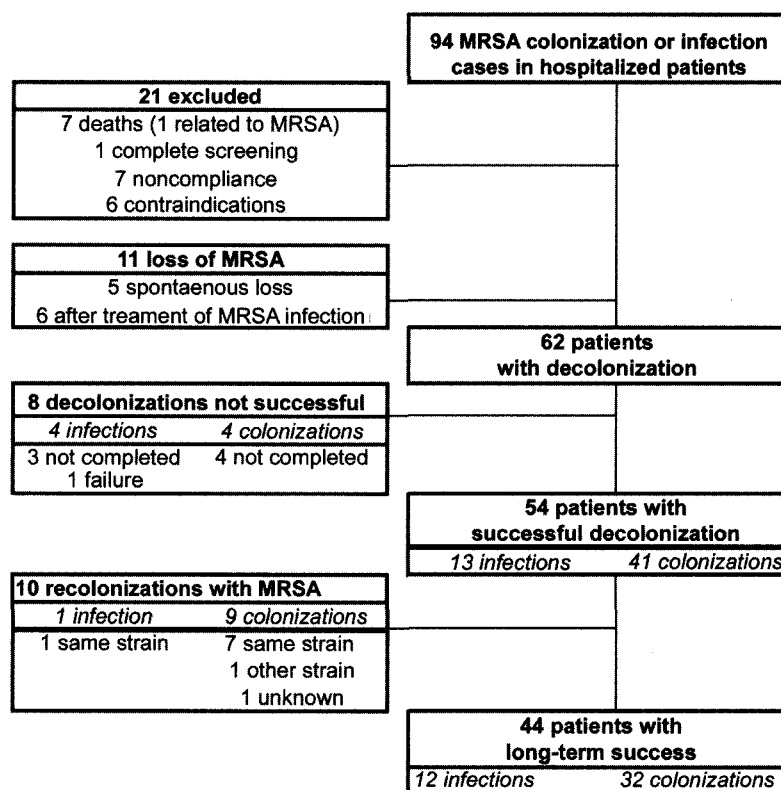


FIGURE 1. Diagram summarizing inclusion and exclusion of patients in the study. MRSA, methicillin-resistant *Staphylococcus aureus*.

Identification of MRSA and Molecular Typing

MRSA screening was performed by means of culture in a highly selective enrichment broth, as described elsewhere.¹² At the University Hospital Basel, each nonrepetitive clinical MRSA isolate has been typed by pulsed-field gel electrophoresis (PFGE) since 1993 and saved at -70°C . In addition, strains have been typed by polymerase chain reaction (PCR)¹⁴ and, more recently, by *spa* typing.¹⁵ For the present study, MRSA isolates were thawed from frozen storage and subcultured twice. DNA was extracted by use of the LC MagnaPure system (Roche Diagnostics), in accordance with the manufacturer's instructions. Genes for Panton-Valentine leukocidin (*pvl*); toxic shock syndrome toxin (*tst*); exfoliative toxins A, B, and D (*eta*, *etb*, and *etd*); and methicillin resistance (*mecA*) were detected by PCR, as described elsewhere.^{16–19} The polymorphic X region of the *spa* gene was amplified using primers *spa*-1113f and *spa*-1514r and sequenced as described elsewhere.¹⁵ Sequences were analyzed by use of StaphType software, version 1.5.4, and SpaServer (both Ridom).²⁰ Analysis of clustering into *spa* clonal complexes (*spa*CCs) was done using default parameters. Susceptibility to mupirocin was determined by E-test (AB Biodisk) and interpreted according to the commonly used definition (minimum inhibitory concentration for low-level resistance, 4–256 $\mu\text{g}/\text{mL}$; minimum inhibitory concentration for high-level resistance, more than 512 $\mu\text{g}/\text{mL}$).^{21,22}

Statistical Analysis

Data were analyzed with SPSS version 14.0.1 for Windows (SPSS). Kaplan-Meier curves were used to describe the probability of decolonization success; covariates were compared using the log rank test. $P < .05$ was considered to be significant.

RESULTS

During the study period, 94 cases of MRSA colonization or infection in hospitalized patients were identified, corresponding to prevalences of 0.1 cases per 100 patients discharged and 1.2 cases per 10,000 patient-days. Thirty-two cases were excluded from the analysis (Figure 1). For 11 patients, MRSA did not grow in screening cultures at the time when additional cultures were performed before decolonization was initiated, and all 11 patients had negative results for 3 sets of screening cultures at follow-up.

The most common sites of MRSA colonization were the nose and throat (Table 1), and 36 patients (58%) had gastrointestinal MRSA colonization (positive rectal cultures). However, no patients were found to have MRSA colonization by rectal culture only. In addition, 6 (26%) of 23 women had vaginal colonization. Seventeen (27%) of the patients presented with MRSA infection (Table 1). A minority of patients had community-acquired MRSA colonization (Table 1).

TABLE 1. Demographic and Clinical Characteristics of Patients Colonized or Infected with Methicillin-Resistant *Staphylococcus aureus* (MRSA)

Characteristic	Value
No. of patients	62
Male sex	39 (62.9)
Age, years, mean \pm SD	66.2 \pm 19
Type of MRSA colonization	
Nosocomial	28 (45.2)
Healthcare associated	27 (43.5)
Community acquired	7 (11.3)
<i>spa</i> type of colonizing strain ($n = 56^a$)	
t041	14 (25)
t008	12 (21.4)
t002	7 (12.5)
t032	5 (8.9)
t030	2 (3.6)
Other ^b	16 (28.6)
Site of colonization	
Nose	42 (67.7)
Throat	33 (53.2)
Inguinal area	30 (48.8)
Perianal area	33 (53.2)
Rectum	36 (58.1)
Wound	27 (43.5)
Urine	13 (21.0)
Vagina ^c	6 (26)
Other ^d	19 (30.6)
Risk factors for colonization	
Foreign-body implantation	19 (30.6)
Chronic skin ulcer	12 (19.3)
Diabetes mellitus	8 (12.9)
Immunosuppression	5 (8.1)
Hemodialysis	2 (3.2)
Chronic skin disease	1 (1.6)
None	15 (24.1)
Site of MRSA infection	
Osteomyelitis or spondylodiscitis	3 (4.8)
Bloodstream infection	3 (4.8)
Skin and soft-tissue infection	3 (4.8)
Pulmonary infection	2 (3.2)
Other ^e	6 (9.7)
Total no. of infections	17 (27.4)

NOTE. Data are no. (%) of patients, unless otherwise indicated.

^a Six isolates were not available for *spa* typing.

^b Other *spa* types included t001, t016, t024, t025, t026, t037, t046, t074, t1508, t1594, t230, t266, t355, t391, and t548.

^c Percentage of positive vaginal cultures among women only (6 of 23).

^d Insertion sites, 5 patients; blood, 4; sputum, 4; tracheobronchial secretions, 1; tracheostoma, 1; abdomen, 1; penis, 1; subretinal fluid, 1; nasolacrimal duct, 1.

^e Prosthetic valve endocarditis, 1 patient; abdominal abscess, 1; urinary tract infection, 1; dacryocystitis, 1; endophthalmitis, 1; foreign-body infection, 1 (Tenckhoff catheter).

Three isolates (5%) were positive for the community-acquired MRSA marker Pantone-Valentine leukocidin, whereas the gene for toxic-shock syndrome toxin 1 was found in 3 other isolates. No isolate was positive for the exfoliative toxin gene.

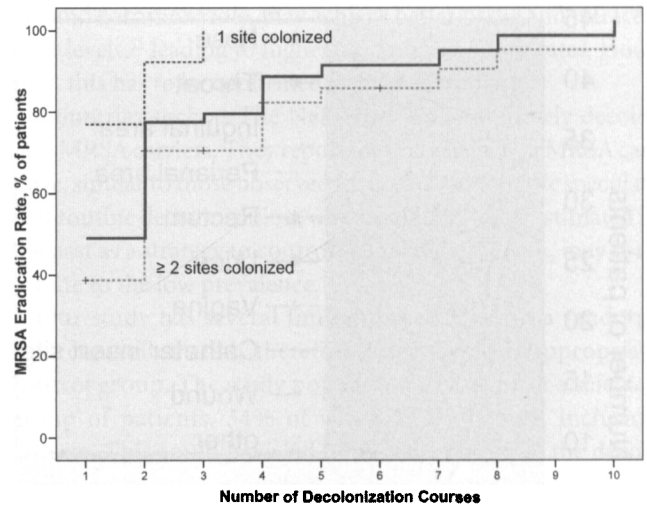


FIGURE 2. Number of decolonization courses needed for successful methicillin-resistant *Staphylococcus aureus* (MRSA) eradication, overall (bold line) and stratified according to number of sites initially colonized by MRSA ($P = .004$).

Overall, 54 of the patients (87%) were successfully decolonized (intent-to-treat analysis). Of the 8 patients with decolonization failure, 7 did not complete the decolonization treatment course according to the protocol, because of non-compliance (3 patients) or sociomedical reasons (4 patients). The patient for whom decolonization failed despite completion of the decolonization treatment course was a young man who had been transferred to our hospital from Brazil after a car accident. After treatment of an open fracture, he developed a chronic osteomyelitis caused by multidrug-resistant *Pseudomonas aeruginosa* and was found to be colonized with MRSA (MRSA was not found in the bone biopsy). Treatment of osteomyelitis failed, as did decolonization after completion of 6 decolonization treatment cycles. It was therefore decided to postpone further decolonization treatment until the osteomyelitis was under control. Treatment was successful in 51 (98%) of 52 (on-treatment analysis) of the patients who completed the full decolonization treatment cycle.

For 29 (46.7%) of 62 of the patients, MRSA eradication was achieved after 1 decolonization course (Figure 2). A minority of patients (10 [16%]) underwent more than 3 decolonization courses. Patients with MRSA colonization at a single body site required significantly fewer decolonization courses for successful eradication than did those with colonization at multiple sites (eradication rate after 1 course, 76.9% of patients with 1 site colonized and 38.7% of patients with multiple sites colonized; $P = .004$) (Figure 2). MRSA colonization persisted longer in patients with throat colonization than in patients with colonization of other sites (Figure 3). Decolonization was not successful in 23.5% of MRSA-infected patients, compared with 8.8% of colonized patients. Decolonization in patients with MRSA *spa* type t041 was more difficult to achieve than was decolonization in patients with other *spa*

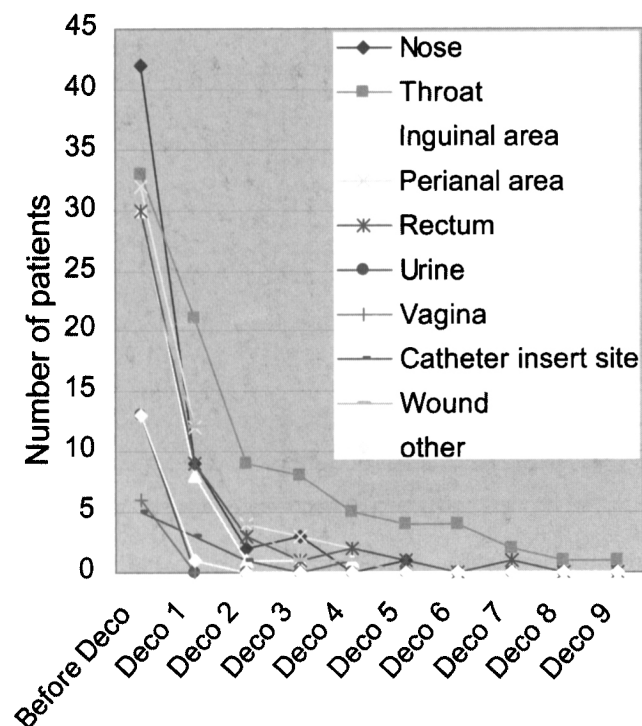


FIGURE 3. Number of patients colonized after each decolonization course (Deco), by methicillin-resistant *Staphylococcus aureus* colonization site (colonization of multiple sites was possible).

types (eradication rate after 1 course, 26.6% and 51.2%, respectively); however, the difference was not statistically significant ($P = .20$).

After successful decolonization, recolonization with MRSA occurred in 10 patients, after a mean interval of 240 days (range, 24–536 days). The recolonization isolate from 1 patient was not available for typing. One patient was colonized with a new MRSA type, confirmed by the presence of a new *spa* type (t008 and t032). In 8 patients, the recolonization strains were indistinguishable from the previous isolates by PFGE, a finding possibly indicating decolonization failure or recolonization by the identical strain. However, the long-term eradication rate was still 72.6%, under the assumption that all patients mentioned above are considered to have decolonization failure. A mean of 4 control screening cultures were available after successful decolonization during a median follow-up period of 34 months (range, 0–72 months).

Mupirocin resistance was rare (Table 2). There was no mupirocin resistance observed in strains of MRSA from patients who were recolonized.

Rates of susceptibility to rifampin, fusidic acid, and cotrimoxazole were 92%, 83%, and 89%, respectively. No glycopeptide-resistant MRSA strains were found. Of 62 isolates, 56 were available for *spa* typing. Of these, 40 (71.4%) belonged to 5 widely distributed epidemic *spa* types that are circulating throughout Europe (Table 1).

DISCUSSION

Eradication of MRSA carriage may reduce the risk of infection in MRSA-colonized patients and prevent MRSA cross-transmission to other individuals. However, the efficacy of MRSA decolonization treatment still remains controversial.^{8,9}

Our study demonstrates that MRSA decolonization with a combination of topical and systemic antimicrobial agents is highly effective for patients completing the full decolonization treatment course. Our decolonization success rate of 87% is higher than most rates that have been reported elsewhere in the literature.^{8–11} None of the previous studies defined decolonization success as rigorously as ours: at least 6 body sites, some of them almost never screened in published studies (eg, the vagina), had to test negative by use of state-of-the-art selective enrichment broth methods.¹² There are several possible reasons for the high efficacy of our MRSA decolonization strategy. First, several other trials evaluated the efficacy of MRSA decol-

TABLE 2. Characteristics of Methicillin-Resistant *Staphylococcus aureus* Decolonization in 94 Patients

Characteristic	Value
Decolonization cycles required for successful decolonization, mean \pm SD (range), no. per patient	2.1 \pm 1.8 (1–10)
Time from diagnosis to start of first decolonization course, median (range), days	13 (0–687)
Time to successful decolonization, median (range), days ^a	65 (14–559)
Colonization with a mupirocin-resistant strain	
Low-level resistance (MIC, 4–256 μ g/mL)	2 (3.6)
High-level resistance (MIC \geq 512 μ g/mL)	1 (1.8)
Decolonization regimen	
Standardized regimen without antibiotics ^b	22 (35.5)
Vancomycin by mouth	32 (51.6)
Cotrimoxazole	17 (27.4)
Rifampin plus fusidic acid	11 (17.7)
Rifampin plus other antibiotic ^c	3 (4.8)
Other ^d	4 (6.4)
Decolonization treatment result	
Successful decolonization	54 (87.1)
Decolonization regimen not completed ^e	7 (11.3)
Unsuccessful decolonization	1 (1.6)
Follow-up period for successful decolonization, median (range), months	34 (0–72)

NOTE. Data are no. (%) of patients, unless otherwise indicated. MIC, minimum inhibitory concentration.

^a Decolonization success was defined as 3 sets of negative culture results from swab samples from the following body sites: nose, throat, inguinal area, rectum, perianal area, urine, wounds, and vagina (in women).

^b Application of mupirocin ointment twice daily, oral rinsing with chlorhexidine 0.2% 3 times daily, and washing with chlorhexidine soap once daily for 5 days.

^c Teicoplanine and rifampin, 1 patient; vancomycin and rifampin, 2 [1 of the 2 courses was followed by treatment with cotrimoxazole and rifampin].

^d Clindamycin, 1 patient; fusidic acid, 1; doxycycline, 1; linezolid, 1.

^e Interruption because of noncompliance for 3 patients and because of socio-medical reasons for 4 patients.

onization on the basis of a single decolonization course. However, in our study, decolonization treatment was repeated if it was not successful at the first attempt, and possible reasons were evaluated, resulting in a mean of 2 courses per patient, with 16% of patients undergoing more than 3 decolonization courses. MRSA eradication after a single decolonization course was achieved in 46.7% of patients, which is comparable to rates in the literature.^{10,11,23,24} In pediatric patients with cystic fibrosis, a 3-step protocol with topical mupirocin, chlorhexidine for washing, and a 5-day course of rifampin and fusidic acid has been evaluated; MRSA eradication was achieved in 16 (94%) of 17 patients—8 (47%) after 1 decolonization course and 8 (47%) after 2 or 3 decolonization courses.²⁵ Maraha et al.²⁶ found the rate of MRSA elimination to be 100% after a mean of 1.6 courses of treatment with enteral vancomycin and topical antimicrobials during an outbreak; decolonization was achieved after 1 course in 69% of patients.

Second, decolonization failure has been reported in patients colonized with MRSA strains with low-level mupirocin resistance.²³ In our study, the rate of low-level mupirocin resistance was low. Of 3 patients colonized with strains with low-level mupirocin resistance, 2 did not undergo decolonization because of noncompliance, and 1 patient was successfully decolonized. The only patient colonized with a strain with high-level mupirocin resistance did not complete decolonization because of noncompliance. In addition, decolonization failure or MRSA recolonization during follow-up was not associated with mupirocin resistance.

Third, previous studies have revealed that the gastrointestinal tract is an important MRSA reservoir in colonized patients.^{27,28} In our study, more than half of the patients had MRSA colonization of the gastrointestinal tract, as indicated by positive rectal cultures. Decolonization procedures using topical antimicrobial agents focus on eradication of MRSA on nares, skin, and, less frequently, the throat. However, treatment is not targeted at gastrointestinal colonization, facilitating recolonization of other body sites. Silvestri et al.²⁹ found eradication of MRSA gut carriage by treatment with enteral vancomycin to be effective in the reduction of the rate of MRSA colonization and infection in an outbreak among patients receiving mechanical ventilation in intensive care units. Maraha et al.²⁶ reported a 100% success rate for MRSA decolonization with enteral vancomycin and topical antimicrobial treatment during an outbreak in a urological unit. In our study, elimination of gut carriage could have minimized the rate of decolonization failure and the risk of recolonization in our population.

Recent studies have shown that the throat is an important site for MRSA colonization that can persist for years.^{12,30} Our data suggest that throat colonization is more difficult to eradicate than is colonization of other sites. One possible reason for this could be the insufficient levels of antiseptics that are achieved in the crypts of the tonsils with topical treatment. In addition, *S. aureus* can be internalized by human cells and can survive intracellularly.³¹ Systemic antibiotics, especially rifam-

pin and cotrimoxazole, may achieve better tissue and intracellular levels,³² leading to higher MRSA eradication rates. However, this has to be confirmed in further studies.

Countries such as The Netherlands also routinely decolonize MRSA carriers. They report low prevalences of MRSA carriage, similar to those observed in our institution. We speculate that routine decolonization, which has been underestimated in the past as a strategy to control the spread of MRSA, may contribute to the low prevalence.

Our study has several limitations. It was not a randomized controlled trial; therefore, there was no appropriate control group. The study population consisted of a selected group of patients, 34% of whom did not meet inclusion criteria. This could have led to overestimation of the decolonization success. However, 27% of the patients were not only colonized but also infected with MRSA, which added obstacles to successful decolonization. The number of cases was small because of a low local MRSA prevalence. In fact, Switzerland has a very low rate of antibiotic use,³³ leading to low selection pressure and potentially allowing MRSA to escape detection by screening culture. Finally, although the study design was prospective, with standardized protocols, PCR for the *pvl* and *tsst* genes and the additional method of *spa* typing were introduced during the study period. However, PFGE was used throughout the study.

In conclusion, this standardized regimen including a combination of topical and systemic antimicrobial agents was highly effective for MRSA decolonization in colonized and infected individuals. The majority of patients were successfully decolonized with 2 or 3 decolonization courses. Decolonization of patients with throat carriage seems to be more difficult to achieve than decolonization of patients with carriage at other sites, and systemic antibiotics may be necessary in the treatment of patients whose conditions do not respond to topical therapy. Specific treatment of gastrointestinal and urogenital MRSA reservoirs may improve the rate of successful decolonization. However, the evolution of other antibiotic-resistant organisms, such as vancomycin-resistant enterococci, needs to be carefully monitored.

ACKNOWLEDGMENTS

We thank M. Battegay, for his helpful comments, and the infection control team of the University Hospital Basel, for their help in data collection.

Financial support. The study was supported in part by the Swiss National Science Foundation (3200BO-104179) and the hospital research fund.

Potential conflicts of interest. All authors report no conflicts of interest relevant to this article.

Address reprint requests to Andreas F. Widmer, MD, MS, Division of Infectious Diseases and Hospital Epidemiology, University Hospital Basel, Petersgraben 4, CH- 4031 Basel, Switzerland (awidmer@uhbs.ch).

Presented in part: 47th Interscience Conference on Antimicrobial Agents and Chemotherapy; Chicago, Illinois; Sept 17-20, 2007.

REFERENCES

- Lowy FD. Staphylococcus aureus infections. *N Engl J Med* 1998;339:520-532.
- Gould IM. The clinical significance of methicillin-resistant *Staphylococcus aureus*. *J Hosp Infect* 2005;61:277-282.
- Rubinovitch B, Pittet D. Screening for methicillin-resistant *Staphylococcus aureus* in the endemic hospital: what have we learned? *J Hosp Infect* 2001;47:9-18.
- Pittet D, Hugonnet S, Harbarth S, et al. Effectiveness of a hospital-wide programme to improve compliance of hand-hygiene. *Lancet* 2000;356:1307-1312.
- Gilbert M, MacDonald J, Gregson D, et al. Outbreak in Alberta of community-acquired (USA300) methicillin-resistant *Staphylococcus aureus* in people with a history of drug use, homelessness or incarceration. *CMAJ* 2006;175:149-154.
- Weber JT. Community-associated methicillin-resistant *Staphylococcus aureus*. *Clin Infect Dis* 2005;41(Suppl 4):S269-272.
- Perl TM, Cullen JJ, Wenzel RP, et al. Intranasal mupirocin to prevent postoperative *Staphylococcus aureus* infections. *N Engl J Med* 2002;346:1871-1877.
- Loeb M, Main C, Walker-Dilks C, et al. Antimicrobial drugs for treating methicillin-resistant *Staphylococcus aureus* colonization. *Cochrane Database Syst Rev* 2003;(4).
- Loveday HP, Pellowe CM, Jones SRLJ, et al. A systematic review of the evidence for interventions for the prevention and control of methicillin-resistant *Staphylococcus aureus* (1996-2004): report to the Joint MRSA Working Party (Subgroup A). *J Hosp Infect* 2006;63:S45-S70.
- Walsh TJ, Standiford HC, Reboli AC, et al. Randomized double-blinded trial of rifampin with either novobiocin or trimethoprim-sulfamethoxazole against methicillin-resistant *Staphylococcus aureus* colonization: prevention of antimicrobial resistance and effect of host factors on outcome. *Antimicrob Agents Chemother* 1993;37:1334-1342.
- Simor AE, Phillips E, McGeer A, et al. Randomized controlled trial of chlorhexidine gluconate for washing, intranasal mupirocin, and rifampin and doxycycline versus no treatment for the eradication of methicillin-resistant *Staphylococcus aureus* colonization. *Clin Infect Dis* 2007;44:178-185.
- Mertz D, Frei R, Jaussi B, et al. Throat swabs are necessary to reliably detect carriers of *Staphylococcus aureus*. *Clin Infect Dis* 2007;45:475-477.
- In: Mayhall CG, Horan TC, Gaynes RP, eds. *Hospital Epidemiology and Infection Control: Surveillance of Nosocomial Infections*. 3rd ed. Philadelphia, PA: Lippincott Williams & Wilkins; 2004:1659-1702.
- Strandén AM, Frei R, Widmer AF. Molecular typing of methicillin-resistant *S. aureus* (MRSA): can PCR replace pulsed-field gel electrophoresis. *J Clin Microbiol* 2003;41:3181-3186.
- Strommenger B, Kettlitz C, Weniger T, et al. Assignment of *Staphylococcus* isolates to groups by *spa* typing, SmaI macrorestriction analysis, and multilocus sequence typing. *J Clin Microbiol* 2006;44:2533-2540.
- Lina G, Piemont Y, Godail-Gamot F, et al. Involvement of Panton-Valentine leukocidin producing *Staphylococcus aureus* in primary skin infections and pneumonia. *Clin Infect Dis* 1999;29:1128-1132.
- Yamasaki O, Tristan A, Yamaguchi T, et al. Distribution of the exfoliative toxin D gene in clinical *Staphylococcus aureus* isolates in France. *Clin Microbiol Infect* 2006;12:585-588.
- Mehrotra M, Wang G, Johnson WM. Multiplex PCR for detection of genes for *Staphylococcus aureus* enterotoxins, exfoliative toxins, toxic shock syndrome toxin 1, and methicillin resistance. *J Clin Microbiol* 2000;38:1032-1035.
- Murakami K, Minamide W, Wada K, et al. Identification of methicillin-resistant strains of staphylococci by polymerase chain reaction. *J Clin Microbiol* 1991;29:2240-2244.
- Ridom SpaServer. Available at: <http://www.spaserver.ridom.de>. Accessed February 20, 2008.
- MacGowan AP, Wise R. Establishing MIC breakpoints and the interpretation of in vitro susceptibility tests. *J Antimicrob Chemother* 2001;48:17-28.
- Simor AE, Stuart TL, Louie L, et al. Mupirocin-resistant, methicillin-resistant *Staphylococcus aureus* strains in Canadian hospitals. *Antimicrob Agents Chemother* 2007;51:3880-3886.
- Harbarth S, Dharan S, Liassine N, et al. Randomized, placebo-controlled, double-blind trial to evaluate the efficacy of mupirocin for eradicating carriage of methicillin-resistant *Staphylococcus aureus*. *Antimicrob Agents Chemother* 1999;43:1312-1316.
- Muder RR. A controlled trial of rifampicin, minocycline and rifampicin plus minocycline for eradication of methicillin-resistant *Staphylococcus aureus* in long-term care patients. *J Antimicrob Chemother* 1994;34:189-190.
- Macfarlane M, Leavy A, McVaughan J, et al. Successful decolonization of methicillin-resistant *Staphylococcus aureus* in paediatric patients with cystic fibrosis using a three-step protocol. *J Hosp Infect* 2007;65:231-236.
- Maraha B, Van Halteren J, Verzijl JM, et al. Decolonization of methicillin-resistant *Staphylococcus aureus* using oral vancomycin and topical mupirocin. *Clin Microbiol Infect* 2002;8:671-675.
- Klotz M, Zimmermann S, Oppen S, et al. Possible risk for re-colonization with methicillin-resistant *Staphylococcus aureus* (MRSA) by faecal transmission. *Int J Hyg Environ Health* 2005;208:401-405.
- Boyce JM, Havill NL, Maria B. Frequency and possible infection control implications of gastrointestinal colonization with methicillin-resistant *Staphylococcus aureus*. *J Clin Microbiol* 2005;43:5992-5995.
- Silvestri L, Milanese M, Oblach L, et al. Enteral vancomycin to control methicillin-resistant *Staphylococcus aureus* outbreak in mechanically ventilated patients. *Am J Infect Control* 2002;30:391-399.
- Ringberg H, Petersson AC, Walder M, et al. The throat: an important site for MRSA colonization. *Scand J Infect Dis* 2006;38:888-893.
- Garzoni C, Francois P, Huyghe A, et al. A global view of *Staphylococcus aureus* whole genome expression upon internalization in human epithelial cells. *BMC Genomics* 2007;8:171.
- Yamaoka T. The bactericidal effects of anti-MRSA agents with rifampicin and sulfamethoxazole-trimethoprim against intracellular phagocytized MRSA. *J Infect Chemother* 2007;13:141-146.
- Filippini M, Masiero G, Moschetti K. Socioeconomic determinants of regional differences in outpatient antibiotic consumption: evidence from Switzerland. *Health Policy* 2006;78:77-92.